

**DATE**

10/6/21

**PRESENTING CLINICAL SIGNS**

Vomiting past 3 weeks.

Current Medications: Veraflox 25mg/mL - Give 1.5 mL po SID - started 9/29/21. Amoxi-Clavulanate 62.5mg - Give 1 tablet po BID for 14 days - started 9/29/21. Cerenia 16mg - 1/2 tab po SID for 4 days - started 9/29/21.

**PATIENT**

Shiloh Gordon

Lab Results: Chemistry and T4 look good, but concern for elevated neutrophil level (~33K).

Date of Previous IntraPet Ultrasound: No previous

Sedation: not needed

Stat Report: not requested

**SPECIES**

Feline

**BREED**

Domestic Shorthair

**SEX**

Neutered male

**AGE**

2010

**WEIGHT**

11.24 lbs

**INTERPRETED BY**Eric Lindquist, DMV  
DABVP, Cert. IVUSS**HOSPITAL NAME**

Taylorsville VC

**REFERRING VET**

Dr. Earp

**INVOICE**

92208

**ULTRASONOGRAPHIC EXAMINATION OF THE ABDOMEN****Urinary System**

The **urinary bladder**, trigone, and pelvic urethra presented normal thicknesses and normal tone. The ureters were not visible which is normal. No uroliths or sediment were visualized and anechoic urine was present. No evidence of inflammatory or neoplastic changes was noted. Ureteral papillae were normal.

The **kidneys** presented a relatively uniform cortical hyperechogenicity when compared to the renal medulla, spleen and liver. No overt masses were noted. Corticomedullary definition was nebulous and the ratio favored the cortex slightly. The ureters were not visible and assumed to be normal. These changes are most consistent with chronic interstitial nephritis yet infiltrative disease could not be entirely ruled out without biopsy though neoplasia is not suspected. The right kidney measured 3.9 cm. The left kidney revealed cortical infarcts and cortical collapse. Pelvic mineralization was noted. The left kidney was subnormal in size and measured 2.85 cm.

**Adrenal Glands**

Both **adrenal glands** were visualized and recognized as having normal shape, size, position and echogenicity for this breed. The phrenic vasculature, glandular echogenicity and detail were unremarkable. Capsule, cortex, and medullary definition were normal for this age patient.

**Spleen**

The **spleen** in this patient was uniform, yet volume contracted. Hydration status should be assessed.

**Liver**

The **liver** is diffusely hyperechoic to the falciform fat. The gallbladder and common bile duct were unremarkable.

**Gastrointestinal**

Examination of the **gastrointestinal tract** revealed a stomach and intestine free of stasis, of normal wall thickness, acceptable curvilinear mural detail, and peristaltic activity. Small and large intestine demonstrated normal luminal chyme and stool consistency respectively. The ileocecal junction revealed undifferentiated 5.0 cm intestinal mass that occupied the ileocecolic junction. Slight areas of free fluid were noted.

**Pancreas**

Heterogenous omental changes were noted around the **pancreas**. This may be manifestation of the suspected neoplastic process.

### Free Abdomen

Free fluid was noted likely secondary to lymphomatosis, carcinomatosis or lymphatic congestion.

### ULTRASONOGRAPHIC FINDINGS

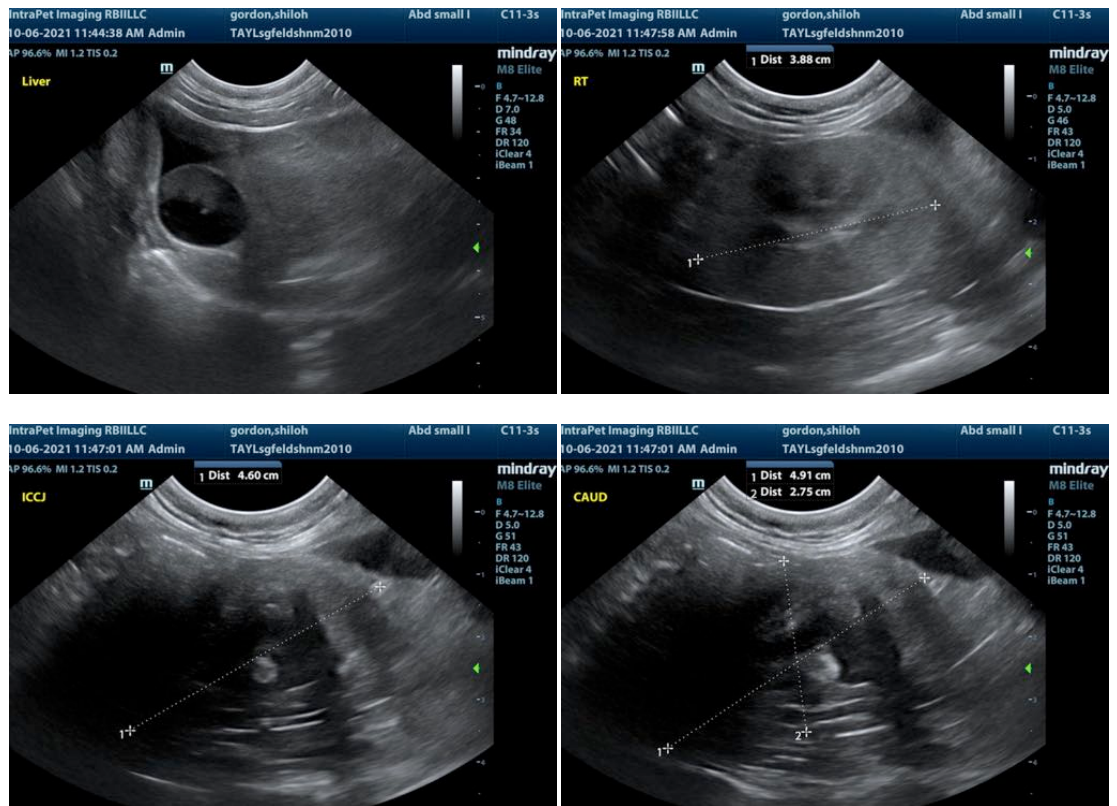
Ileocecolic mass.

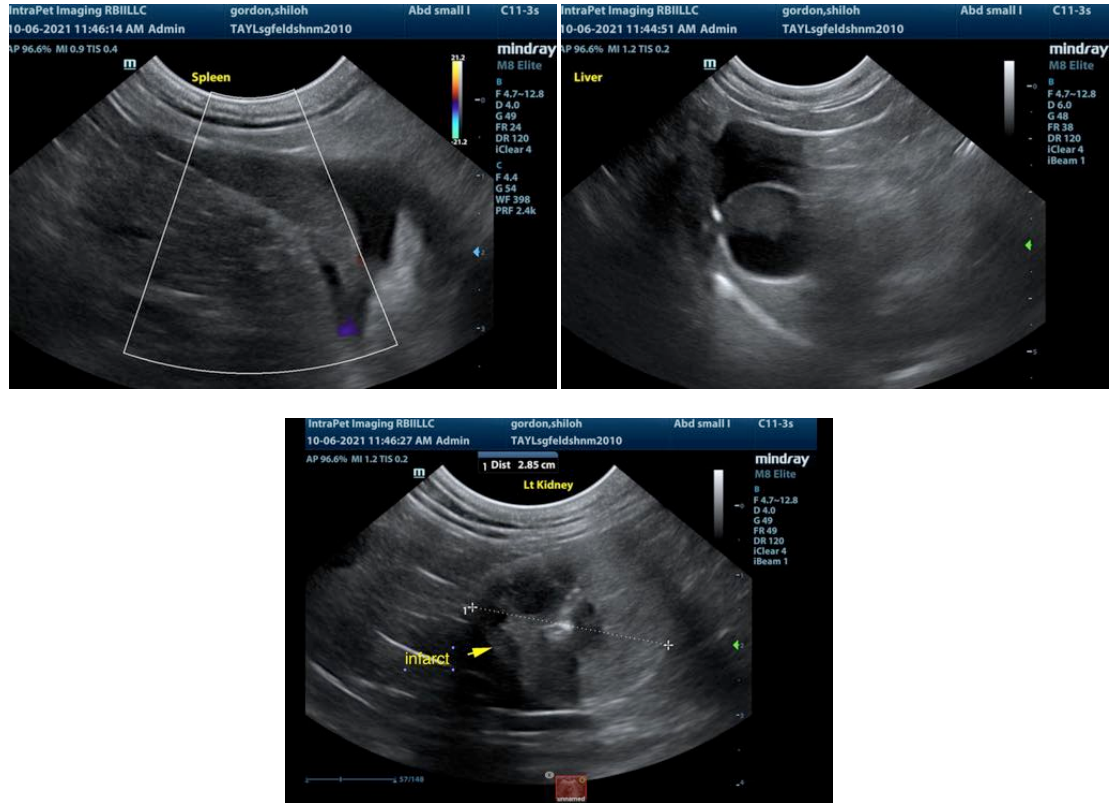
Dystrophic left kidney with infarcts and mineralization.

Chronic interstitial nephrosis right kidney.

### INTERPRETATION OF THE FINDINGS & FURTHER RECOMMENDATIONS

The prognosis is poor. Abdominocentesis and cytospin would be warranted or full exploratory surgery. Given the free fluid resection of the ileocecolic junction is unlikely to prove curative.





The information and recommendations provided are based on the images presented by the referring veterinarian. No evaluation can be communicated regarding pathology that was not visible in the image/video clips provided.

Thank you for this referral. If the clinical or image interpretation does not parallel your findings or if I can be of any further assistance please contact me.

**Eric Lindquist, DMV, DABVP, Cert. IVUSS, CEO of SonoPath.com**  
 Eric.Lindquist@SonoPath.com