



PATIENT PRESENTING CLINICAL SIGNS

Molly Romero vomiting blood

SPECIES ULTRASONOGRAPHIC EXAMINATION OF THE ABDOMEN

Canine Urinary System

The **urinary bladder**, trigone, and pelvic urethra presented normal thicknesses and normal tone. The ureters were not visible which is normal. No uroliths or sediment were visualized and anechoic urine was present. No evidence of inflammatory or neoplastic changes were noted. Ureteral papillae were normal.

BREED

Pomeranian

SEX

Female

The **kidneys** revealed normal size and structure, corticomedullary definition and ratio for this age. The cortices presented largely uniform texture with normal echogenic relationship to liver and spleen. Medullary structure differed distinctly from the cortex and no evidence of pelvic dilation was present. The capsules were acceptably uniform without significant irregularities. The right kidney measured 3.03 cm. The left kidney measured 3.39 cm.

AGE

1 Year

Adrenal Glands

Both **adrenal glands** were visualized and recognized as having normal shape, size, position and echogenicity for this breed. The phrenic vasculature, glandular echogenicity and detail were unremarkable. Capsule, cortex, and medullary definition were normal for this age patient. The left adrenal gland measured 1.6 cm x 0.39 cm at the caudal pole and 0.49 cm at the cranial pole. The right adrenal gland measured 1.23 cm x 0.93 cm at the cranial pole and 0.4 cm at the caudal pole.

WEIGHT

10

Spleen

The **spleen** presented a smooth homogeneous parenchyma hyperechoic to liver and renal cortical parenchyma. The capsule was smooth without noticeable expansion or deviation from within the spleen or adjacent pathology. The splenic vasculature demonstrated normal volume without signs of congestion or thrombosis. No sonographic evidence of acute or chronic inflammatory, neoplastic, or infarctual changes were noted.

INTERPRETED BY

Eric Lindquist, DMV
DABVP, Cert. IVUSS

IMAGING PERFORMED BY

Jenn

Liver

The **liver** was slightly subnormal in size, otherwise unremarkable. The gallbladder was unremarkable.

HOSPITAL NAME

Rockaway AH

Gastrointestinal

The **stomach** revealed slight shadowing material, possibly medications, measuring 1.0 cm, non-obstructive. No fluid filled lumen noted prior. The small intestine and colon were unremarkable.

REFERRING VET

Dr. Maniar

Pancreas

The base and limbs of the **pancreas** were observed to be largely isoechoic to surrounding omental fat. Pancreatic duct and capsular contour were acceptably normal and parenchyma respected normal curvilinear patterns. No overt evidence of active inflammatory or neoplastic disease was noted.

INVOICE

26089

Other

The uterus was thickened in this patient, measuring 1.8 cm in width. Slight fluid filled lumen.

DATE

10/6/21



PATIENT

Molly Romero

ULTRASONOGRAPHIC FINDINGS

- Minor pyloric material, possible medications, non-obstructive
- Thickened uterus

SPECIES

Canine

INTERPRETATION OF THE FINDINGS & FURTHER RECOMMENDATIONS

Assessment for vaginal discharge warranted. Either active heat cycle or possible low-grade metritis. Supportive care should prove effective. Recheck sonogram in 48-72 hours to assess if the pyloric material is persistently present and/or if the uterus has changed in appearance.

BREED

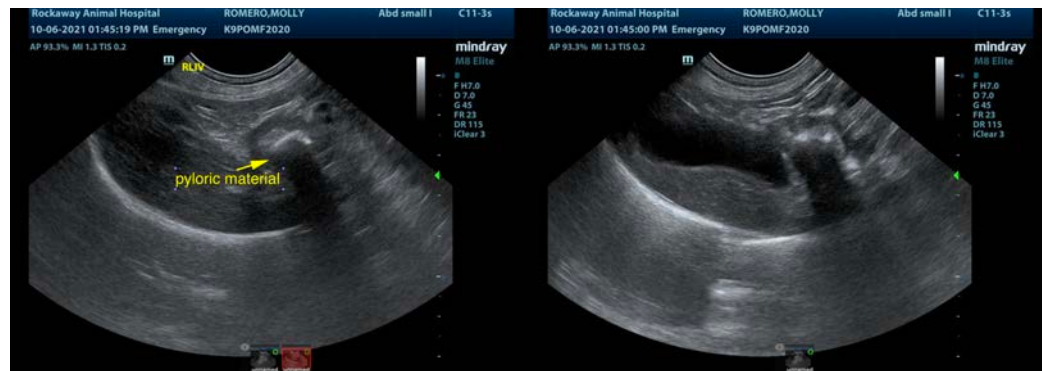
Pomeranian

SEX

Female

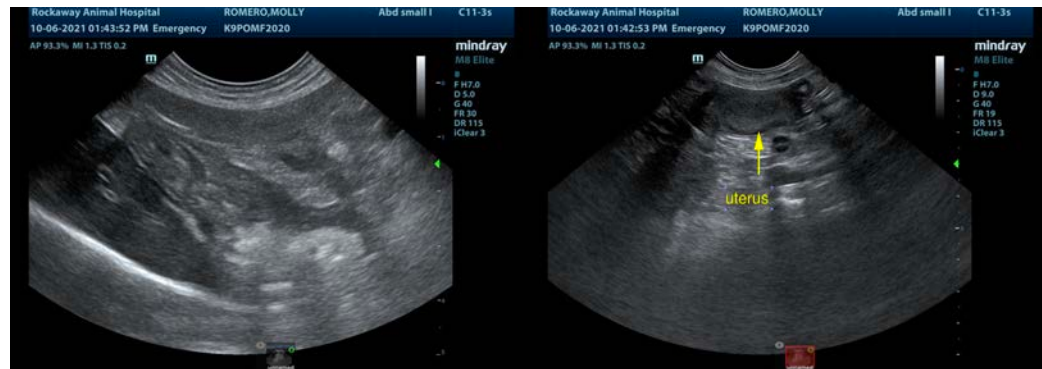
AGE

1 Year



WEIGHT

10



INTERPRETED BY

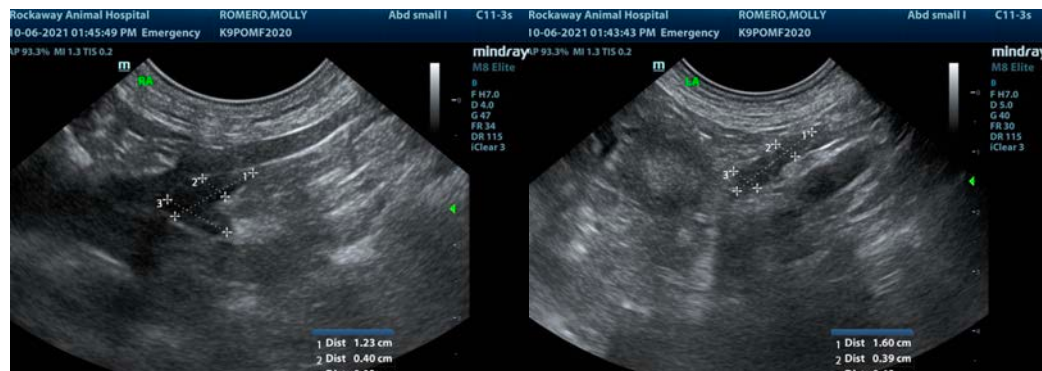
Eric Lindquist, DMV
DABVP, Cert. IVUSS

IMAGING PERFORMED BY

Jenn

HOSPITAL NAME

Rockaway AH



REFERRING VET

Dr. Maniar

INVOICE

26089

DATE

10/6/21



PATIENT

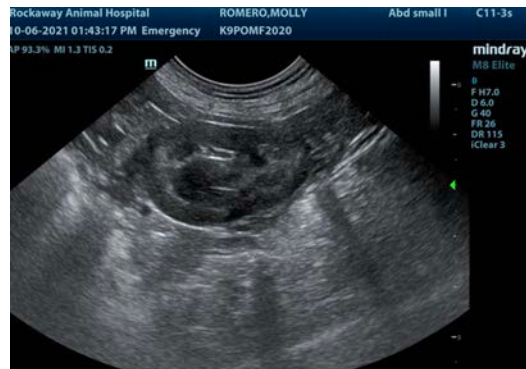Molly Romero

SPECIES

Canine

BREED

Pomeranian



SEX

Female

The information and recommendations provided are based on the images presented by the referring veterinarian. No evaluation can be communicated regarding pathology that was not visible in the image/video clips provided.

AGE

1 Year

Thank you for this referral. If the clinical or image interpretation does not parallel your findings or if I can be of any further assistance please contact me.

WEIGHT

10

Eric Lindquist, DMV, DABVP, Cert. IVUSS, CEO of SonoPath.com
info@SonoPath.com

INTERPRETED BY

Eric Lindquist, DMV
DABVP, Cert. IVUSS

IMAGING PERFORMED BY

Jenn

HOSPITAL NAME

Rockaway AH

REFERRING VET

Dr. Maniar

INVOICE

26089

DATE

10/6/21