



**PATIENT**

Maggie Cose

**SPECIES**

Canine

**BREED**

Golden Retriever

**SEX**

Spayed Female

**AGE**

8 years

**WEIGHT**

80.8 lbs

**INTERPRETED BY**

Eric Lindquist, DMV  
DABVP, Cert. IVUSS

**IMAGING PERFORMED BY**

Dr. Rupley

**HOSPITAL NAME**

All Pets Medical Center

**REFERRING VET**

Dr. Rupley

**INVOICE**

92201

**DATE**

10/6/21

**PRESENTING CLINICAL SIGNS**

History: PRESENTED FOR: Blood in the stool and straining. VITALS: Temperature: 101.4 Heart Rate: 120 bpm Respiratory Rate: 108 bpm PANTING Mucous Membrane Color: Pink Capillary Refill Time: <2 seconds HISTORY Has hypothyroidism, off treatment for a couple of weeks. CURRENT MEDICATIONS: None EXAM FINDINGS: Obese, b/s 8/9. No apparent pain on palpation of the abdomen. Rectal exam reveals soft dark feces with some dark red blood and mucous. No mass palpated and sublumbar lymph nodes palpate normal. Anal sacs palpate normal. Grade II/VI left basilar murmur. Normal rhythm and rate. Ear and skin infections. Dental disease. LAB RESULTS: Fecal Float nps CBC results reveal a leukocytosis resulting from a neutrophilia, with 17% hypersegmented neutrophils Chemistry and electrolyte panel results are normal. Urinalysis results reveal a pH of 7 and Specific Gravity: 1.018. The cPLI is normal. Fecal gram's stain normal.

**ULTRASONOGRAPHIC EXAMINATION OF THE ABDOMEN**

**Urinary System**

The **urinary bladder**, trigone, and pelvic urethra presented normal thicknesses and normal tone. The ureters were not visible which is normal. No uroliths or sediment were visualized and anechoic urine was present. No evidence of inflammatory or neoplastic changes was noted. Ureteral papillae were normal.

The **kidneys** revealed normal size and structure, corticomedullary definition and ratio for this age. The cortices presented largely uniform texture with normal echogenic relationship to liver and spleen. Medullary structure differed distinctly from the cortex and no evidence of pelvic dilation was present. The capsules were acceptably uniform without significant irregularities. The left kidney measured 7.08 cm. The right kidney measured 7.94 cm.

**Adrenal Glands**

The left **adrenal gland** was visualized and recognized as having normal shape, size, position and echogenicity for this breed. The phrenic vasculature, glandular echogenicity and detail were unremarkable. Capsule, cortex, and medullary definition were normal for this age patient. The left adrenal gland measured 0.5 cm. The region of the right adrenal gland was unremarkable.

**Spleen**

The **spleen** presented a smooth homogeneous parenchyma hyperechoic to liver and renal cortical parenchyma. The capsule was smooth without noticeable expansion or deviation from within the spleen or adjacent pathology. The splenic vasculature demonstrated normal volume without signs of congestion or thrombosis. No sonographic evidence of acute or chronic inflammatory, neoplastic, or infarctual changes was noted.



**PATIENT** *Liver*

Maggie Cose The **liver** images submitted revealed subjectively normal liver size, contour, and structure. Parenchymal echogenicity was naturally coarse and hypoechoic to the spleen. Vascular and biliary tracts were of normal volume with no evidence of congestion. The gallbladder presented acceptably thin walls with primarily anechoic content. The cystic and common bile ducts were normal. No pathological hepatic lymphadenopathy was evident. No overt structural evidence of inflammatory, infiltrative or regenerative pathology was evident.

**SPECIES**

Canine

**BREED**

Golden Retriever

**SEX**

Spayed Female

**AGE**

8 years

**WEIGHT**

80.8 lbs

**Gastrointestinal**

Examination of the **gastrointestinal tract** revealed a stomach and intestine free of stasis, of normal wall thickness, acceptable curvilinear mural detail, and peristaltic activity. Small and large intestine demonstrated normal luminal chyme and stool consistency respectively. No obstructive or overt infiltrative disease was noted. No associated abnormal lymphatic activity was noted.

**Pancreas**

The base and limbs of the **pancreas** were observed to be largely isoechoic to surrounding omental fat. Pancreatic duct and capsular contour were acceptably normal and parenchyma respected normal curvilinear patterns. No overt evidence of active inflammatory or neoplastic disease was noted.

**ULTRASONOGRAPHIC FINDINGS**

Structurally unremarkable abdomen.

**INTERPRETED BY**

Eric Lindquist, DMV  
DABVP, Cert. IVUSS

**INTERPRETATION OF THE FINDINGS & FURTHER RECOMMENDATIONS**

There was no evidence of visceral pathology. Supportive care should prove effective. I recommend a fresh fecal smear and fecal floatation analysis. Rectal palpation is warranted. There was no evidence of pathology noted; however, the distal colon or colorectal pathology can still be present.

**IMAGING PERFORMED BY**

Dr. Rupley

**HOSPITAL NAME**

All Pets Medical Center

**REFERRING VET**

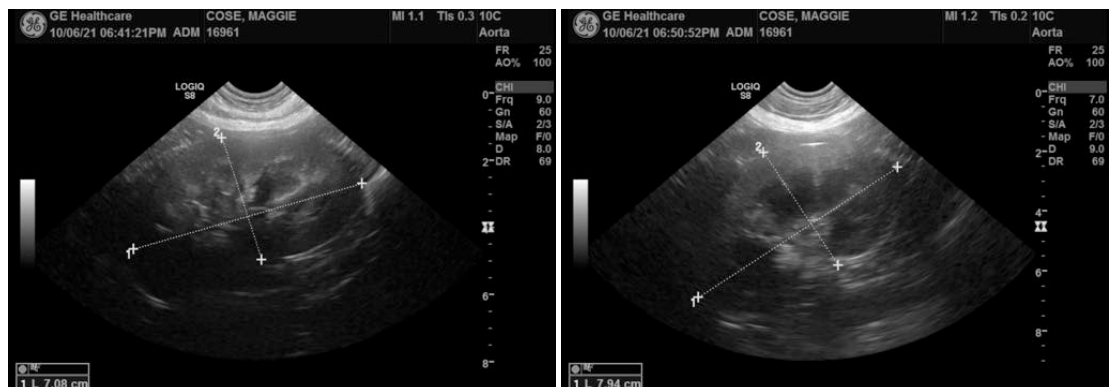
Dr. Rupley

**INVOICE**

92201

**DATE**

10/6/21





**PATIENT**

Maggie Cose

**SPECIES**

Canine

**BREED**

Golden Retriever

**SEX**

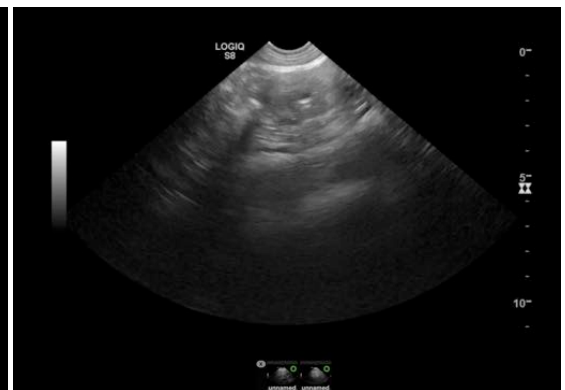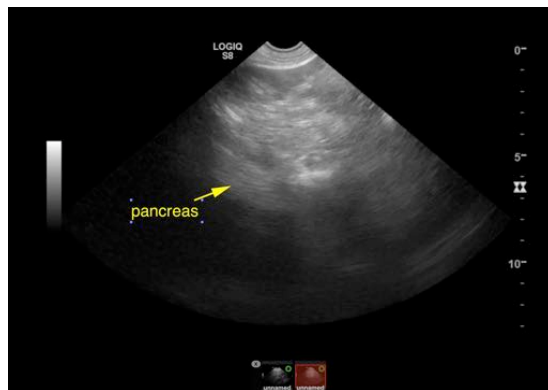
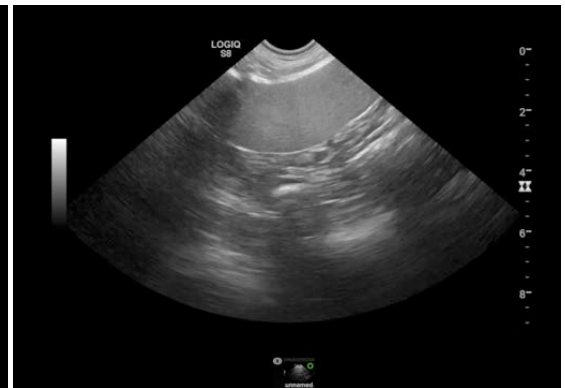
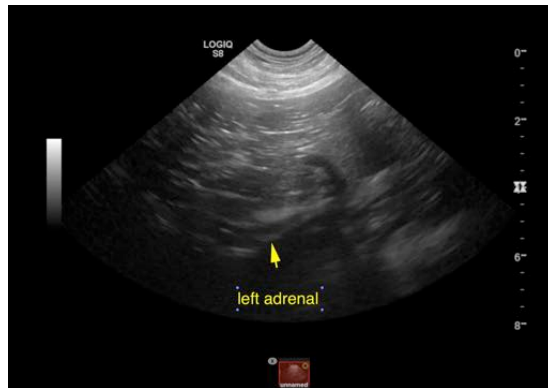
Spayed Female

**AGE**

8 years

**WEIGHT**

80.8 lbs



**INTERPRETED BY**

Eric Lindquist, DMV  
DABVP, Cert. IVUSS

**IMAGING PERFORMED BY**

Dr. Rupley

**HOSPITAL NAME**

All Pets Medical Center

**REFERRING VET**

Dr. Rupley

**INVOICE**

92201

**DATE**

10/6/21

The information and recommendations provided are based on the images presented by the referring veterinarian. No evaluation can be communicated regarding pathology that was not visible in the image/video clips provided.

Thank you for this referral. If the clinical or image interpretation does not parallel your findings or if I can be of any further assistance please contact me.

**Eric Lindquist, DMV, DABVP, Cert. IVUSS, CEO of SonoPath.com**  
info@SonoPath.com