

**DATE PRESENTING CLINICAL SIGNS**

10/5/21 Vomiting, Diarrhea, Lethargic, & Not Himself.

PATIENT

Tiny Jones

History: Date: 10-04-2021 Notes: Last 2 weeks owner reports Tiny has been having soft stools off and on and seems to have some fecal incontinence. Yesterday had a large amount of projective vomiting. Went to rDVM today; radiographs showed thickened bowel loops and possible mass in cranial abdomen. ALT slightly increased at 160; Na and Cl slightly decreased.

SPECIES

Canine

Current Medications: Pantoprazole (Protonix) 40mg/vial Injection (Per mL), Buprenorphine 0.6mg/mL
Lab Results: ALT slightly increased at 160; Na and Cl slightly decreased.

BREED

Pomeranian

Radiographs: radiographs showed thickened bowel loops and possible mass in cranial abdomen.

Date of Previous IntraPet Ultrasound: no previous.

Sedation: not needed

Stat Report: not requested

SEX

Neutered Male

ULTRASONOGRAPHIC EXAMINATION OF THE ABDOMEN**Urinary System**

The **urinary bladder**, trigone, and pelvic urethra presented normal thicknesses and normal tone. The ureters were not visible which is normal. No uroliths or sediment were visualized and anechoic urine was present. No evidence of inflammatory or neoplastic changes were noted. Ureteral papillae were normal.

AGE

2012

WEIGHT

7.6 Pounds

The **kidneys** revealed largely normal size and structure, corticomedullary definition and ratio (cortex 1/3 of medulla) were essentially maintained with some age-related loss of curvilinear patterns regarding the capsule and C/M junction. The cortices presented largely uniform texture with some increased echogenicity expected for his age patient. Medullary structure differed distinctly from that of the cortex and no evidence of pelvic dilation was present. Calculi noted in both kidneys, non-obstructive. The right kidney measured 3.04 cm with largest calculus of 0.3 cm. The left kidney measured 3.57 cm.

INTERPRETED BYEric Lindquist, DMV
DABVP, Cert. IVUSS**Adrenal Glands**

Both **adrenal glands** were visualized and recognized as having normal shape, size, position and echogenicity for this breed. The phrenic vasculature, glandular echogenicity and detail were unremarkable. Capsule, cortex, and medullary definition were normal for this age patient. The left adrenal gland measured 1.3 cm x 0.39 cm at the cranial pole and 0.42 cm at the caudal pole. The right adrenal gland measured 1.4 cm x 0.46 cm at the cranial pole and 0.47 cm at the caudal pole.

HOSPITAL NAMEAnimal Emergency
Hospital**REFERRING VET**

Dr. Martinoli

Spleen

The **spleen** presented a smooth homogeneous parenchyma hyperechoic to liver and renal cortical parenchyma. The capsule was smooth without noticeable expansion or deviation from within the spleen or adjacent pathology. The splenic vasculature demonstrated normal volume without signs of congestion or thrombosis. No sonographic evidence of acute or chronic inflammatory, neoplastic, or infarctual changes were noted.

INVOICE

26075

Liver

The **liver** images submitted revealed subjectively normal liver size, contour, and structure. Parenchymal echogenicity was naturally coarse and hypoechoic to the spleen. Vascular and biliary tracts were of normal volume with no evidence of congestion. The gallbladder presented acceptably thin walls with primarily anechoic content. The cystic and common bile ducts were normal. No pathological hepatic lymphadenopathy was evident. No overt structural evidence of inflammatory, infiltrative or regenerative pathology was evident.

Gastrointestinal

The **stomach** was overdistended with fluid, no overt obstruction. The pylorus was free of luminal pathology and patent. Subjective mild hypertrophy present. The small intestine and colon were unremarkable.

Pancreas

The base and limbs of the **pancreas** were observed to be largely isoechoic to surrounding omental fat. Pancreatic duct and capsular contour were acceptably normal and parenchyma respected normal curvilinear patterns. No overt evidence of active inflammatory or neoplastic disease was noted.

ULTRASONOGRAPHIC FINDINGS

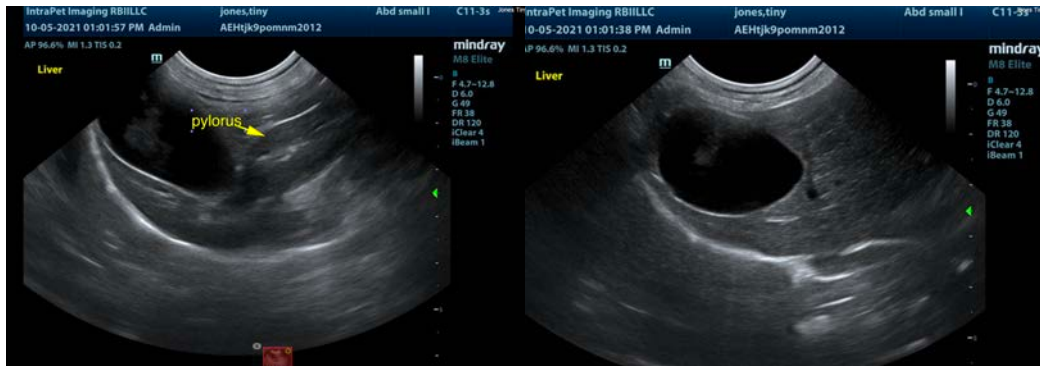- Mild pyloric hypertrophy with gastric stasis – likely gastritis.
- Minor renal calculi, non-obstructive

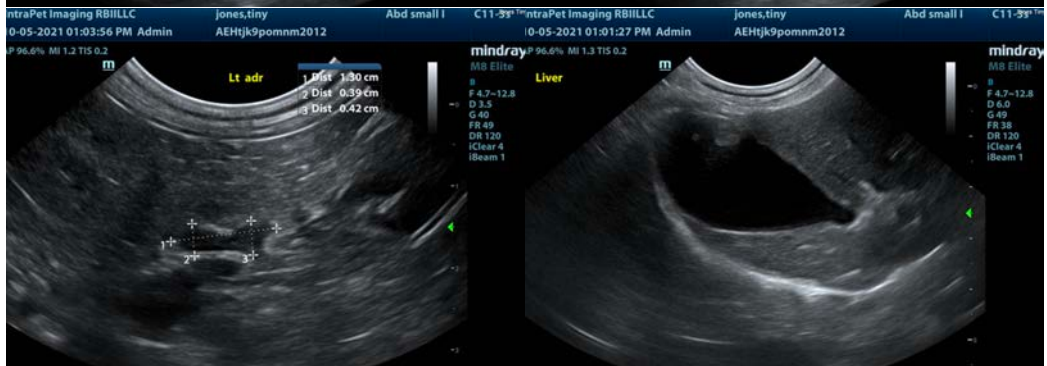
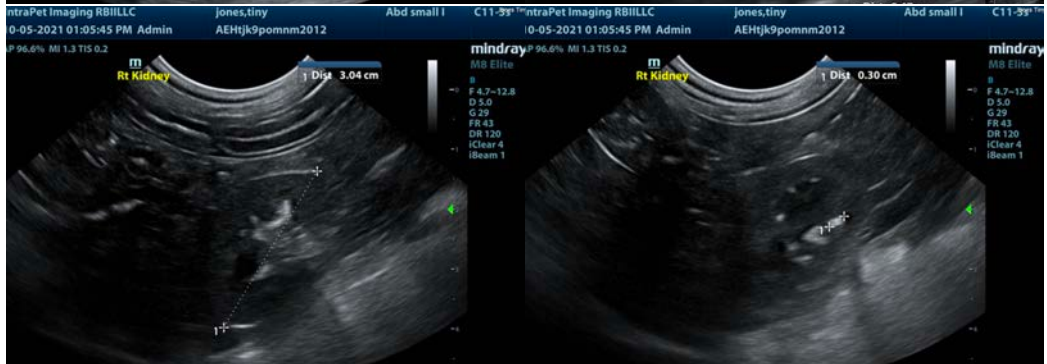
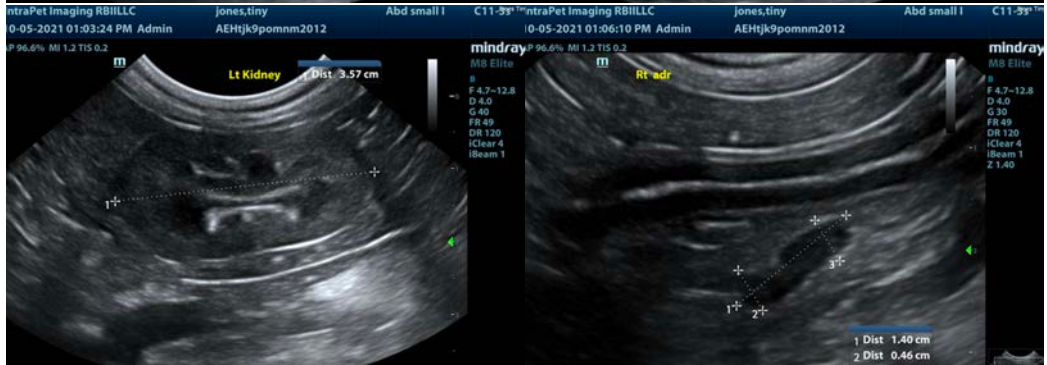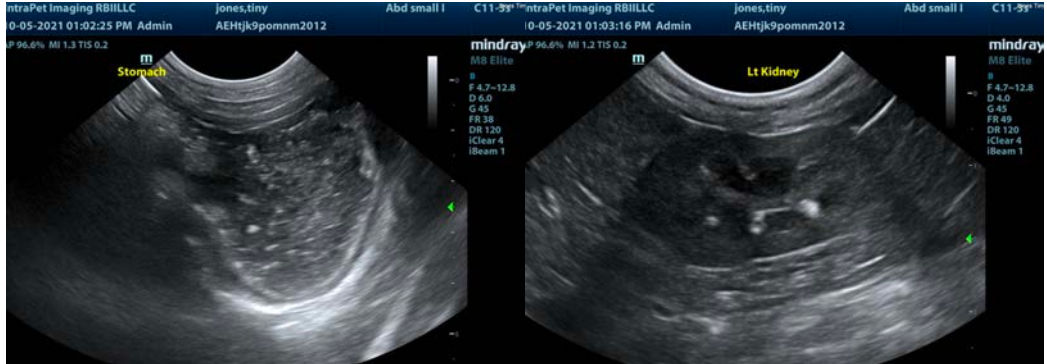
INTERPRETATION OF THE FINDINGS & FURTHER RECOMMENDATIONS

Supportive GI care should prove effective. A clinical trial of the following may prove effective. Canned BID feedings likely in this patient's best interest, as any bulk would likely be irritative to the pyloric outflow. Dietary indiscretion, food intolerance, structurally insignificant inflammatory bowel or occult parasitism and occult Addison's are all potentials.

Helicobacter/Gastritis protocol

A clinical trial of **Zithromax** (**Dogs:** 5-10 mg/kg p.o. q24h. May increase dosing interval to q48h after 3-5 days of treatment), **Metronidazole** (10-20 mg/kg p.o. b.i.d.), **Pepcid** (0.5-1 mg/kg s.i.d.) and **Sucralfate** (0.5-2 g/dog PO) or **Omeprazole** (1 mg/kg p.o. s.i.d.) over the next 3 weeks along with a **novel-protein or hydrolyzed diet** with slurry feeding b.i.d./t.i.d. over the next 2-4 days and then increase to canned diet bid. Dry food should be avoided over the next 4 weeks. A recheck sonogram to assess GI improvement or progression would be ideal in 4 weeks.





The information and recommendations provided are based on the images presented by the referring veterinarian. No evaluation can be communicated regarding pathology that was not visible in the image/video clips provided.

Thank you for this referral. If the clinical or image interpretation does not parallel your findings or if I can be of any further assistance please contact me.

Eric Lindquist, DMV, DABVP, Cert. IVUSS, CEO of SonoPath.com
info@SonoPath.com