



**PATIENT**

Tilly Reager

**SPECIES**

Canine

**BREED**

Airedale Terrier

**SEX**

Intact Female

**AGE**

4 months

**WEIGHT**

19 lbs

**PRESENTING CLINICAL SIGNS**

History: Tilly is a four month old, female, Airedale Terrier puppy with a history of UTI, frequent urinary accidents in house that resolved with antibiotic course. Since then, Tilly has had increased volumes of urination and seems like has to go out every hour. However, Tilly does not have urinary accidents overnight. Brief urinary tract ultrasound is submitted to rule out causes such as ectopic ureters. Urinalysis by cystocentesis was performed today and showed USG=1.028, pH=6.5, WBC=4 phpf, no crystals, no bacteria, no casts Urine culture is pending

**ULTRASONOGRAPHIC EXAMINATION OF THE ABDOMEN**

**Urinary System**

The **urinary bladder**, trigone, and pelvic urethra presented normal thicknesses and normal tone. The ureters were not visible which is normal. No uroliths or sediment were visualized and anechoic urine was present. No evidence of inflammatory or neoplastic changes was noted. Ureteral papillae were normal. Normal ureteral jets were noted.

The uterus was unremarkable and uniform measuring 0.3 cm.

The **kidneys** revealed normal size and structure, corticomedullary definition and ratio for this age. The cortices presented largely uniform texture with normal echogenic relationship to liver and spleen. Medullary structure differed distinctly from the cortex and no evidence of pelvic dilation was present. The capsules were acceptably uniform without significant irregularities. The left kidney measured 6.08 cm. The right kidney measured 6.31 cm.

**INTERPRETED BY**

Eric Lindquist, DMV  
DABVP, Cert. IVUSS

**ULTRASONOGRAPHIC FINDINGS**

Structurally normal urinary tract.

**IMAGING PERFORMED BY**

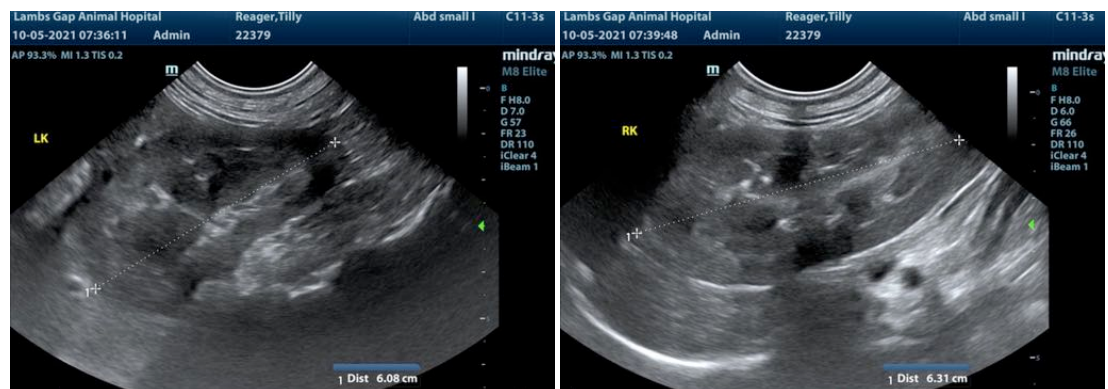
Dr. Todd

**INTERPRETATION OF THE FINDINGS & FURTHER RECOMMENDATIONS**

There is no evidence of ectopic ureters or renal dysplasia.

**HOSPITAL NAME**

Lambs Gap AH



**REFERRING VET**

Dr. Campbell

**INVOICE**

92170

**DATE**

10/5/21



**PATIENT**

Tilly Reager

**SPECIES**

Canine

**BREED**

Airedale Terrier

**SEX**

Intact Female

**AGE**

4 months

**WEIGHT**

19 lbs

**INTERPRETED BY**

Eric Lindquist, DMV  
DABVP, Cert. IVUSS

**IMAGING PERFORMED BY**

Dr. Todd

**HOSPITAL NAME**

Lambs Gap AH

**REFERRING VET**

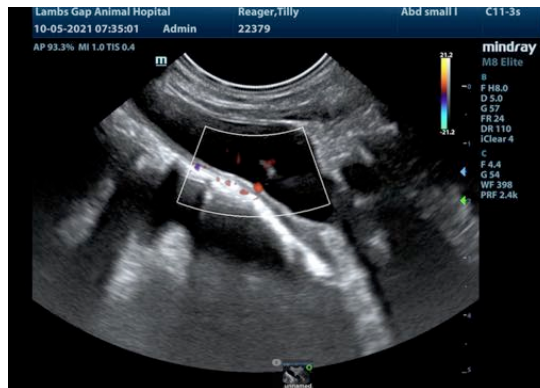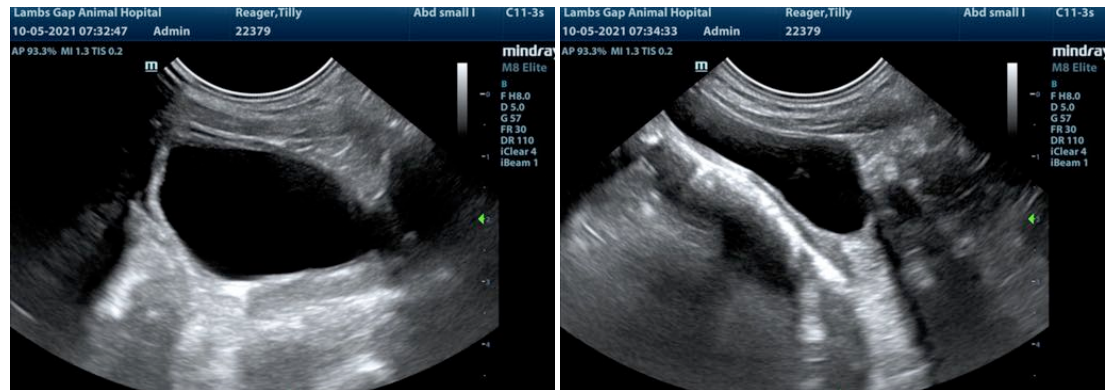
Dr. Campbell

**INVOICE**

92170

**DATE**

10/5/21



The information and recommendations provided are based on the images presented by the referring veterinarian. No evaluation can be communicated regarding pathology that was not visible in the image/video clips provided.

Thank you for this referral. If the clinical or image interpretation does not parallel your findings or if I can be of any further assistance please contact me.

Eric Lindquist, DMV, DABVP, Cert. IVUSS, CEO of SonoPath.com  
info@SonoPath.com