



**PATIENT**

Rizzo Lampariello

**PRESENTING CLINICAL SIGNS**

History: New HM Grade 3/6 L sided , owner reports some coughing at night at home

**SPECIES**

Canine

**BREED**

Beagle

**SEX**

Spayed female

**AGE**

11 years

**WEIGHT**

28 lbs

**INTERPRETED BY**

Eric Lindquist, DMV  
DABVP, Cert. IVUSS

**IMAGING PERFORMED BY**

Jenn

**HOSPITAL NAME**

Rockaway AH

**REFERRING VET**

Dr. Kahn

**INVOICE**

89875

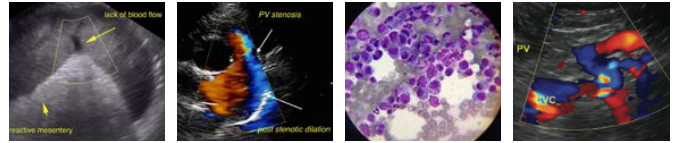
**DATE**

10/4/22

**ULTRASONOGRAPHIC EXAMINATION OF THE HEART**

The echocardiogram in this patient demonstrated normal **left atrial** size based on 3 different LA measurement methods. Chamber volumes and echogenicity were normal. The cranial and caudal **mitral** valve leaflets presented vegetative thickening consistent with endocardiosis. Doppler indicated measurable insufficiency. The **left ventricle** presented normal thicknesses with linear contour and was not dilated nor restricted. The **myocardium** presented normal echogenicity without subjective evidence of significant fibrotic or ischemic disease. **Contractility** of the ventricular walls was adequate and in normal range for this patient evidenced by the fractional shortening measurement and subjective evaluation of the different regions of the myocardium. The **left ventricular outflow** tract demonstrated normal laminar flow and subjective structural integrity. The **right atrium** and auricle revealed normal size, structure and content. No evidence of masses was noted or chamber overload. **Tricuspid** valvular assessment demonstrated adequate linear morphology. The **right ventricle** was of normal size (1/3 diameter of LV), chordae structure, myocardial echogenicity and thickness. **Pulmonic** tract assessment revealed normal valve structure, laminar flow, and diameter (approx. 1:1 pa/ao ratio). No visible **pericardial** or free pleura fluid was noted. No echographically detectable evidence of infiltrative disease was visible. The cranial **mediastinum and pericardial regions** were free of masses in the visible window.

CANINE CARDIAC PARAMETERS	MR VMAX (m/s)	TR VMAX (m/s)	LA/AO (Boon method)	LA/AO (Heart Base; Swe)	FS (%)	EF (%)	EPSS (cm)
NORMAL PARAMETER	4.5-5.5	<2.7	1.3	<1.6	28-40	40-100	<0.6
PATIENT	6.0	2.0	1.1	1.15	64	93	NM
CANINE CARDIAC PARAMETERS	HR (BPM)	AV VMAX (m/s)	PV MAX (m/s)	BODY WEIGHT	LA 2D short axis Base view (cm)	LVIDd Avg; 2D and m- mode short axis (cm)	LVIDs Avg; 2D and m- mode short axis (cm)
NORMAL PARAMETER	50-100	0.7-1.7	0.7-1.6	BELOW	BELOW	BELOW	BELOW
PATIENT	168	1.8	1.17	28 lbs	2.2	2.87	



**PATIENT**                      **ULTRASONOGRAPHIC FINDINGS**

Rizzo Lampariello                      Stage B1 valvular disease.

**SPECIES**                      **INTERPRETATION OF THE FINDINGS & FURTHER RECOMMENDATIONS**

Canine                      The cough is non-cardiogenic in this patient. Primary respiratory protocol is recommended.

**BREED**                      The heart is stable without clinical disease. No overt contraindication for anesthesia of brief to moderate duration. I suggest Torbutrol premed, Propofol induction, Isoflor maintenance or similar protocol if anesthesia is desired. Blood pressure recommended if not already performed and target white coat negative systolic pressure of < 160 mmHg. If higher than this ACE-inhibitor is suggested to reach this level. Recheck echocardiogram is recommended in 6 months, earlier if murmur grade increases or clinical signs initiate.

**SEX**

Spayed female

**AGE**

11 years

**WEIGHT**

28 lbs

**INTERPRETED BY**

Eric Lindquist, DMV  
DABVP, Cert. IVUSS

**IMAGING PERFORMED BY**

Jenn

**HOSPITAL NAME**

Rockaway AH

**REFERRING VET**

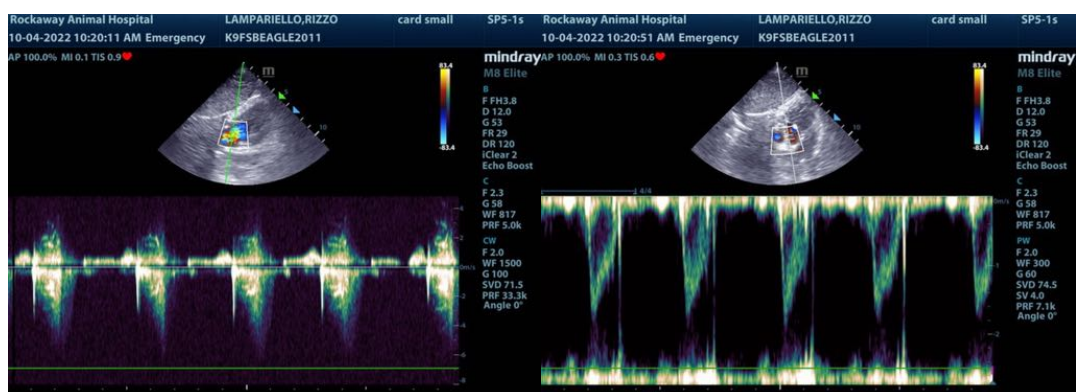
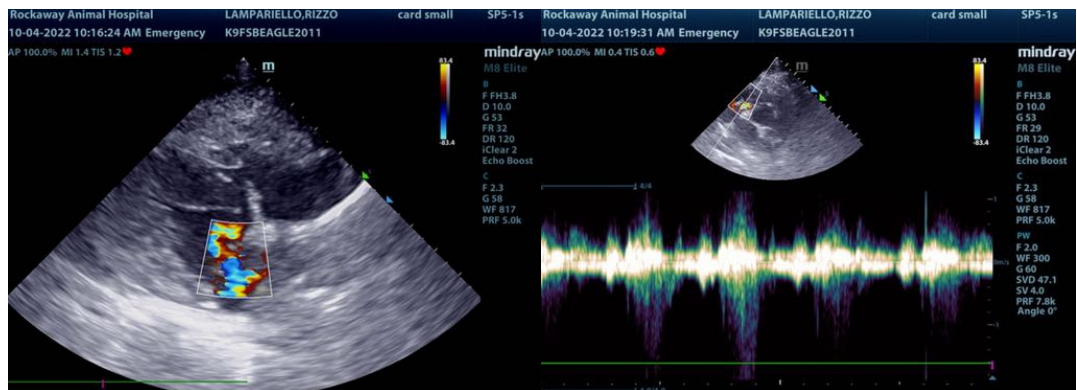
Dr. Kahn

**INVOICE**

89875

**DATE**

10/4/22





**PATIENT**

Rizzo Lampariello

**SPECIES**

Canine

**BREED**

Beagle

**SEX**

Spayed female

**AGE**

11 years

**WEIGHT**

28 lbs

**INTERPRETED BY**

Eric Lindquist, DMV  
DABVP, Cert. IVUSS

**IMAGING PERFORMED BY**

Jenn

**HOSPITAL NAME**

Rockaway AH

**REFERRING VET**

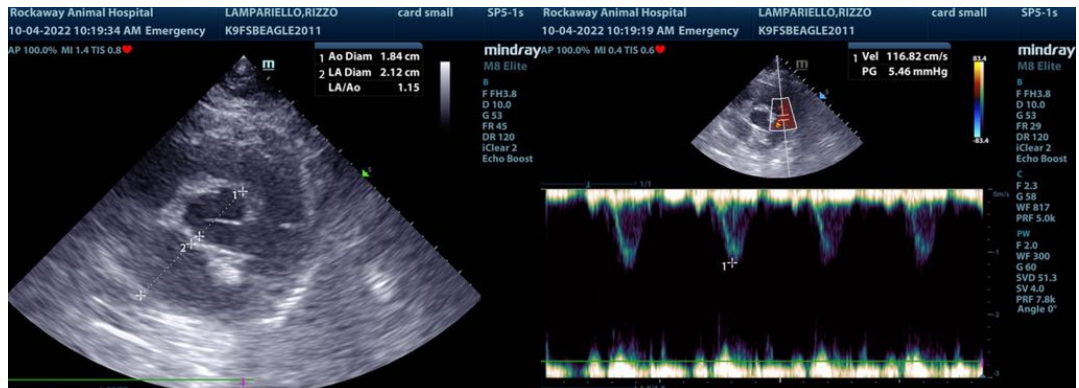Dr. Kahn

**INVOICE**

89875

**DATE**

10/4/22



The information and recommendations provided are based on the images presented by the referring veterinarian/sonographer. No evaluation can be communicated regarding pathology that was not visible in the image/video clips provided.

Thank you for this referral. If the clinical or image interpretation does not parallel your findings or if I can be of any further assistance please contact me.

**Eric Lindquist**, DMV, DABVP, Cert. IVUSS, CEO of SonoPath.com  
info@SonoPath.com