

**PATIENT**

Gizmo Miller

SPECIES

Feline

BREED

Domestic Shorthair

SEX

Female

AGE

6 months

WEIGHT

3.6 lbs

INTERPRETED BYEric Lindquist, DMV
DABVP, Cert. IVUSS**IMAGING
PERFORMED BY**

Amy Mayhew LVT

HOSPITAL NAME

SVS Imaging Michigan

REFERRING VET

Family Pet Practice

INVOICE

39900

DATE

10/4/22

PRESENTING CLINICAL SIGNS

History: Current Medications: None currently- plan to start Metronidazole, fenbendazole, proviable today 10/4/22 Patient History: Presented for AUS following elevated ALT prior to OHE. Recent history of soft stool for past couple of weeks. Feral kitten found outdoors.

Fecal from 10/3/22 Rhabditiform larva 1+ Pre-op bloodwork ALT 233 (10-100) otherwise normal, PT/PTT WNL **Bile acids, toxo titers submitted 10/4/22 Abnormal Examination Findings: Mildly thickened intestines on abdominal palpation Mobile deciduous molars

ULTRASONOGRAPHIC EXAMINATION OF THE ABDOMEN**Urinary System**

The **urinary bladder**, trigone, and pelvic urethra presented normal thicknesses and normal tone. The ureters were not visible which is normal. No uroliths or sediment were visualized and anechoic urine was present. No evidence of inflammatory or neoplastic changes was noted. Ureteral papillae were normal.

The **kidneys** revealed normal size and structure, corticomedullary definition and ratio for this age. The cortices presented largely uniform texture with normal echogenic relationship to liver and spleen. Medullary structure differed distinctly from the cortex and no evidence of pelvic dilation was present. The capsules were acceptably uniform without significant irregularities. The right kidney measured 3.54 cm. The left kidney measured 3.05 cm.

Adrenal Glands

Both **adrenal glands** were visualized and recognized as having normal shape, size, position and echogenicity for this breed. The phrenic vasculature, glandular echogenicity and detail were unremarkable. Capsule, cortex, and medullary definition were normal for this age patient. The right adrenal gland measured 0.21 cm. The left adrenal gland measured 0.25 cm.

Spleen

The **spleen** presented a smooth homogeneous parenchyma hyperechoic to liver and renal cortical parenchyma. The capsule was smooth without noticeable expansion or deviation from within the spleen or adjacent pathology. The splenic vasculature demonstrated normal volume without signs of congestion or thrombosis. No sonographic evidence of acute or chronic inflammatory, neoplastic, or infarctual changes was noted. The spleen measured 0.57 cm.

Liver

The **liver** images submitted revealed subjectively normal liver size, contour, and structure. Parenchymal echogenicity was naturally coarse and hypoechoic to the spleen. Vascular and biliary tracts were of normal volume with no evidence of congestion. The portal vein to vena cava ratio was 1:1 with no evidence of portosystemic shunting. The gallbladder presented acceptably thin walls with primarily anechoic content. The cystic and common bile ducts were normal. No pathological hepatic lymphadenopathy was evident. No overt structural evidence of inflammatory, infiltrative or regenerative pathology was evident.

IMAGING PERFORMED BYSVS Mobile Imaging MI 734-637-7711
svsimagingmi@gmail.com**PATIENT**

Gizmo Miller

SPECIES

Feline

BREED

Domestic Shorthair

SEX

Female

AGE

6 months

WEIGHT

3.6 lbs

Gastrointestinal

Examination of the **gastrointestinal tract** revealed a stomach free of stasis, of normal wall thickness, acceptable curvilinear mural detail, and peristaltic activity. The intestinal tract revealed diffuse, mild muscularis thickening. The submucosa and mucosal layers were intact. There was no evidence of luminal foreign bodies. Slight reactive mesenteric lymph nodes were noted. The epigastric lymph nodes are slightly enlarged. Trace amounts of free fluid was noted in the cranial abdomen likely owing to lymphatic congestion.

Pancreas

The base and limbs of the **pancreas** were observed to be largely isoechoic to surrounding omental fat. Pancreatic duct and capsular contour were acceptably normal and parenchyma respected normal curvilinear patterns. No overt evidence of active inflammatory or neoplastic disease was noted.

ULTRASONOGRAPHIC FINDINGS

Minor, non-specific, intestinal thickening with reactive epigastric and mesenteric lymph nodes.

Free fluid likely owing to lymphatic congestion.

Likely reactive hepatopathy owing to underlying GI disease.

Otherwise, unremarkable abdomen.

INTERPRETED BYEric Lindquist, DMV
DABVP, Cert. IVUSS**INTERPRETATION OF THE FINDINGS & FURTHER RECOMMENDATIONS**

Underlying parasitic disease, irritable bowel, dietary intolerance are all possible. Full thickness intestinal biopsies would be necessary for further definition. FNA of liver could be justified or biopsies if full thickness and surgical biopsies are to be performed.

IMAGING PERFORMED BY

Amy Mayhew LVT

HOSPITAL NAME

SVS Imaging Michigan

REFERRING VET

Family Pet Practice

The hepatic clinical sonographic presentation is most consistent with Reactive Hepatopathy which is the most common cause of liver enzyme elevation in dogs and cats. The presumption is that gut and other organ antigen stimuli may be causing a low-grade immune response through portal system with which the liver is reacting to causing low-grade enzyme elevations. US-guided FNA could be performed to assess if low grade lymphoplasmacytic inflammation is present that would support this theory. If FNA is performed, please ask the cytologist to emphasize the primary inflammatory cell type. Empirical treatment measures to address this issue can include diet change to hydrolyzed diet, probiotics, deworming, nutraceuticals (SAME, Actigall...), dental exam and cleaning, and potentially antibiotics such as Clavamox. Metronidazole and Tylosin have traditionally been utilized for this purpose but new studies show that both these antibiotics can disrupt the normal intestinal bacterial flora (intestinal dysbiosis) for weeks and up to 4-6 months. Therefore, Metronidazole and Tylosin should be utilized as a last resort if other efforts have not been effective and sonographic organ appearance remains benign.

INVOICE

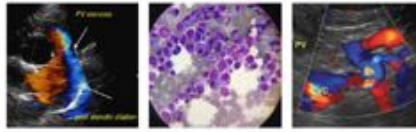
39900

DATE

10/4/22

IMAGING PERFORMED BY

SVS Mobile Imaging MI 734-637-7711
svsimagingmi@gmail.com



Clinical Sonography & Telecytology

EDUCATIONAL TELECONSULTATION SERVICES™

1-800-838-4268 info@sonopath.com SonoPath.com

PATIENT

Gizmo Miller

SPECIES

Feline

BREED

Domestic Shorthair

SEX

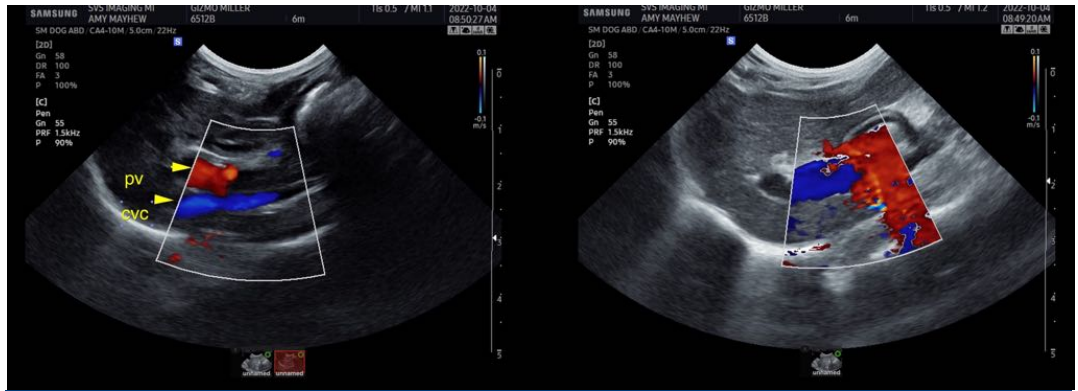
Female

AGE

6 months

WEIGHT

3.6 lbs



SEX

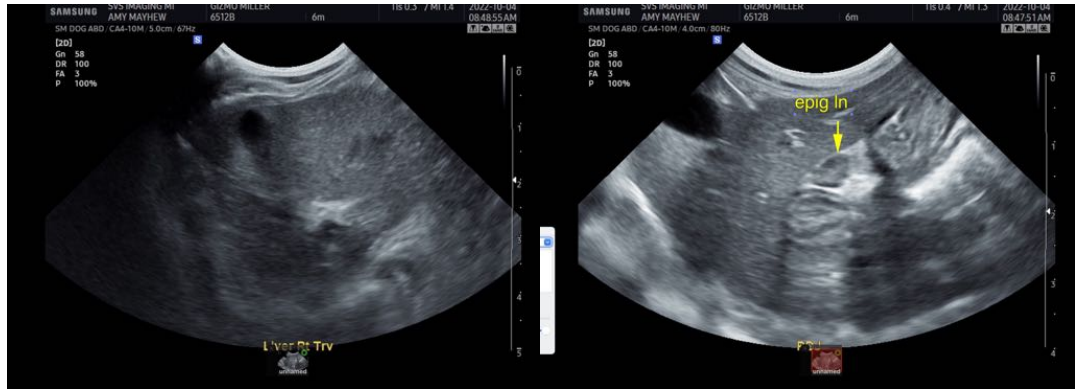
Female

AGE

6 months

WEIGHT

3.6 lbs



INTERPRETED BY

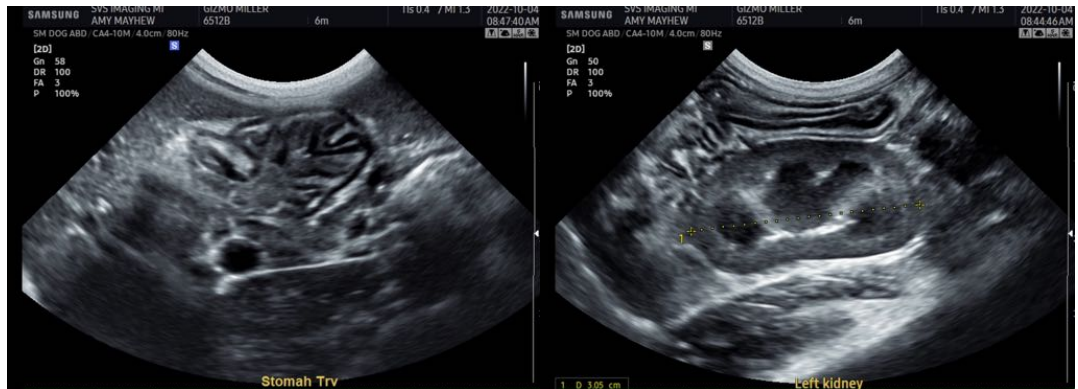
Eric Lindquist, DMV
DABVP, Cert. IVUSS

IMAGING PERFORMED BY

Amy Mayhew LVT

HOSPITAL NAME

SVS Imaging Michigan



REFERRING VET

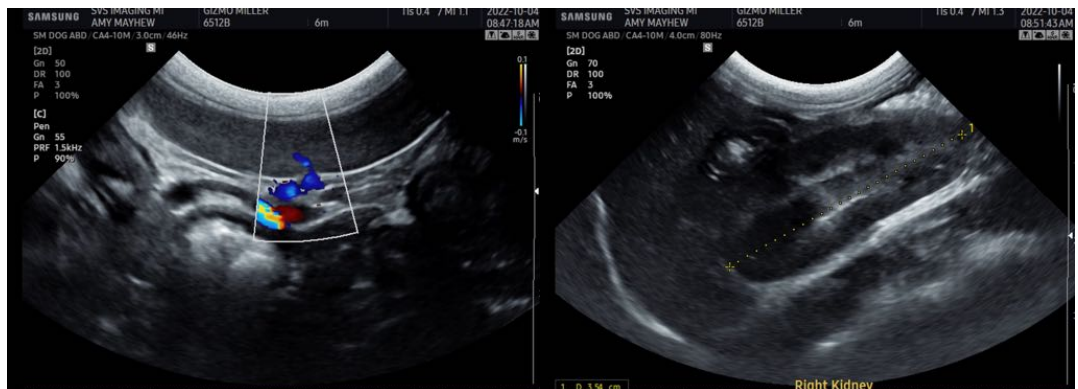
Family Pet Practice

INVOICE

39900

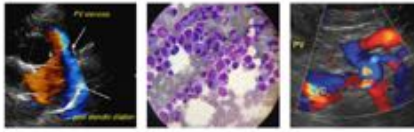
DATE

10/4/22



IMAGING PERFORMED BY

SVS Mobile Imaging MI 734-637-7711
svsimagingmi@gmail.com



EDUCATIONAL TELECONSULTATION SERVICES™
1-800-838-4268 info@sonopath.com SonoPath.com

PATIENT

Gizmo Miller

SPECIES

Feline

BREED

Domestic Shorthair

SEX

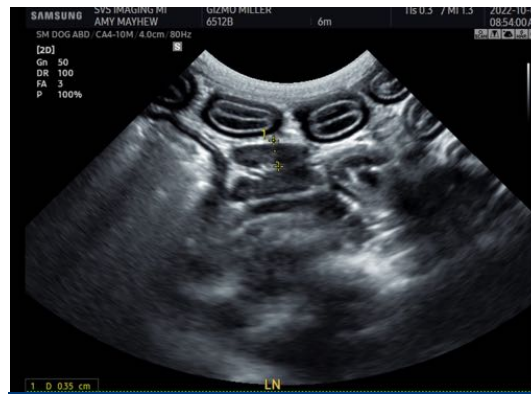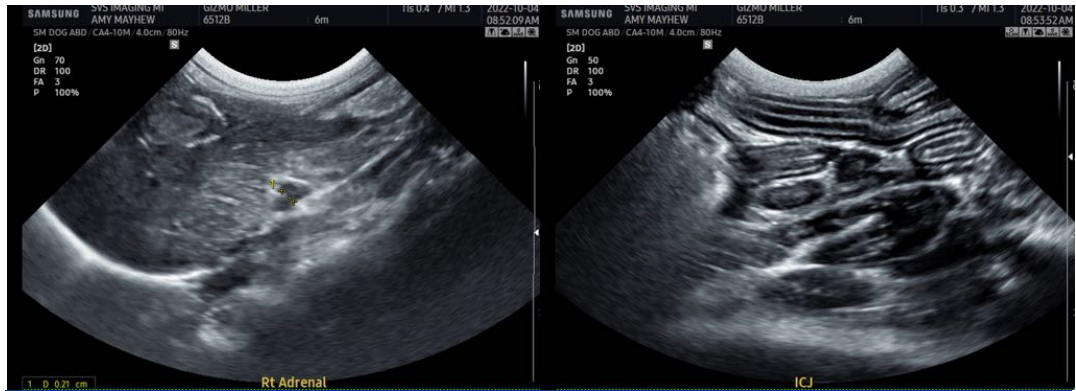
Female

AGE

6 months

WEIGHT

3.6 lbs



INTERPRETED BY

Eric Lindquist, DMV
DABVP, Cert. IVUSS

IMAGING PERFORMED BY

Amy Mayhew LVT

HOSPITAL NAME

SVS Imaging Michigan

REFERRING VET

Family Pet Practice

INVOICE

39900

DATE

10/4/22

The information and recommendations provided are based on the images presented by the referring veterinarian/sonographer. No evaluation can be communicated regarding pathology that was not visible in the image/video clips provided.

Thank you for this referral. If the clinical or image interpretation does not parallel your findings or if I can be of any further assistance please contact me.

Eric Lindquist, DMV, DABVP, Cert. IVUSS, CEO of SonoPath.com
Eric.Lindquist@SonoPath.com