



PATIENT

Bebe Kikengil

PRESENTING CLINICAL SIGNS

History: Hx of arrhythmia, on atenolol pre op echo for cystotomy

SPECIES

Feline

BREED

Domestic Shorthair

SEX

Neutered male

AGE

6 years

WEIGHT

13.3 lbs

INTERPRETED BY

Eric Lindquist, DMV
DABVP, Cert. IVUSS

IMAGING PERFORMED BY

Jenn

HOSPITAL NAME

Rockaway AH

REFERRING VET

Dr. Maniar

ULTRASONOGRAPHIC EXAMINATION OF THE HEART

The echocardiogram in this patient demonstrated normal **left atrial** size based on 3 separate LA measurements. Trivial **mitral** valve insufficiency was noted. The **left ventricle** presented normal thicknesses with linear contour and was not dilated nor restricted. A minor amount of **myocardial** remodeling was noted. **Contractility** of the ventricular walls was adequate and in normal range for this patient evidenced by the fractional shortening measurement and subjective evaluation of the different regions and angles of the myocardium. The **left ventricular outflow** tract demonstrated normal laminar flow and subjective structural integrity. The **right atrium** and auricle revealed normal size, structure and content. No evidence of masses was noted or chamber overload. **Tricuspid** valvular assessment demonstrated adequate linear morphology and kinetics. The **right ventricle** was of normal size (1/3 diameter of LV), chordae structure, myocardial echogenicity and thickness. **Pulmonic** tract assessment revealed normal valve structure, laminar flow, and diameter (approx.1:1 pa/ao ratio). No visible **pericardial** or free pleura fluid was noted or extra cardiac pathology in the visible planes. The cranial **mediastinum and pericardial regions** were free of masses in the visible window. Persistent arrhythmia was noted in this patient.

FELINE CARDIAC PARAMETERS	BODY WEIGHT	HR (BPM)	IVSd (cm)	LVIDd (cm)	LVWd (cm)	FS (%)	EF (%)
NORMAL PARAMETER	-----	150-240	0.3-0.6	1.0-2.1	0.25-0.6	35-67	80-100
PATIENT	13.3 lbs	NM	0.5	1.2	0.5	50	
FELINE CARDIAC PARAMETERS	LA/AO (Boon)	LA/AO HEART BASE (Sisson)	LA 2D 4-chamber long axis AS to FW (Sisson) (cm)		LVOT VEL. (m/s)	RVOT VEL. (m/s)	IVRT (m/)
NORMAL PARAMETER	<1.5	0.88-1.79	0.7-1.7		<1.6	<1.3	40-60
PATIENT		1.3					NM
Adapted from June Boon, Veterinary Echocardiography, 1998 Sisson D et al. JVIM 1991; 5: 232, Jacobs et al. Am J Vet Res 1985; 46:1705							

ULTRASONOGRAPHIC FINDINGS

Structurally and functionality unremarkable heart with normal volumes.

Significant arrhythmia.

Myocardial remodeling, may be playing a role in the arrhythmogenic activity.

INVOICE

89876

DATE

10/4/22



PATIENT

Bebe Kikengil

INTERPRETATION OF THE FINDINGS & FURTHER RECOMMENDATIONS

EKG is indicated. Treatment and anesthetic recommendations will be based on EKG findings. I do not recommend anesthesia until the EKG has been addressed.

SPECIES

Feline

BREED

Domestic Shorthair

SEX

Neutered male

AGE

6 years

WEIGHT

13.3 lbs

INTERPRETED BY

Eric Lindquist, DMV
DABVP, Cert. IVUSS

IMAGING PERFORMED BY

Jenn

HOSPITAL NAME

Rockaway AH

REFERRING VET

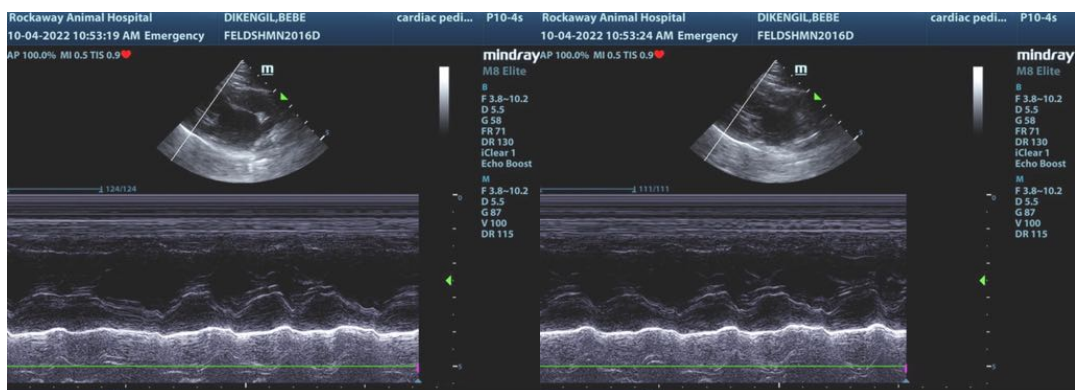
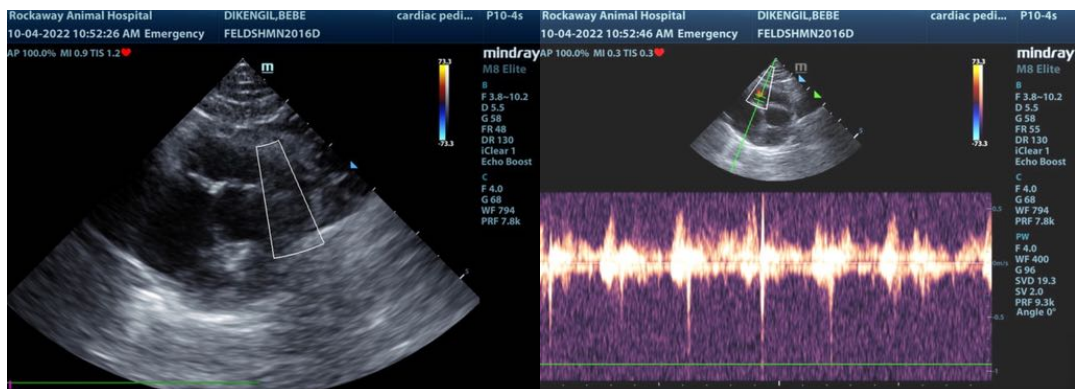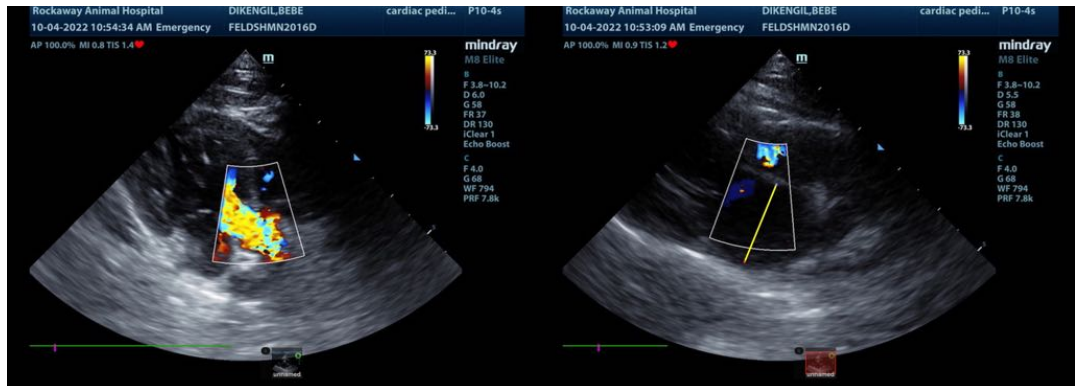Dr. Maniar

INVOICE

89876

DATE

10/4/22





PATIENT

Bebe Kikengil

SPECIES

Feline

BREED

Domestic Shorthair

SEX

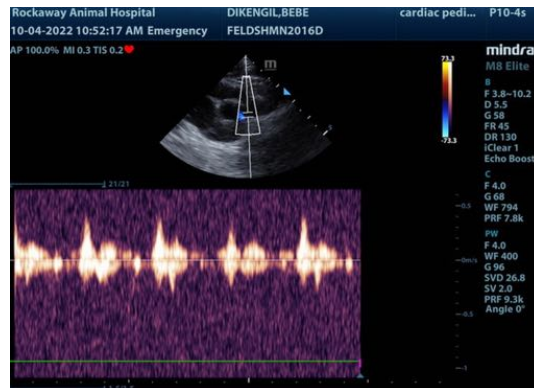
Neutered male

AGE

6 years

WEIGHT

13.3 lbs



The information and recommendations provided are based on the images presented by the referring veterinarian/sonographer. No evaluation can be communicated regarding pathology that was not visible in the image/video clips provided.

Thank you for this referral. If the clinical or image interpretation does not parallel your findings or if I can be of any further assistance please contact me.

Eric Lindquist, DMV, DABVP, Cert. IVUSS, CEO of SonoPath.com
info@SonoPath.com

INTERPRETED BY

Eric Lindquist, DMV
DABVP, Cert. IVUSS

IMAGING PERFORMED BY

Jenn

HOSPITAL NAME

Rockaway AH

REFERRING VET

Dr. Maniar

INVOICE

89876

DATE

10/4/22