



**PATIENT**

Purrfect Cleary

**PRESENTING CLINICAL SIGNS**

History: Wt loss of 1.5 lbs over last month, hyporexia, small hard stools, lethargy.  
Abnormal PE/Chem/CBC/UA Results: Total Body Function and UA pending.

**SPECIES**

Feline

**ULTRASONOGRAPHIC EXAMINATION OF THE ABDOMEN**

**Urinary System**

The **urinary bladder**, trigone, and pelvic urethra presented normal thicknesses and normal tone. The ureters were not visible which is normal. No uroliths or sediment were visualized and anechoic urine was present. No evidence of inflammatory or neoplastic changes was noted. Ureteral papillae were normal.

**BREED**

Domestic Shorthair

**SEX**

Spayed Female

The iliac trifurcation was unremarkable.

**AGE**

14 years

The **kidneys** revealed normal size and structure, corticomedullary definition and ratio for this age. The cortices presented largely uniform texture with normal echogenic relationship to liver and spleen. Medullary structure differed distinctly from the cortex and no evidence of pelvic dilation was present. The capsules were acceptably uniform without significant irregularities. The right kidney measured 3.15 cm. The left kidney measured 3.0 cm.

**WEIGHT**

9.6 lbs

**Adrenal Glands**

Both **adrenal glands** were visualized and recognized as having normal shape, size, position and echogenicity for this breed. The phrenic vasculature, glandular echogenicity and detail were unremarkable. Capsule, cortex, and medullary definition were normal for this age patient.

**INTERPRETED BY**

Eric Lindquist, DMV  
DABVP, Cert. IVUSS

**Spleen**

The **spleen** presented a smooth homogeneous parenchyma hyperechoic to liver and renal cortical parenchyma. The capsule was smooth without noticeable expansion or deviation from within the spleen or adjacent pathology. The splenic vasculature demonstrated normal volume without signs of congestion or thrombosis. No sonographic evidence of acute or chronic inflammatory, neoplastic, or infarctual changes was noted.

**IMAGING PERFORMED BY**

Dr. Prescott

**HOSPITAL NAME**

Roundout Valley VA

**Liver**

The **liver** images submitted revealed subjectively normal liver size, contour, and structure. Parenchymal echogenicity was naturally coarse and hypoechoic to the spleen. Vascular and biliary tracts were of normal volume with no evidence of congestion. The gallbladder presented acceptably thin walls with primarily anechoic content. The cystic and common bile ducts were normal. No pathological hepatic lymphadenopathy was evident. No overt structural evidence of inflammatory, infiltrative or regenerative pathology was evident.

**REFERRING VET**

Dr. Prescott

**INVOICE**

92144

**DATE**

10/4/21



**PATIENT**

**Gastrointestinal**

Purrfect Cleary

The **intestines** in this patient presented a concentric mass that appears to be jejunum. Ultrasound-guided FNA is warranted. The mass measures approximately 3.0 cm. The pylorus was patent and free of evident pathology. The colon was unremarkable. Slight regional lymphadenopathy was noted. The lymph node measured 0.5 cm and was adjacent to the mass.

**SPECIES**

Feline

**BREED**

Domestic Shorthair

**Pancreas**

The base and limbs of the **pancreas** were observed to be largely isoechoic to surrounding omental fat. Pancreatic duct and capsular contour were acceptably normal and parenchyma respected normal curvilinear patterns. No overt evidence of active inflammatory or neoplastic disease was noted.

**SEX**

Spayed Female

**ULTRASONOGRAPHIC FINDINGS**

Jejunal mass, possibly resectable.

**AGE**

14 years

Slight regional lymphadenopathy, suggestive of metastatic disease.

**WEIGHT**

9.6 lbs

**INTERPRETATION OF THE FINDINGS & FURTHER RECOMMENDATIONS**

There was no other evidence of significant pathology. Ultrasound-guided FNA is warranted or direct exploratory surgery if chest radiographs are free of evident pathology. However, often micrometastasis and other organs are present without sonographic appearance. FNA of the intestinal mass, spleen and liver would be ideal for staging. However, on ultrasound, there is no obvious involvement in the other organs.

**INTERPRETED BY**

Eric Lindquist, DMV  
DABVP, Cert. IVUS

**IMAGING PERFORMED BY**

Dr. Prescott

**HOSPITAL NAME**

Roundout Valley VA

**REFERRING VET**

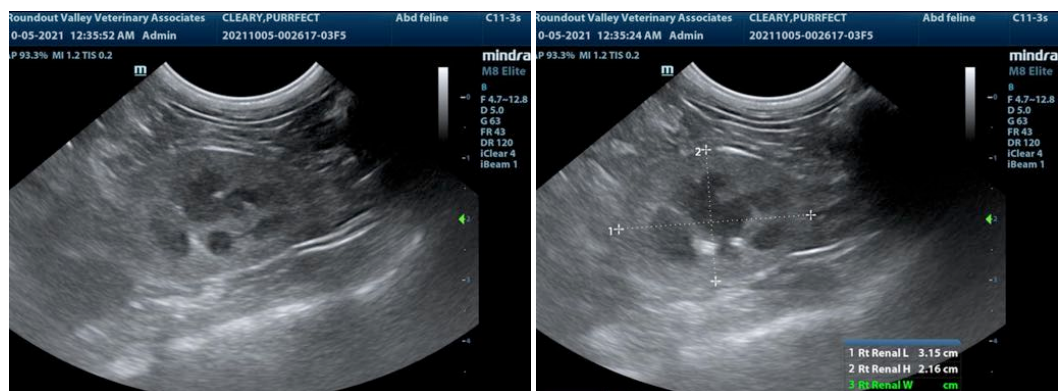
Dr. Prescott

**INVOICE**

92144

**DATE**

10/4/21





**PATIENT**

Purrfect Cleary

**SPECIES**

Feline

**BREED**

Domestic Shorthair

**SEX**

Spayed Female

**AGE**

14 years

**WEIGHT**

9.6 lbs

**INTERPRETED BY**

Eric Lindquist, DMV  
DABVP, Cert. IVUS

**IMAGING PERFORMED BY**

Dr. Prescott

**HOSPITAL NAME**

Roundout Valley VA

**REFERRING VET**

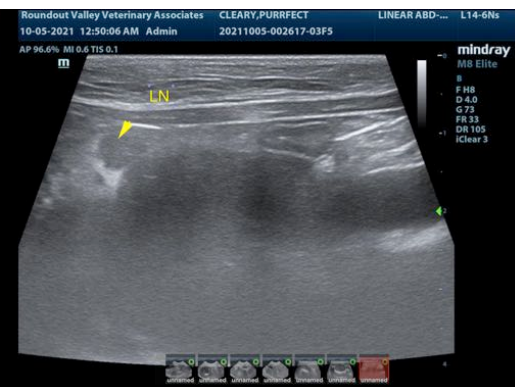
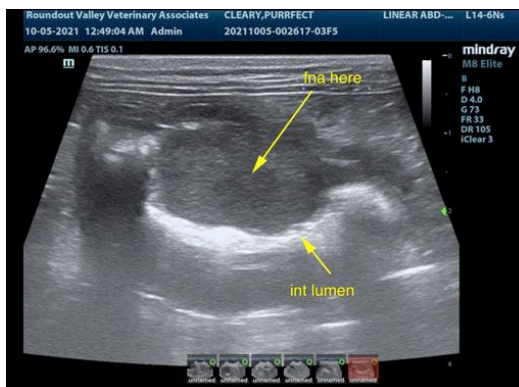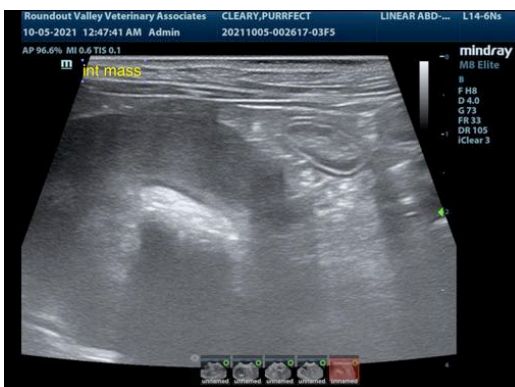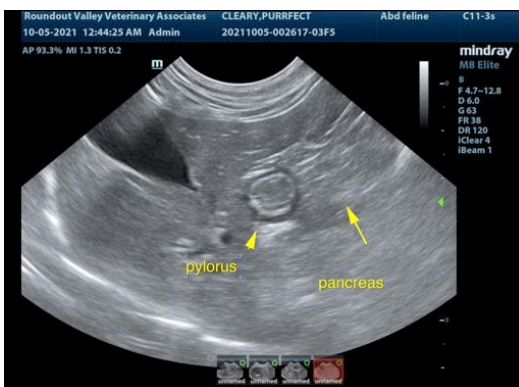
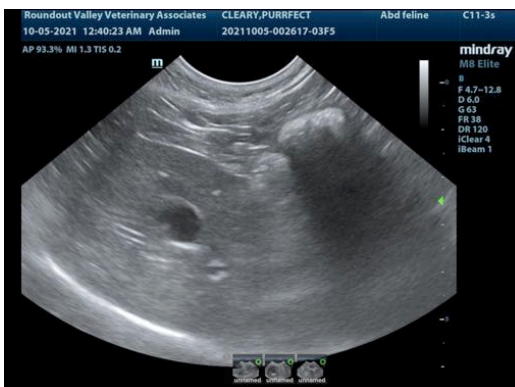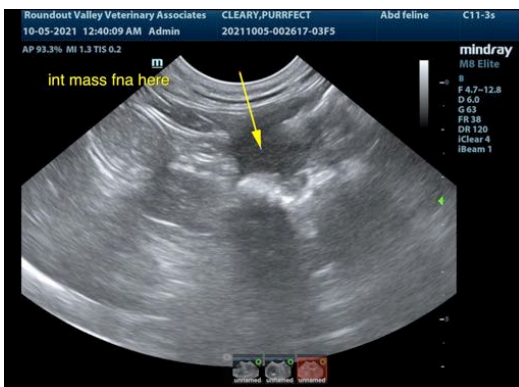
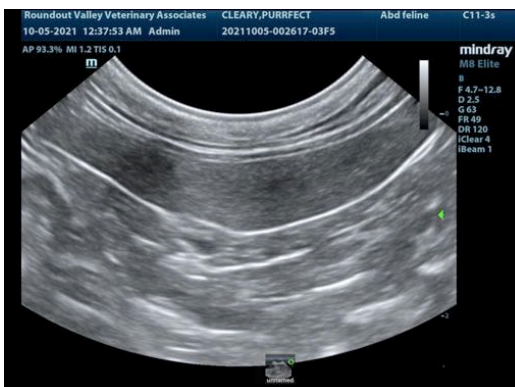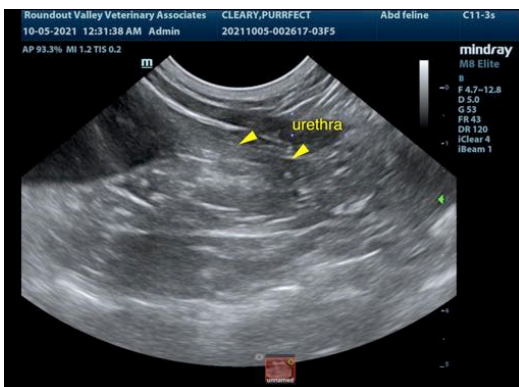
Dr. Prescott

**INVOICE**

92144

**DATE**

10/4/21





**PATIENT**

Purrfect Cleary

The information and recommendations provided are based on the images presented by the referring veterinarian. No evaluation can be communicated regarding pathology that was not visible in the image/video clips provided.

**SPECIES**

Feline

Thank you for this referral. If the clinical or image interpretation does not parallel your findings or if I can be of any further assistance please contact me.

**BREED**

Domestic Shorthair

**Eric Lindquist**, DMV, DABVP, Cert. IVUSS, CEO of SonoPath.com  
info@SonoPath.com

**SEX**

Spayed Female

**AGE**

14 years

**WEIGHT**

9.6 lbs

**INTERPRETED BY**

Eric Lindquist, DMV  
DABVP, Cert. IVUSS

**IMAGING PERFORMED BY**

Dr. Prescott

**HOSPITAL NAME**

Roundout Valley VA

**REFERRING VET**

Dr. Prescott

**INVOICE**

92144

**DATE**

10/4/21