



## PATIENT

Abby Massey

## SPECIES

Canine

## BREED

Cavachon

## SEX

Spayed Female

## AGE

12 Years

## WEIGHT

18.7 Pounds

## PRESENTING CLINICAL SIGNS

History: Patient presents for cardiomegaly, grade 3/6 holosystolic left-sided murmur, PMI 456. No reported meds.

Abnormal PE/Chem/CBC/UA Results:

## ULTRASONOGRAPHIC EXAMINATION OF THE HEART

CANINE CARDIAC PARAMETERS	MR VMAX (m/s)	TR VMAX (m/s)	LA/AO (Boon method)	LA/AO (Heart Base; Swe)	FS (%)	EF (%)	EPSS (cm)
NORMAL PARAMETER	4.5-5.5	<2.7	1.3	<1.6	28-40	40-100	<0.6
PATIENT	5.50	--	NM	1.1	35	66	0.1
CANINE CARDIAC PARAMETERS	HR (BPM)	AV VMAX (m/s)	PV MAX (m/s)	BODY WEIGHT (kg)	LA 2D short axis Base view (cm)	LVIDd Avg; 2D and m-mode short axis (cm)	LVIDs Avg; 2D and m-mode short axis (cm)
NORMAL PARAMETER	50-100	0.7-1.7	0.7-1.6	BELOW	BELOW	BELOW	BELOW
PATIENT	115	1.40	.93	--	2.91	3.03	--

## INTERPRETED BY

Eric Lindquist, DMV  
DABVP, Cert. IVUSS

## IMAGING PERFORMED BY

Kelly Vazquez

## HOSPITAL NAME

Westwood RVH

## REFERRING VET

Dr. Cattiny

## INVOICE

13504

## DATE

10/4/21

## Cardiac Presentation

The echocardiogram in this patient demonstrated normal **left atrial** size based on 3 different LA measurement methods. Chamber volumes and echogenicity were normal. The cranial and caudal **mitral** valve leaflets presented vegetative thickening consistent with endocardiosis. Doppler indicated measurable insufficiency. The **left ventricle** presented thicknesses with linear contour and was not dilated nor restricted. The **myocardium** presented normal echogenicity without subjective evidence of significant fibrotic or ischemic disease. **Contractility** of the ventricular walls was adequate and in normal range for this patient evidenced by the fractional shortening measurement and subjective evaluation of the different regions of the myocardium. The **left ventricular outflow** tract demonstrated normal laminar flow and subjective structural integrity. The **right atrium** and auricle revealed normal size, structure and content. No evidence of masses was noted or chamber overload. **Tricuspid** valvular assessment demonstrated adequate linear morphology. The **right ventricle** was of normal size (1/3 diameter of LV), chordae structure, myocardial echogenicity and thickness. **Pulmonic** tract assessment revealed normal valve structure, laminar flow, and diameter (approx.1:1 pa/ao ratio). No visible **pericardial** or free pleura fluid was noted. No echographically detectable evidence of infiltrative disease was visible. The cranial **mediastinum and pericardial regions** were free of masses in the visible window.

## ULTRASONOGRAPHIC FINDINGS

- Stage B1 valvular disease



**PATIENT**

Abby Massey

**SPECIES**

Canine

**BREED**

Cavachon

**SEX**

Spayed Female

**AGE**

12 Years

**WEIGHT**

18.7 Pounds

**INTERPRETED BY**

Eric Lindquist, DMV  
DABVP, Cert. IVUSS

**IMAGING PERFORMED BY**

Kelly Vazquez

**HOSPITAL NAME**

Westwood RVH

**REFERRING VET**

Dr. Cattiny

**INVOICE**

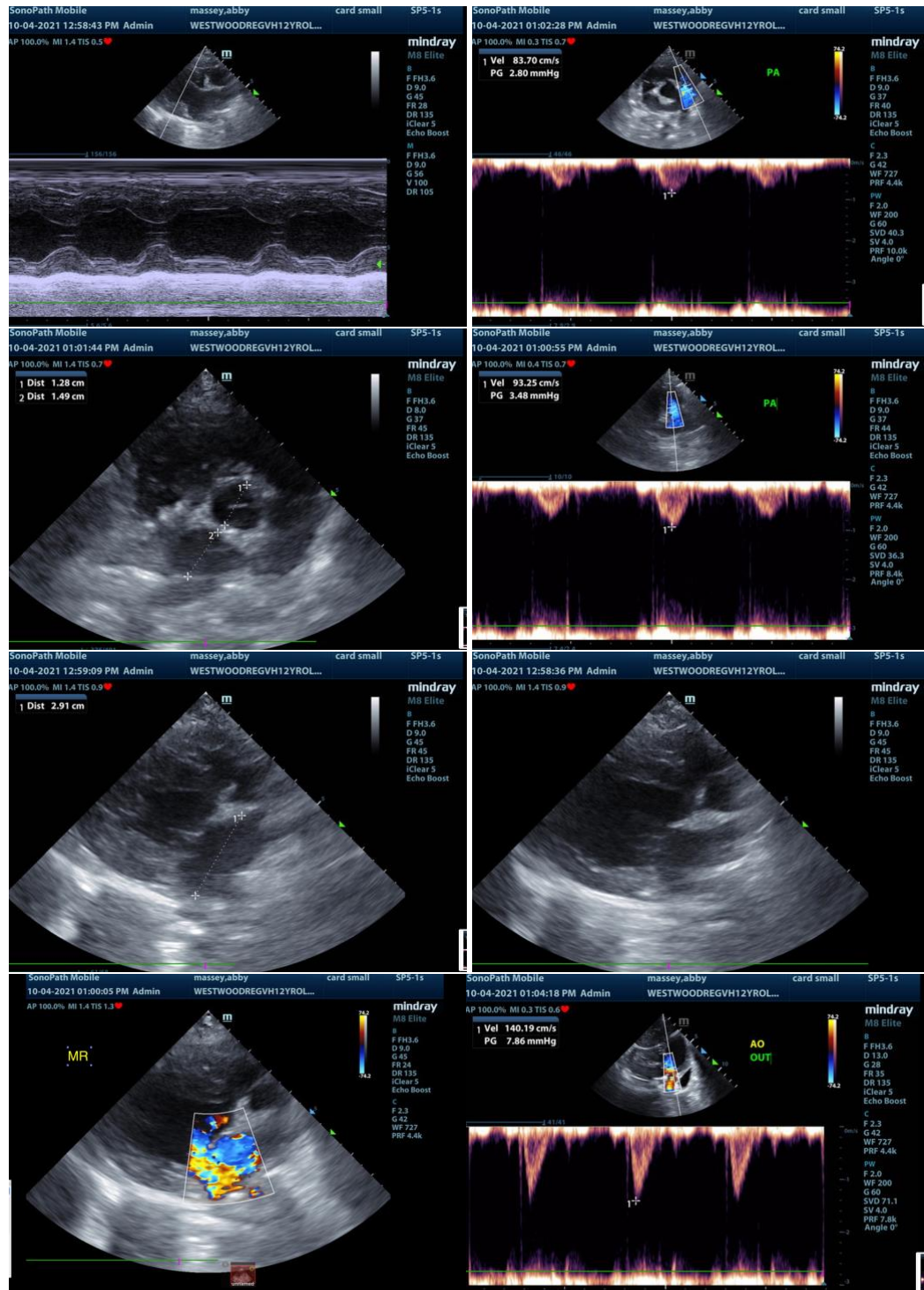
13504

**DATE**

10/4/21

**INTERPRETATION OF THE FINDINGS & FURTHER RECOMMENDATIONS**

No significant volume overload. Assessment of BUN, creatinine, USG, chest radiographs and blood pressure as well as clinical exam ideal in 7-10 days. Basal respiratory rate should be <20/min.





**PATIENT**

Abby Massey

**SPECIES**

Canine

**BREED**

Cavachon

**SEX**

Spayed Female

**AGE**

12 Years

**WEIGHT**

18.7 Pounds

**INTERPRETED BY**

Eric Lindquist, DMV  
DABVP, Cert. IVUSS

**IMAGING  
PERFORMED BY**

Kelly Vazquez

**HOSPITAL NAME**

Westwood RVH

**REFERRING VET**

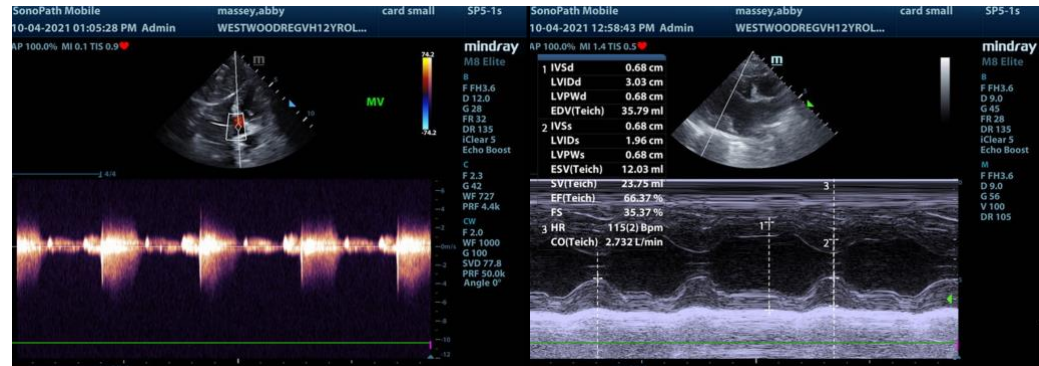
Dr. Cattiny

**INVOICE**

13504

**DATE**

10/4/21



The information and recommendations provided are based on the images presented by the referring veterinarian. No evaluation can be communicated regarding pathology that was not visible in the image/video clips provided.

Thank you for this referral. If the clinical or image interpretation does not parallel your findings or if I can be of any further assistance please contact me.

**Eric Lindquist**, DMV, DABVP, Cert. IVUSS, CEO of SonoPath.com  
info@SonoPath.com