



PATIENT

Precious Greaves

SPECIES

Feline

BREED

DSH

SEX

Female

AGE

6

WEIGHT

4.94

INTERPRETED BY

Eric Lindquist, DMV
DABVP, Cert. IVUSS

**IMAGING
PERFORMED BY**

Elyse Hauer

HOSPITAL NAME

Mariposa VH

REFERRING VET

Elyse Hauer

INVOICE

17978

DATE

10/31/22

PRESENTING CLINICAL SIGNS

History: New kitten introduced into home 8 days ago. Owners haven't seen her eat for 4 days, vomiting as well as non-productive retching. No bowel movements in several days. Minimal water intake. Very lethargic, not herself. Indoors only, not up to date on vaccination.

Abnormal PE/Chem/CBC/UA Results: CBC - normal. Chem - mild hyperglycemia suspect stress. U/A - USG 1.081 and 1+ glucose, proteinuria. On exam is breathing with very mild tachypnea, but no distress or open mouth breathing. Otherwise quiet, crusting on nose.

ULTRASONOGRAPHIC EXAMINATION OF THE ABDOMEN

Urinary System

The **urinary bladder**, trigone, and pelvic urethra presented normal thicknesses and normal tone. The ureters were not visible which is normal. No uroliths or sediment were visualized, and anechoic urine was present. No evidence of inflammatory or neoplastic changes were noted. Ureteral papillae were normal.

The **kidneys** were largely normal in size and contour, however, pericapsular inflammatory pattern was noted around the left kidney consistent with nephritis. Minor pyelectasia was present. The left kidney measured 4.12 cm. The right kidney measured 4.39 cm.

Adrenal Glands

The regions of the **adrenal glands** revealed no evident pathology.

Spleen

The **spleen** measured the upper limits of normal at 0.88 cm with subtle micronodular changes.

Liver

The **liver** was unremarkable, curvilinear patterns were maintained. The gallbladder and common bile duct were unremarkable.

Gastrointestinal

Examination of the **gastrointestinal tract** revealed a stomach and intestine free of stasis, of normal wall thickness, acceptable curvilinear mural detail, and peristaltic activity. Small and large intestine demonstrated normal luminal chyme and stool consistency respectively. No obstructive or overt infiltrative disease was noted. No associated abnormal lymphatic activity was noted.

Pancreas

The base and limbs of the **pancreas** were observed to be largely isoechoic to surrounding omental fat. Pancreatic duct and capsular contour were acceptably normal and parenchyma respected normal curvilinear patterns. No overt evidence of active inflammatory or neoplastic disease was noted.

Free Abdomen

The sonogram revealed a large amount of **falciform fat**, measuring up to 5.0 cm in width.

ULTRASONOGRAPHIC FINDINGS



PATIENT

Precious Greaves

- Nephritis pattern with minor pyelectasia
- Subtle micronodular changes in the spleen
- Excessive abdominal fat, particularly in the falciform ligament

SPECIES

Feline

INTERPRETATION OF THE FINDINGS & FURTHER RECOMMENDATIONS

Urinary work up is warranted in this patient. IV fluid support is warranted. Blood pressure measurements and urine culture are indicated. CNS, thoracic or orthopedic systems should be assessed. The only abdominal abnormality, other than excessive abdominal fat is the nephritis pattern in the left kidney.

BREED

DSH

SEX

Female

AGE

6

WEIGHT

4.94

INTERPRETED BY

Eric Lindquist, DMV
DABVP, Cert. IVUSS

IMAGING PERFORMED BY

Elyse Hauer

HOSPITAL NAME

Mariposa VH

REFERRING VET

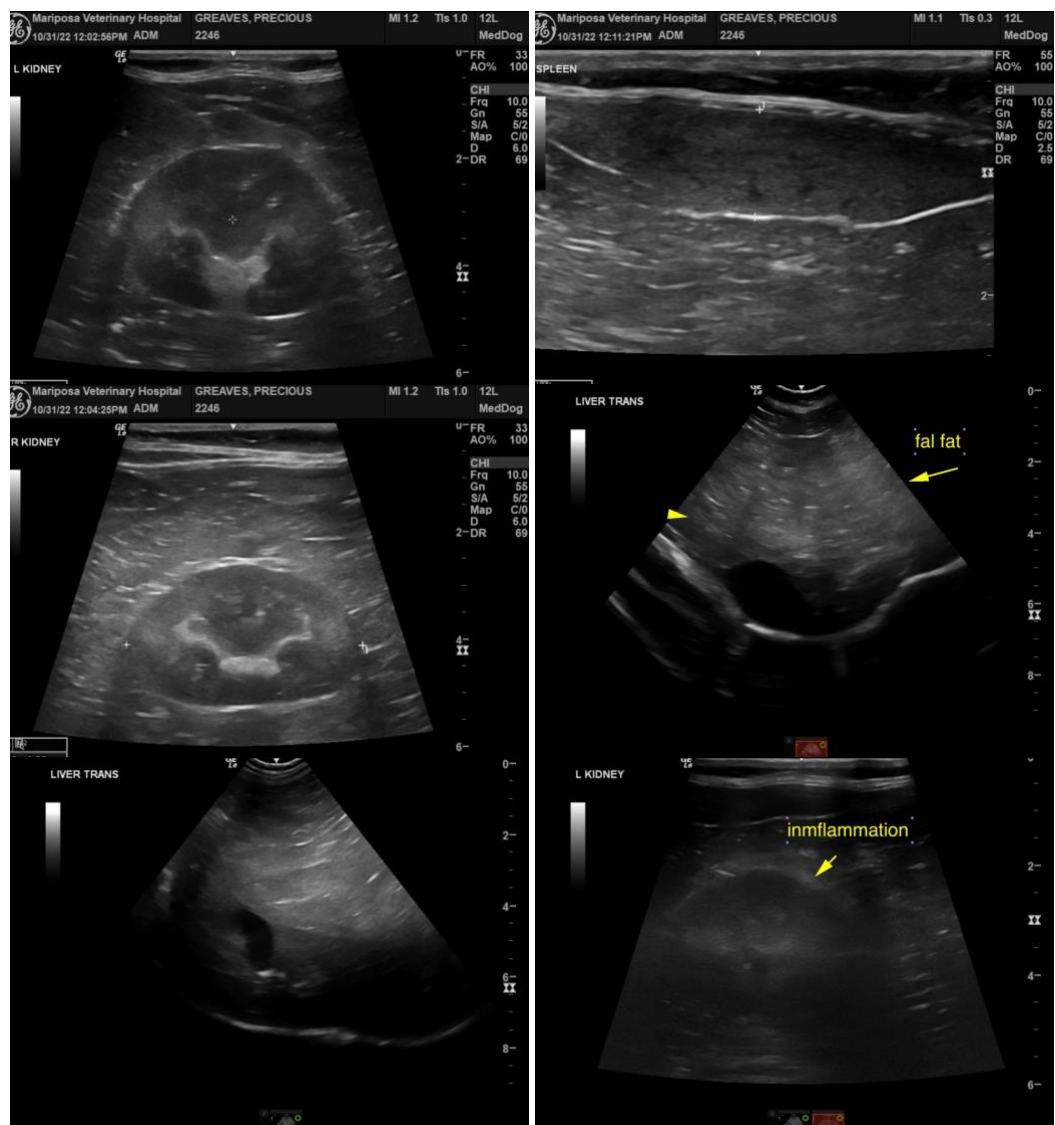
Elyse Hauer

INVOICE

17978

DATE

10/31/22





PATIENT

Precious Greaves

SPECIES

Feline

BREED

DSH

SEX

Female

AGE

6

WEIGHT

4.94

INTERPRETED BY

Eric Lindquist, DMV
DABVP, Cert. IVUSS

IMAGING PERFORMED BY

Elyse Hauer

HOSPITAL NAME

Mariposa VH

REFERRING VET

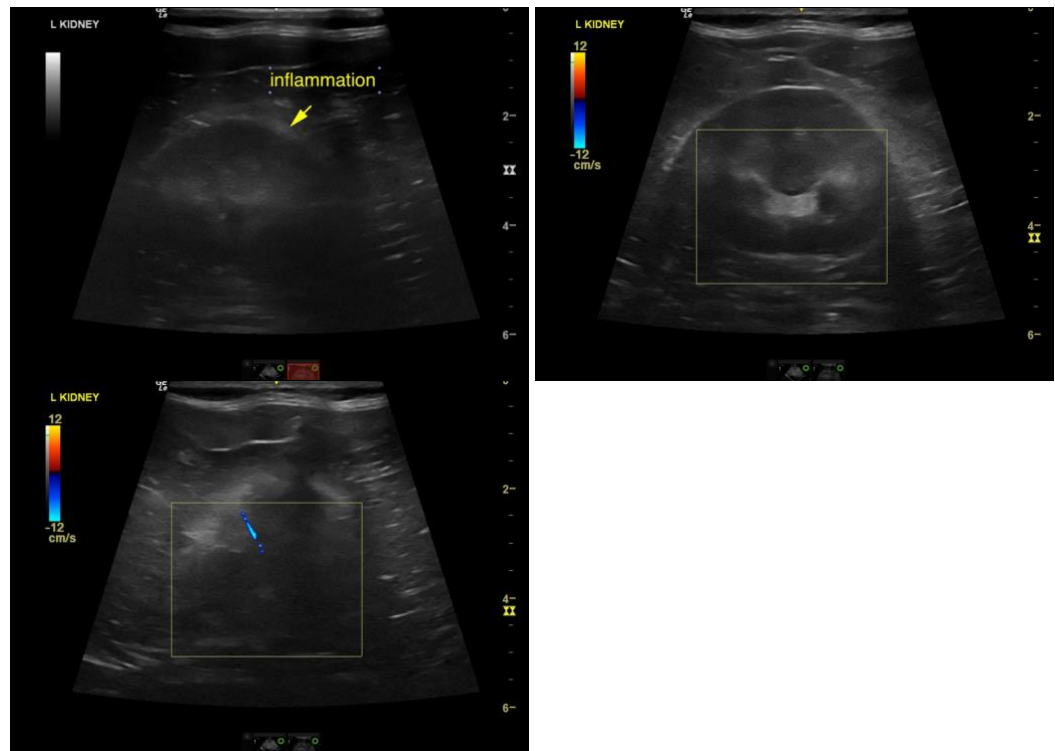
Elyse Hauer

INVOICE

17978

DATE

10/31/22



The information and recommendations provided are based on the images presented by the referring veterinarian. No evaluation can be communicated regarding pathology that was not visible in the image/video clips provided.

Thank you for this referral. If the clinical or image interpretation does not parallel your findings or if I can be of any further assistance please contact me.

Eric Lindquist, DMV, DABVP, Cert. IVUSS, CEO of SonoPath.com
info@SonoPath.com