



PATIENT

Garfield King

SPECIES

Feline

BREED

Domestic Shorthair

SEX

Neutered male

AGE

4 years

WEIGHT

13 lbs

INTERPRETED BY

Eric Lindquist, DMV
DABVP, Cert. IVUSS

IMAGING PERFORMED BY

Jill Rumachik

HOSPITAL NAME

Clarity Imaging LLC

PRESENTING CLINICAL SIGNS

History: 3-4 week hx of labored breathing/weight loss; otherwise, BAR and E/D/U/D normally

ULTRASONOGRAPHIC EXAMINATION OF THE HEART

The echocardiogram in this patient demonstrated **mitral** and **tricuspid** insufficiency with severe **right** and **left atrial enlargement**. The **left ventricle** presented normal thicknesses with linear contour and was not dilated nor restricted. The **myocardium** presented normal echogenicity without subjective evidence of significant fibrotic or ischemic disease. **Contractility** of the ventricular walls was adequate and in normal range for this patient evidenced by the fractional shortening measurement and subjective evaluation of the different regions and angles of the myocardium. The **left ventricular outflow** tract demonstrated normal laminar flow and subjective structural integrity. The **right ventricle** was of normal size (1/3 diameter of LV), chordae structure, myocardial echogenicity and thickness. **Pulmonic** tract assessment revealed normal valve structure, laminar flow, and diameter (approx.1:1 pa/ao ratio). **Pleural effusion** was noted with areas of lung consolidation. Periodic arrhythmia was noted.

| FELINE CARDIAC PARAMETERS | BODY WEIGHT (kg) | HR (BPM) | IVSd (cm) | LVIDd (cm) | LVWd (cm) | FS (%) | EF (%) |
|------------------------------------------------------------------------------------------------------------------------------------------|------------------------|------------------------------------|-----------------------------------------------------------|---------------|--------------------|--------------------|--------------|
| NORMAL PARAMETER | ----- | 150-240 | 0.3-0.6 | 1.0-2.1 | 0.25-0.6 | 35-67 | 80-100 |
| PATIENT | | NM | 0.87 | 1.3 | 0.86 | 45 | |
| FELINE CARDIAC PARAMETERS | LA/AO (Boon) | LA/AO HEART BASE (Sisson) | LA 2D 4-chamber long axis AS to FW (Sisson) (cm) | | LVOT VEL. (m/s) | RVOT VEL. (m/s) | IVRT (m/) |
| NORMAL PARAMETER | <1.5 | 0.88-1.79 | 0.7-1.7 | | <1.6 | <1.3 | 40-60 |
| PATIENT | > 3 | 3 | 2.8 | | | | NM |
| Adapted from June Boon, Veterinary Echocardiography, 1998 Sisson D et al. JVIM 1991; 5: 232, Jacobs et al. Am J Vet Res 1985; 46:1705 | | | | | | | |

REFERRING VET

Dr. Richardson

INVOICE

39855

DATE

10/3/22

ULTRASONOGRAPHIC FINDINGS

Left and right sided heart failure.

Feline cardiomyopathy. Hypertrophic phenotype.

Hepatic veins were dilated and ascites was present.

INTERPRETATION OF THE FINDINGS & FURTHER RECOMMENDATIONS

Lung consolidation, pleural effusion and ascites as well as left and right sided failure. Extremely guarded prognosis. I recommend Lasix at 1-2 mg/kg b.i.d., ace inhibitor at 0.5 mg/kg s.i.d., Plavix therapy at 18.75



PATIENT

Garfield King

SPECIES

Feline

mg/day/cat is recommended. Ace inhibitor should not be utilized if the patient is suspected to be a Maine coon. Spironolactone can be considered at 1-2 mg/kg b.i.d. Pimobendan can be considered as well; however, it is debatable on its use in hypertrophic cardiomyopathy patient's. A recheck echocardiogram is recommended in 2-4 weeks for refinement of therapy. I recommend to monitor BUN, creatinine, hydration status and blood pressure measurements as well as target sleeping respiratory rate < 25/minute. The patient is at high risk for sudden death.

BREED

Domestic Shorthair

SEX

Neutered male

AGE

4 years

WEIGHT

13 lbs

INTERPRETED BY

Eric Lindquist, DMV
DABVP, Cert. IVUSS

IMAGING PERFORMED BY

Jill Rumachik

HOSPITAL NAME

Clarity Imaging LLC

REFERRING VET

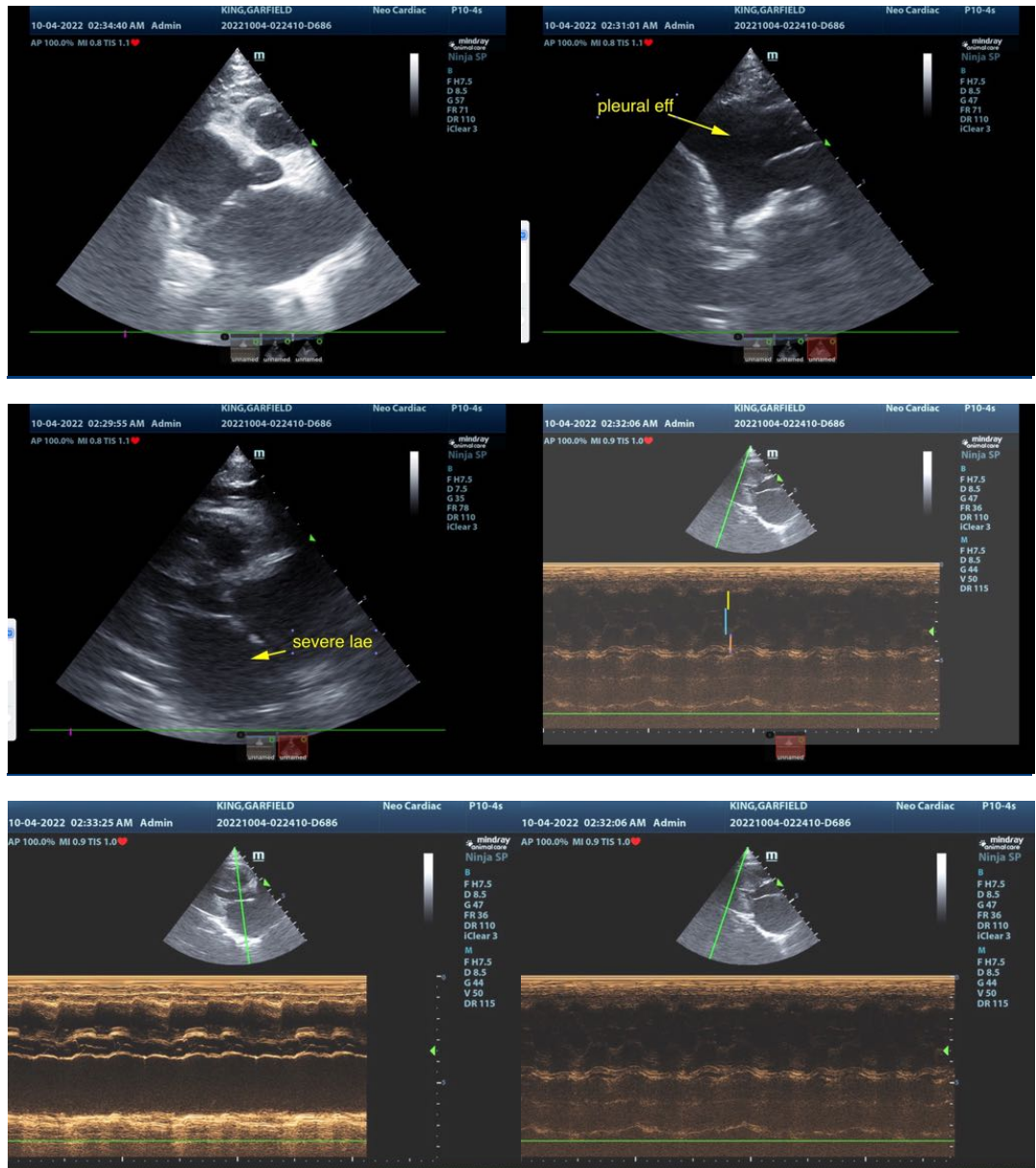
Dr. Richardson

INVOICE

39855

DATE

10/3/22





PATIENT

Garfield King

The information and recommendations provided are based on the images presented by the referring veterinarian/sonographer. No evaluation can be communicated regarding pathology that was not visible in the image/video clips provided.

SPECIES

Feline

Thank you for this referral. If the clinical or image interpretation does not parallel your findings or if I can be of any further assistance please contact me.

BREED

Domestic Shorthair

Eric Lindquist, DMV, DABVP, Cert. IVUSS, CEO of SonoPath.com
info@SonoPath.com

SEX

Neutered male

AGE

4 years

WEIGHT

13 lbs

INTERPRETED BY

Eric Lindquist, DMV
DABVP, Cert. IVUSS

**IMAGING
PERFORMED BY**

Jill Rumachik

HOSPITAL NAME

Clarity Imaging LLC

REFERRING VET

Dr. Richardson

INVOICE

39855

DATE

10/3/22