



PATIENT

Gunner OVC

SPECIES

Feline

BREED

Sphynx

SEX

Neutered Male

AGE

14 Years

WEIGHT

4.96

PRESENTING CLINICAL SIGNS

History: This is our clinic cat. Currently has a grade 3/6 systolic heart murmur and an irregularly irregular rhythm. Echo done while under GA (was anesthetized for unrelated skin biopsy).

Abnormal PE/Chem/CBC/UA Results: Last bloodwork Sept 2022 unremarkable, including T4

ULTRASONOGRAPHIC EXAMINATION OF THE HEART

FELINE CARDIAC PARAMETERS	BODY WEIGHT (kg)	HR (BPM)	IVSd (cm)	LVIDd (cm)	LVWd (cm)	FS (%)	EF (%)
NORMAL PARAMETER	-----	150-240	0.3-0.6	1.0-2.1	0.25-0.6	35-67	80-100
PATIENT	--	NM	0.4	1.35	0.35	--	--
FELINE CARDIAC PARAMETERS	LA/AO (Boon)	LA/AO HEART BASE (Sisson)	LA 2D 4-chamber long axis AS to FW (Sisson) (cm)	LVOT VEL. (m/s)	RVOT VEL. (m/s)	IVRT (m/)	
NORMAL PARAMETER	<1.5	0.88-1.79	0.7-1.7	<1.6	<1.3	40-60	
PATIENT	1.4	1.3	--	--	.80	NM	
Adapted from June Boon, Veterinary Echocardiography, 1998 Sisson D et al. JVIM 1991; 5: 232, Jacobs et al. Am J Vet Res 1985; 46:1705							

INTERPRETED BY

Eric Lindquist, DMV
DABVP, Cert. IVUSS

IMAGING PERFORMED BY

Stephanie Cory

HOSPITAL NAME

Orchard VC

REFERRING VET

Stephanie Cory

INVOICE

17969

DATE

10/29/22

Cardiac Presentation

The echocardiogram in this patient demonstrated normal **left atrial** size based on 3 separate methods of LA evaluation. The cranial and caudal **mitral** valve leaflets presented normal linear structure, extension in systole, and union in diastole with normal kinesis. The **left ventricle** presented thicknesses with linear contour and was not dilated nor restricted. The **myocardium** presented normal echogenicity without subjective evidence of significant fibrotic or ischemic disease.

Contractility of the ventricular walls was adequate and in normal range for this patient evidenced by the fractional shortening measurement and subjective evaluation of the different regions of the myocardium. The **left ventricular outflow** tract demonstrated normal laminar flow and subjective structural integrity. The **right atrium** and auricle revealed normal size, structure and content. No evidence of masses was noted. **Tricuspid** valvular assessment demonstrated adequate linear morphology and kinesis. The **right ventricle** was of normal size (1/3 diameter of LV), chordae structure, myocardial echogenicity and thickness. **Pulmonary outflow** tract assessment revealed normal valve structure, laminar flow, and diameter (approx.1:1 pa/ao ratio). No visible **pericardial** or free pleura fluid was noted. The cranial **mediastinum and pericardial and extra-cardiac regions** were free of masses in the visible window.

ULTRASONOGRAPHIC FINDINGS

- Normal echocardiogram

INTERPRETATION OF THE FINDINGS & FURTHER RECOMMENDATIONS



PATIENT

This is likely a flow murmur. No evidence of significant disease. Normal structure, chamber size and function.

Gunner OVC

SPECIES

Benign flow murmurs are common in cats. This may be owing to volume shifts, tachycardia, benign (DRVOTO) right ventricular outflow changes, trivial turbulence in any of the valvular apparatuses, or possibly excessive stethoscope pressure against the chest according to a recent study. These are physiologically benign and unrelated to specific pathology.

Feline

BREED

Sphynx

SEX

Neutered Male

AGE

14 Years

WEIGHT

4.96

INTERPRETED BY

Eric Lindquist, DMV
DABVP, Cert. IVUSS

IMAGING PERFORMED BY

Stephanie Cory

HOSPITAL NAME

Orchard VC

REFERRING VET

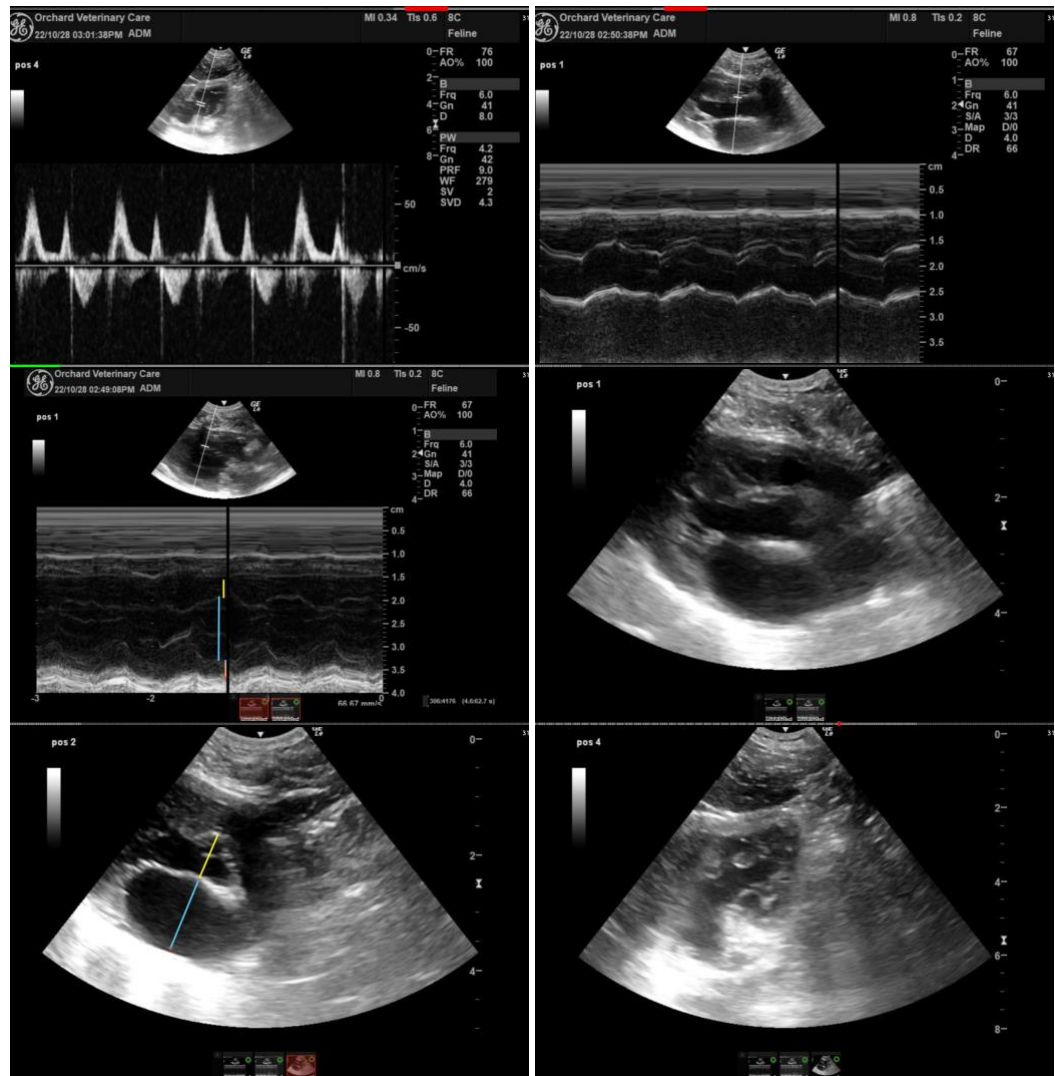
Stephanie Cory

INVOICE

17969

DATE

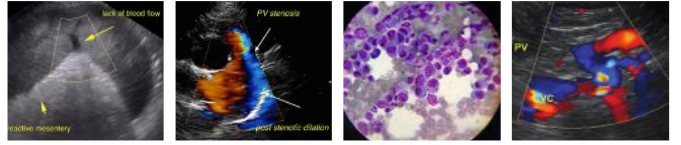
10/29/22



The information and recommendations provided are based on the images presented by the referring veterinarian. No evaluation can be communicated regarding pathology that was not visible in the image/video clips provided.

Thank you for this referral. If the clinical or image interpretation does not parallel your findings or if I can be of any further assistance please contact me.

Eric Lindquist, DMV, DABVP, Cert. IVUSS, CEO of SonoPath.com



PATIENT

info@SonoPath.com

Gunner OVC

SPECIES

Feline

BREED

Sphynx

SEX

Neutered Male

AGE

14 Years

WEIGHT

4.96

INTERPRETED BY

Eric Lindquist, DMV
DABVP, Cert. IVUSS

**IMAGING
PERFORMED BY**

Stephanie Cory

HOSPITAL NAME

Orchard VC

REFERRING VET

Stephanie Cory

INVOICE

17969

DATE

10/29/22