**DATE PRESENTING CLINICAL SIGNS**

10/29/21 History: Left testicle undescended. O wishes to neuter ASAP.

PATIENT

Thurman Purman
Degaitas

Current Medications: Not provided by the veterinarian.
 Lab Results: Not provided by the veterinarian.
 Radiographs: Not provided by the veterinarian.
 Date of Previous IntraPet Ultrasound: No previous IntraPet scans.
 Sedation: not needed
 Stat Report: not requested

SPECIES

Feline

BREED

Bengal

SEX

Intact Male

AGE

5/1/21

WEIGHT

7 Pounds

INTERPRETED BY

Eric Lindquist, DMV
DABVP, Cert. IVUSS

HOSPITAL NAME

Homeward Bound VS

REFERRING VET

Dr. Sorum

INVOICE

14098

LIMITED ULTRASONOGRAPHIC EXAMINATION

The urinary bladder, trigone, and pelvic urethra presented normal thicknesses and normal tone. The ureters were not visible which is normal. No uroliths or sediment were visualized and anechoic urine was present. No evidence of inflammatory or neoplastic changes were noted. Ureteral papillae were normal.

Just cranial to the urinary bladder, a 1.3 cm x 0.8 cm ovoid hypoechoic structure with what appears to be an epididymis was noted in this patient, most consistent with retained testicle.

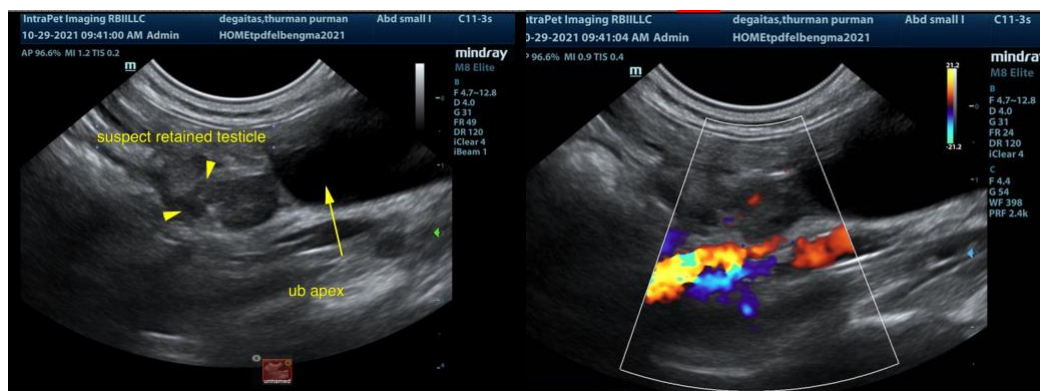
The kidneys revealed normal size and structure, corticomedullary definition and ratio for this age. The cortices presented largely uniform texture with normal echogenic relationship to liver and spleen. Medullary structure differed distinctly from the cortex and no evidence of pelvic dilation was present. The capsules were acceptably uniform without significant irregularities. The right kidney measured 3.47 cm. The left kidney measured 3.5 cm.

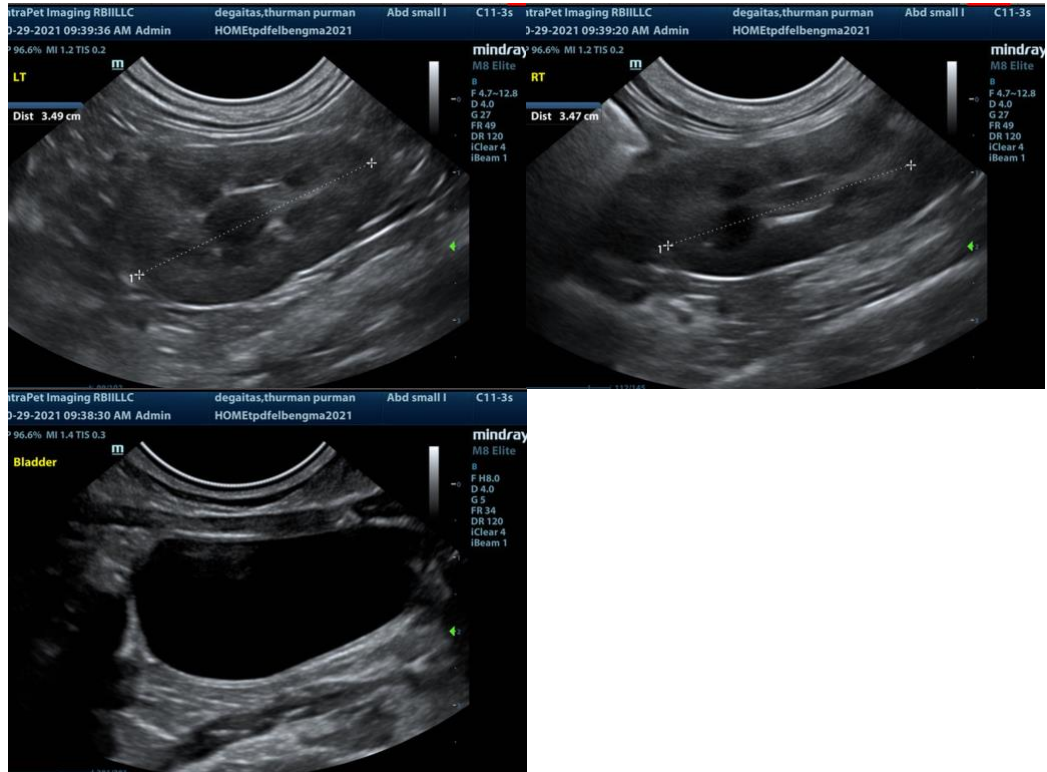
ULTRASONOGRAPHIC FINDINGS

- Suspect retained testicle just cranial to the urinary bladder
- Unremarkable urinary tract otherwise

INTERPRETATION OF THE FINDINGS & FURTHER RECOMMENDATIONS

I recommend abdominal exploratory at surgery.





The information and recommendations provided are based on the images presented by the referring veterinarian. No evaluation can be communicated regarding pathology that was not visible in the image/video clips provided.

Thank you for this referral. If the clinical or image interpretation does not parallel your findings or if I can be of any further assistance please contact me.

Eric Lindquist, DMV, DABVP, Cert. IVUSS, CEO of SonoPath.com
info@SonoPath.com