



**PATIENT**

Ryker Wierichs

**SPECIES**

Canine

**BREED**

Great Dane

**SEX**

Intact Male

**AGE**

5 Years

**WEIGHT**

158 Pounds

**INTERPRETED BY**

Eric Lindquist, DMV  
DABVP, Cert. IVUSS

**IMAGING PERFORMED BY**

Dr. Jill Rumachik

**HOSPITAL NAME**

Mazomanie AH

**REFERRING VET**

Dr. CC Sheldon

**INVOICE**

26773

**DATE**

10/29/21

**PRESENTING CLINICAL SIGNS**

Leaking copious amounts of yellow/green fluid from prepuce in past few weeks; u/a clear. Intact male dog. Not responsive to cephalexin. Prostate sampled - results pending.  
Abnormal PE/Chem/CBC/UA Results: BW 1 year ago WNL; swab from prepuce showed mostly degenerate neutrophils with short rod bacteria

**ULTRASONOGRAPHIC EXAMINATION OF THE ABDOMEN**

**Urinary System**

The **urinary bladder**, trigone, and pelvic urethra presented normal thicknesses and normal tone. The ureters were not visible which is normal. A minimal amount of urine was present at the time of the sonogram. No evidence of inflammatory or neoplastic changes were noted. Ureteral papillae were normal.

The **prostate** was uniformly enlarged with lobar swelling appeared to impinge upon the urethra and mildly deviate the descending colon. The prostatic tissue was hyperechoic containing focal areas of decreased echogenicity. These changes are suggestive of either chronic inflammatory episodes, benign cystic pathology or both. Underlying neoplasia cannot be completely ruled-out but is lower on the differential list. This presentation is most consistent with benign prostatic hyperplasia with possible active prostatitis. The prostate measured 5.4 cm in width.

The **kidneys** revealed normal size and structure, corticomedullary definition and ratio for this age. The cortices presented largely uniform texture with normal echogenic relationship to liver and spleen. Medullary structure differed distinctly from the cortex and no evidence of pelvic dilation was present. The capsules were acceptably uniform without significant irregularities. The left kidney measured 8.1 cm. The right kidney measured 8.0 cm.

**Adrenal Glands**

The **adrenal glands** were not visualized.

**Spleen**

The **spleen** was folded upon itself cranially and caudally, unremarkable abdomen otherwise.

**Liver**

The visible **liver** was unremarkable.

**Gastrointestinal**

The visible **gastrointestinal tract** was unremarkable.

**Pancreas**

The visible **pancreas** was unremarkable.

**ULTRASONOGRAPHIC FINDINGS**

- BPH prostate
- Folded spleen

**INTERPRETATION OF THE FINDINGS & FURTHER RECOMMENDATIONS**

Neutering should prove effective in this patient. If neutering is not an option, the following protocol may prove effective:



**PATIENT**

Ryker Wierichs

Off-label Finasteride (Propecia) (0.1-0.5 mg/kg Sid) treatment is indicated +/- FNA or prostatic wash cytology and culture.

**SPECIES**

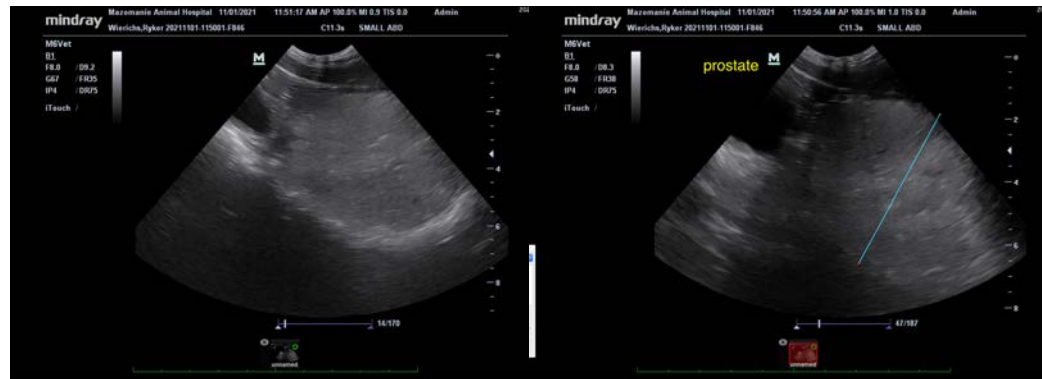
Canine

**BREED**

Great Dane

**SEX**

Intact Male



**AGE**

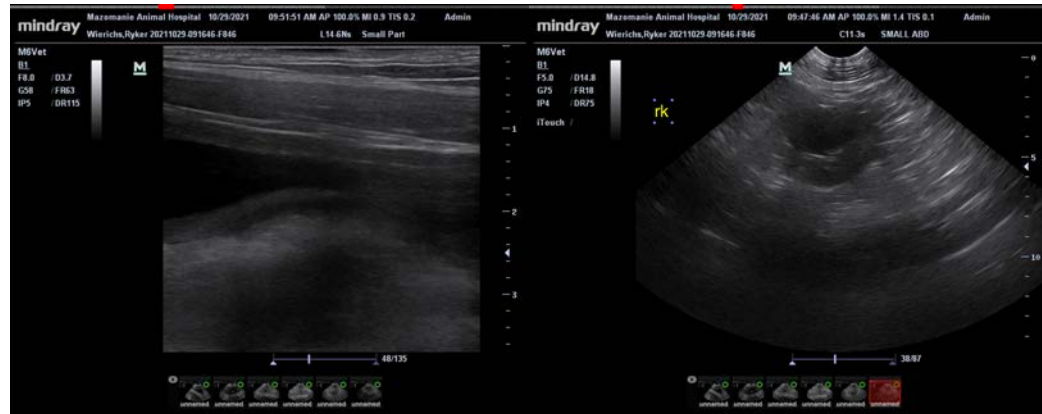5 Years

**WEIGHT**

158 Pounds

**INTERPRETED BY**

Eric Lindquist, DMV  
DABVP, Cert. IVUSS



**IMAGING PERFORMED BY**

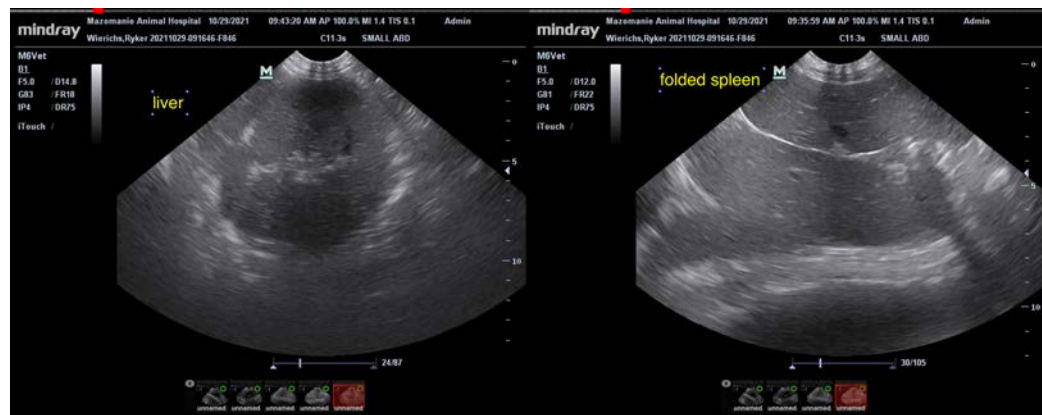
Dr. Jill Rumachik

**HOSPITAL NAME**

Mazomanie AH

**REFERRING VET**

Dr. CC Sheldon



**INVOICE**

26773

**DATE**

10/29/21



**PATIENT**

Ryker Wierichs

**SPECIES**

Canine

**BREED**

Great Dane

**SEX**

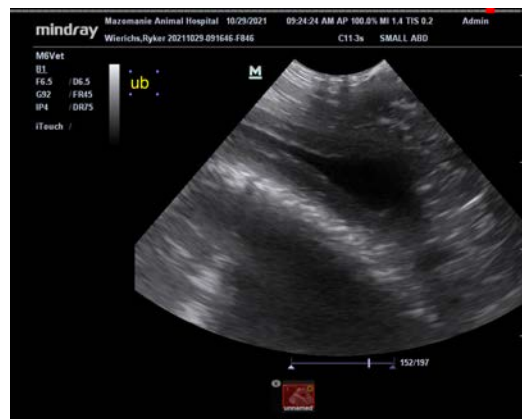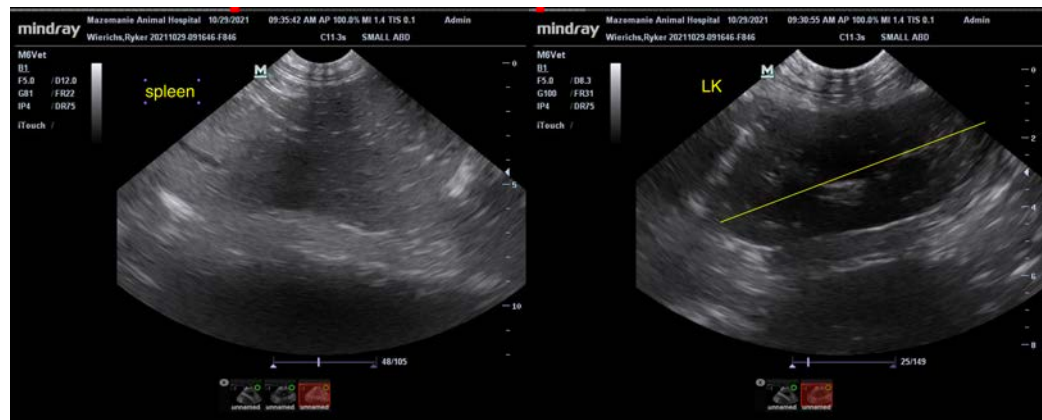Intact Male

**AGE**

5 Years

**WEIGHT**

158 Pounds



**INTERPRETED BY**

Eric Lindquist, DMV  
DABVP, Cert. IVUSS

**IMAGING PERFORMED BY**

Dr. Jill Rumachik

**HOSPITAL NAME**

Mazomanie AH

**REFERRING VET**

Dr. CC Sheldon

**INVOICE**

26773

**DATE**

10/29/21

The information and recommendations provided are based on the images presented by the referring veterinarian. No evaluation can be communicated regarding pathology that was not visible in the image/video clips provided.

Thank you for this referral. If the clinical or image interpretation does not parallel your findings or if I can be of any further assistance please contact me.

Eric Lindquist, DMV, DABVP, Cert. IVUSS, CEO of SonoPath.com  
[info@SonoPath.com](mailto:info@SonoPath.com)