



PATIENT

Porkchop Vasapollo

SPECIES

Feline

BREED

Domestic Shorthair

SEX

Neutered male

AGE

12 years

INTERPRETED BY

Eric Lindquist, DMV
DABVP, Cert. IVUSS

IMAGING PERFORMED BY

Eric Lindquist, DMV
DABVP, Cert. IVUSS

HOSPITAL NAME

Greenwood Lakes AH

REFERRING VET

Dr. Louer

INVOICE

92754

DATE

10/29/21

PRESENTING CLINICAL SIGNS

Chronic vomiting/diarrhea. CA increased, weight loss.
CA 12.1, PSL 77, CPK 540, rest WNL, CBC Normal. T4 2.0

ULTRASONOGRAPHIC EXAMINATION OF THE ABDOMEN

Urinary System

The **urinary bladder**, trigone, and pelvic urethra presented normal thicknesses and normal tone. The ureters were not visible which is normal. No uroliths or sediment were visualized and anechoic urine was present. No evidence of inflammatory or neoplastic changes was noted. Ureteral papillae were normal.

The **kidneys** revealed largely normal size and structure, corticomedullary definition and ratio (cortex 1/3 of medulla) were essentially maintained with some age-related loss of curvilinear patterns regarding the capsule and C/M junction. The cortices presented largely uniform texture with some increased echogenicity expected for this age patient. Medullary structure differed distinctly from that of the cortex and no evidence of pelvic dilation was present. The left kidney measured 4.29 cm.

Adrenal Glands

Both **adrenal glands** were visualized and recognized as having normal shape, size, position and echogenicity for this breed. The phrenic vasculature, glandular echogenicity and detail were unremarkable. Capsule, cortex, and medullary definition were normal for this age patient.

Spleen

The **spleen** presented a smooth homogeneous parenchyma hyperechoic to liver and renal cortical parenchyma. The capsule was smooth without noticeable expansion or deviation from within the spleen or adjacent pathology. The splenic vasculature demonstrated normal volume without signs of congestion or thrombosis. No sonographic evidence of acute or chronic inflammatory, neoplastic, or infarctual changes was noted.

Liver

The **liver** images submitted revealed subjectively normal liver size, contour, and structure. Parenchymal echogenicity was naturally coarse and hypoechoic to the spleen. Vascular and biliary tracts were of normal volume with no evidence of congestion. The gallbladder presented acceptably thin walls with primarily anechoic content. The cystic and common bile ducts were normal. No pathological hepatic lymphadenopathy was evident. No overt structural evidence of inflammatory, infiltrative or regenerative pathology was evident.



PATIENT

Gastrointestinal

Porkchop Vasapollo

The **gastrointestinal** presentation revealed mild uniform prominence of the gastric mucosa as well as areas of "ropey" small intestinal wall with slight disruption of the normal 1:3 muscularis/mucosal ratio. The intestinal submucosa was slightly irregular, thickened and hyperechoic suggestive of low grade, chronic disease. No evidence of obstruction was present. Chronic inflammatory bowel disease is likely with a low possibility of an early neoplastic event such as lymphoma. Full thickness tissue biopsies via open laparotomy, ideally guided by intraoperative ultrasound in order to obtain the most representative mural sample, would be necessary to rule out this possibility. The mesenteric lymph nodes are reactive. The largest of which measured 2.13 x 0.82 cm.

SPECIES

Feline

BREED

Domestic Shorthair

SEX

Neutered male

Pancreas

The **pancreas** was enlarged, hypoechoic and irregular with undulating contour.

AGE

12 years

ULTRASONOGRAPHIC FINDINGS

Prominent pancreas.

Chronic intestinal thickening.

Reactive mesenteric lymph nodes.

INTERPRETED BY

Eric Lindquist, DMV
DABVP, Cert. IVUSS

INTERPRETATION OF THE FINDINGS & FURTHER RECOMMENDATIONS

The Prednisolone may be suppressing a more significant presentation. Full thickness GI, lymph node and pancreatic biopsies would be ideal. Maldigestion panel is indicated. Empirical treatment with B12 injections, Prednisolone +/- Leukeran and hydrolyzed diet is all indicated.

IMAGING PERFORMED BY

Eric Lindquist, DMV
DABVP, Cert. IVUSS

HOSPITAL NAME

Greenwood Lakes AH

REFERRING VET

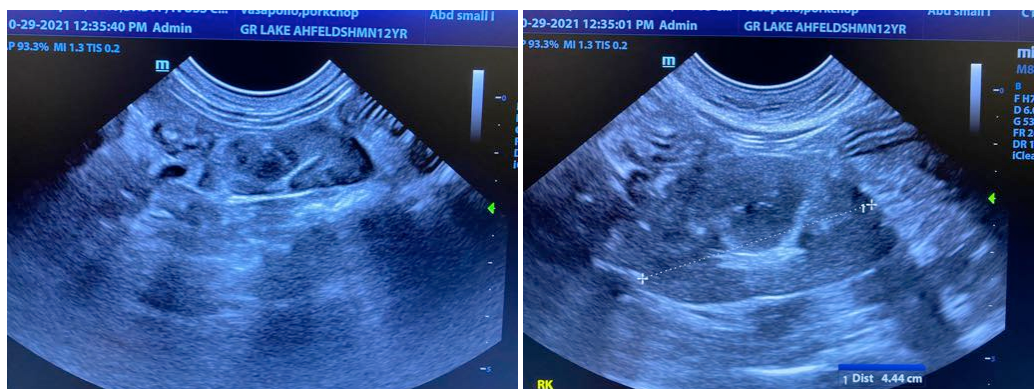
Dr. Louer

INVOICE

92754

DATE

10/29/21





PATIENT

Porkchop Vasapollo

SPECIES

Feline

BREED

Domestic Shorthair

SEX

Neutered male

AGE

12 years

INTERPRETED BY

Eric Lindquist, DMV, DABVP, Cert. IVUSS

IMAGING PERFORMED BY

Eric Lindquist, DMV, DABVP, Cert. IVUSS

HOSPITAL NAME

Greenwood Lakes AH

REFERRING VET

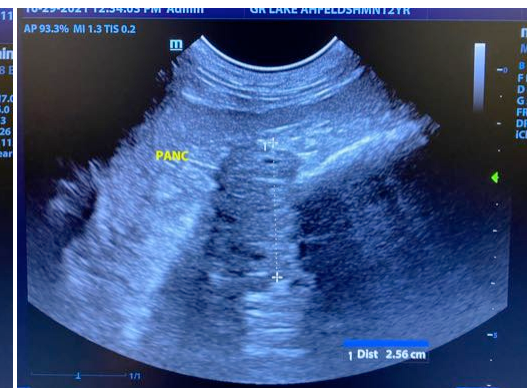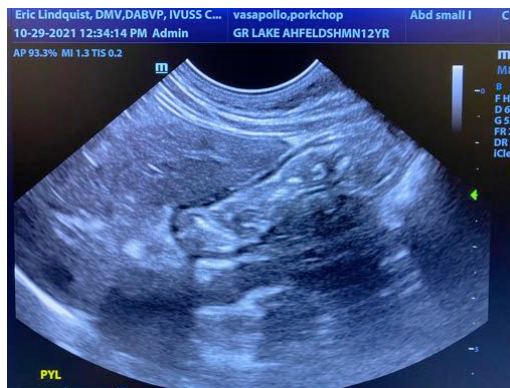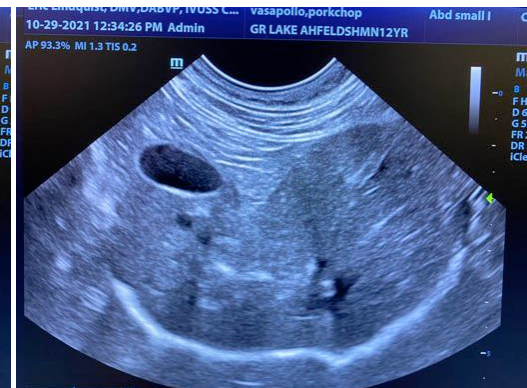
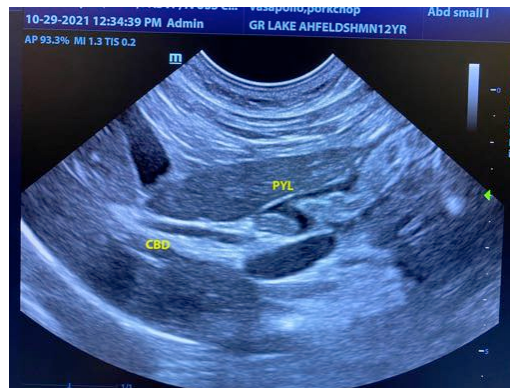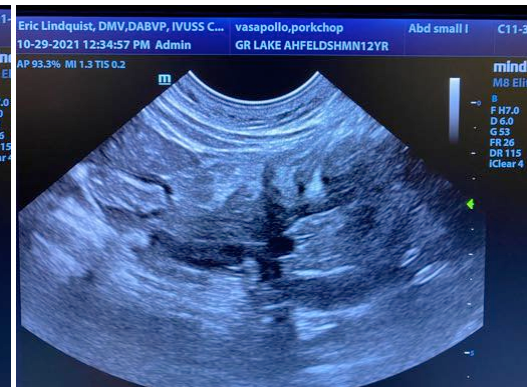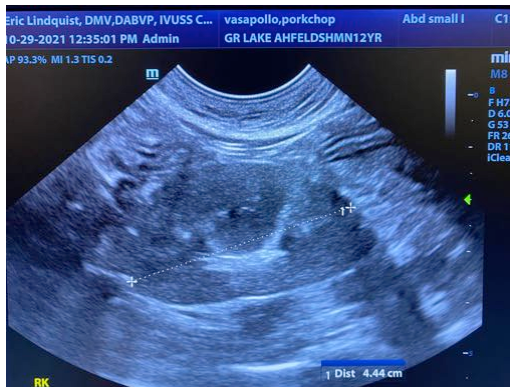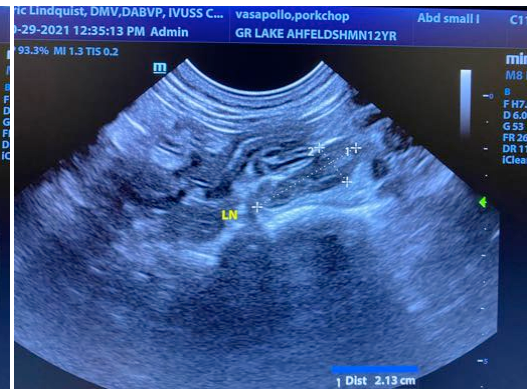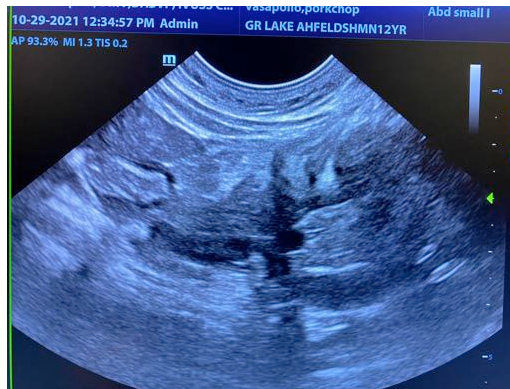Dr. Louer

INVOICE

92754

DATE

10/29/21





PATIENT

Porkchop Vasapollo

SPECIES

Feline

BREED

Domestic Shorthair

SEX

Neutered male

AGE

12 years

INTERPRETED BY

Eric Lindquist, DMV
DABVP, Cert. IVUSS

IMAGING PERFORMED BY

Eric Lindquist, DMV
DABVP, Cert. IVUSS

HOSPITAL NAME

Greenwood Lakes AH

REFERRING VET

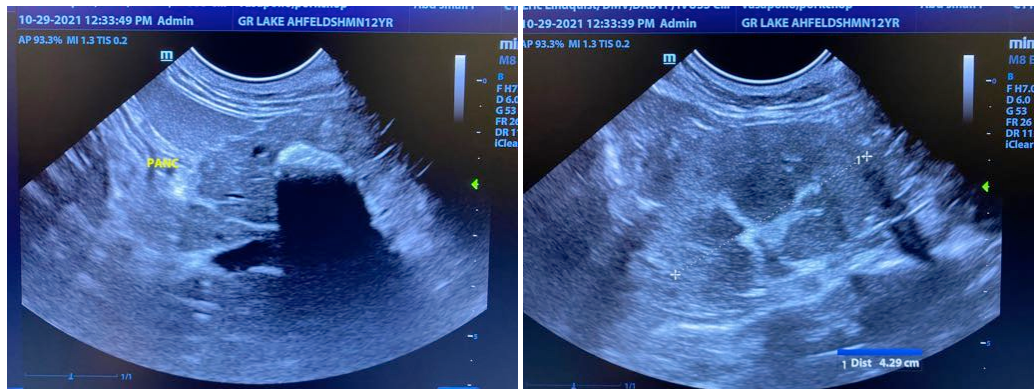
Dr. Louer

INVOICE

92754

DATE

10/29/21



The information and recommendations provided are based on the images presented by the referring veterinarian. No evaluation can be communicated regarding pathology that was not visible in the image/video clips provided.

Thank you for this referral. If the clinical or image interpretation does not parallel your findings or if I can be of any further assistance please contact me.

Eric Lindquist, DMV, DABVP, Cert. IVUSS, CEO of SonoPath.com
Info@SonoPath.com