



PATIENT

Brady Raimond

PRESENTING CLINICAL SIGNS

6 month recheck echo; no clinical signs
Abnormal PE/Chem/CBC/UA Results: pending but in July all normal

SPECIES

Canine

ULTRASONOGRAPHIC EXAMINATION OF THE HEART

BREED

Doberman X

SEX

Neutered Male

AGE

8 Years

WEIGHT

76.6 Pounds

CANINE CARDIAC PARAMETERS	MR VMAX (m/s)	TR VMAX (m/s)	LA/AO (Boon method)	LA/AO (Heart Base; Swe)	FS (%)	EF (%)	EPSS (cm)
NORMAL PARAMETER	4.5-5.5	<2.7	1.3	<1.6	28-40	40-100	<0.6
PATIENT	5.0		1.15	1.32	37	67	0.3
CANINE CARDIAC PARAMETERS	HR (BPM)	AV VMAX (m/s)	PV MAX (m/s)	BODY WEIGHT (kg)	LA 2D short axis Base view (cm)	LVIDd Avg; 2D and m-mode short axis (cm)	LVIDs Avg; 2D and m-mode short axis (cm)
NORMAL PARAMETER	50-100	0.7-1.7	0.7-1.6				
PATIENT	127		0.5		4.84	4.53	

Cardiac Presentation

The cardiac presentation revealed normal volumes and contractility with largely normal structure. Persistent mitral insufficiency noted, compensated. No evidence of volume overload.

INTERPRETED BY

Eric Lindquist, DMV
DABVP, Cert. IVUSS

ULTRASONOGRAPHIC FINDINGS

- Persistent compensated Stage B1 valvular disease

IMAGING PERFORMED BY

Diane McFadden

INTERPRETATION OF THE FINDINGS & FURTHER RECOMMENDATIONS

No evidence of volume overload or cardiac dysfunction. Assessment of BUN, creatinine, USG, chest radiographs and blood pressure as well as clinical exam ideal in 7-10 days. Basal respiratory rate should be <20/min.

HOSPITAL NAME

Parsippany Troy Hills

REFERRING VET

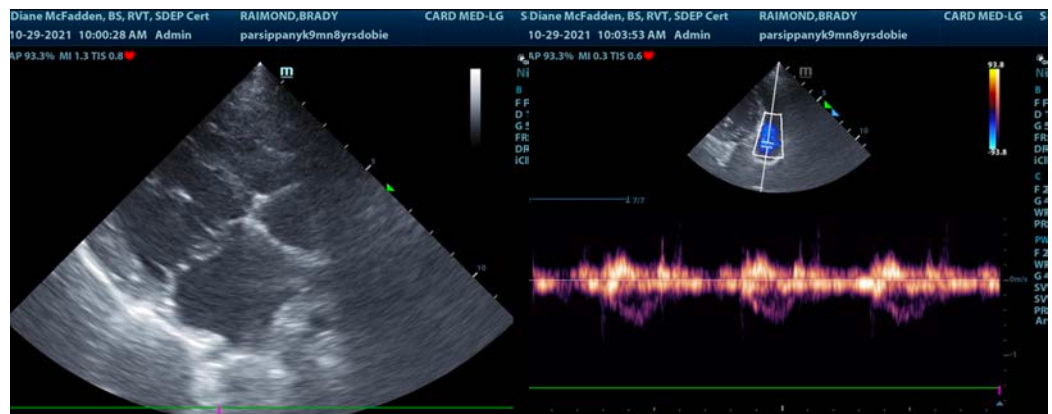
Dr Dulude

INVOICE

26746

DATE

10/29/21





PATIENT

Brady Raimond

SPECIES

Canine

BREED

Doberman X

SEX

Neutered Male

AGE

8 Years

WEIGHT

76.6 Pounds

INTERPRETED BY

Eric Lindquist, DMV
DABVP, Cert. IVUSS

IMAGING PERFORMED BY

Diane McFadden

HOSPITAL NAME

Parsippany Troy Hills

REFERRING VET

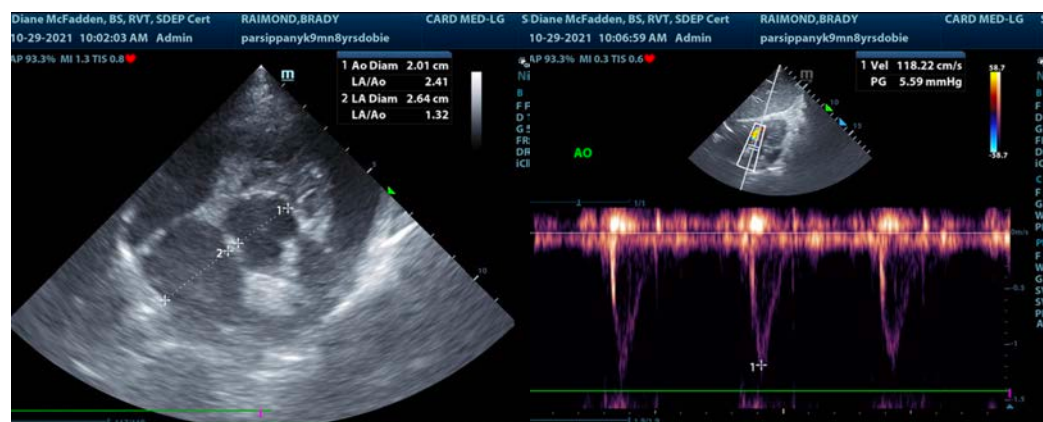
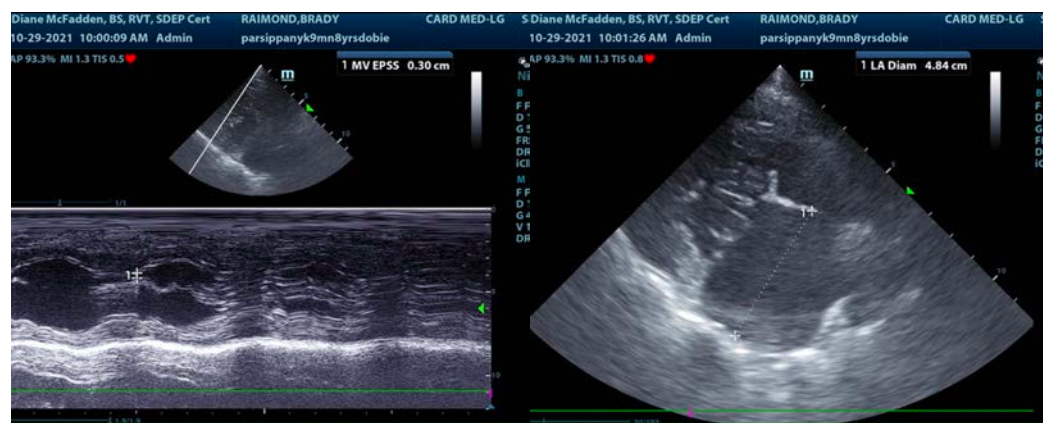
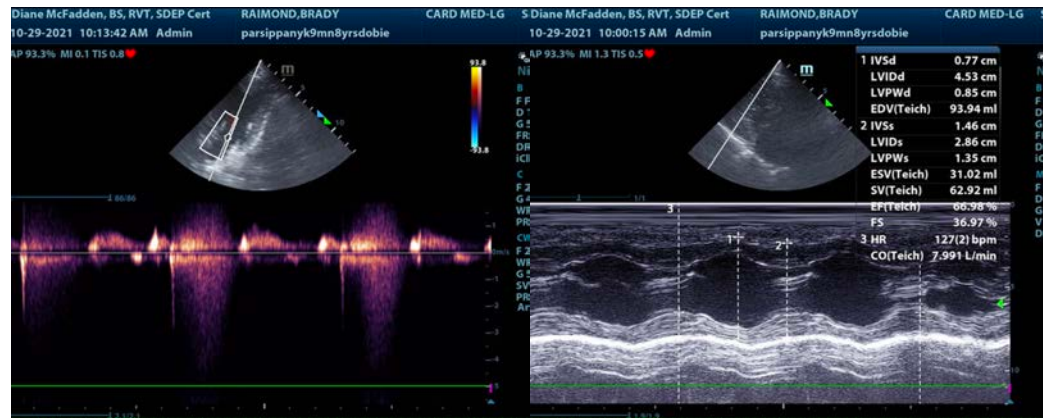
Dr Dulude

INVOICE

26746

DATE

10/29/21



The information and recommendations provided are based on the images presented by the referring veterinarian. No evaluation can be communicated regarding pathology that was not visible in the image/video clips provided.

Thank you for this referral. If the clinical or image interpretation does not parallel your findings or if I can be of any further assistance please contact me.

Eric Lindquist, DMV, DABVP, Cert. IVUSS, CEO of SonoPath.com
info@SonoPath.com