



PATIENT

Sophie Weimer-Kopf

SPECIES

Canine

BREED

Min. Schnauzer

SEX

Spayed Female

AGE

8 Years

WEIGHT

18.7

INTERPRETED BY

Eric Lindquist, DMV
DABVP, Cert. IVUSS

IMAGING PERFORMED BY

Emily Kirk

HOSPITAL NAME

Shiloh AH

REFERRING VET

Shana Silverstein

INVOICE

17961

DATE

10/28/22

PRESENTING CLINICAL SIGNS

History: Patient presented today for wellness exam. Splenomegaly was identified on abdominal palpation.

Abnormal PE/Chem/CBC/UA Results: Lab work completed in April 2022 unremarkable.

ULTRASONOGRAPHIC EXAMINATION OF THE ABDOMEN

Urinary System

The **urinary bladder** and visible pelvic urethra were unremarkable for the level of repletion presented. The urine, however, did present some mildly echogenic debris consistent with mucous, exfoliated cells from renal or bladder origin, and/or blood clots as these echogenic changes can all present similarly. This is often related to urinary tract infection but may represent simple evidence of exfoliated debris or sterile inflammation. Cystocentesis, urinalysis, +/- culture would be recommended to rule out and define any UTI.

The **kidneys** revealed normal size and structure, corticomedullary definition and ratio for this age. The cortices presented largely uniform texture with normal echogenic relationship to liver and spleen. Medullary structure differed distinctly from the cortex and no evidence of pelvic dilation was present. The capsules were acceptably uniform without significant irregularities. The left kidney measured 5.43 cm. The right kidney measured 5.84 cm.

Adrenal Glands

Both **adrenal glands** were visualized and recognized as having normal shape, size, position and echogenicity for this breed. The phrenic vasculature, glandular echogenicity and detail were unremarkable. Capsule, cortex, and medullary definition were normal for this age patient. The left adrenal gland measured 0.5 cm. The right adrenal gland measured 0.8 cm at the cranial pole and 0.6 cm at the caudal pole.

Spleen

The **spleen** revealed mild uniform enlargement with subtle heterogenous parenchymal changes. Splenic fold was noted. No evidence of masses noted.

Liver

The **liver** images submitted revealed subjectively normal liver size, contour, and structure. Parenchymal echogenicity was naturally coarse and hypoechoic to the spleen. Vascular and biliary tracts were of normal volume with no evidence of congestion. The gallbladder presented acceptably thin walls with primarily anechoic content. The cystic and common bile ducts were normal. No pathological hepatic lymphadenopathy was evident. No overt structural evidence of inflammatory, infiltrative or regenerative pathology was evident.

Gastrointestinal

There was some residual chyme and gas was noted in the **stomach**, yet not pathological. This is consistent with end post prandial presentation. Transit of chyme into the small intestine was normal. Curvilinear patterns were maintained throughout the GI tract. No evidence of pathology. Small and large intestine demonstrated normal luminal chyme and stool consistency respectively. No obstructive or overt infiltrative disease was noted. No associated abnormal lymphatic activity was noted.



PATIENT

Sophie Weimer-Kopf

SPECIES

Canine

BREED

Min. Schnauzer

SEX

Spayed Female

AGE

8 Years

WEIGHT

18.7

INTERPRETED BY

Eric Lindquist, DMV
DABVP, Cert. IVUSS

IMAGING PERFORMED BY

Emily Kirk

HOSPITAL NAME

Shiloh AH

REFERRING VET

Shana Silverstein

INVOICE

17961

DATE

10/28/22

Pancreas

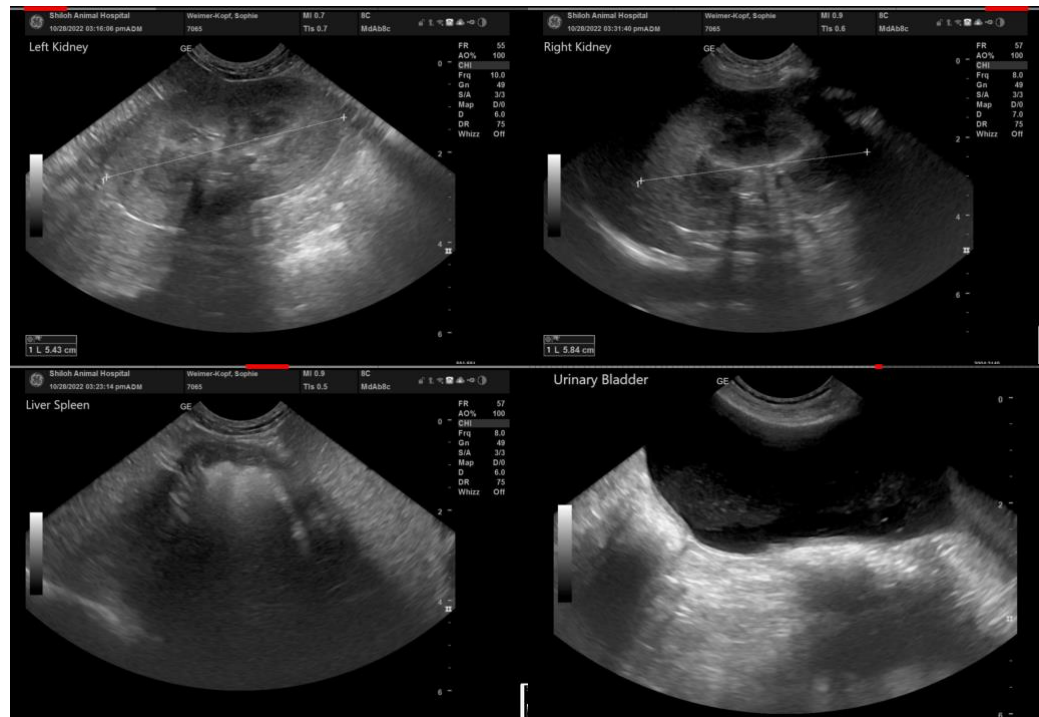
The base and limbs of the **pancreas** were observed to be largely isoechoic to surrounding omental fat. Pancreatic duct and capsular contour were acceptably normal and parenchyma respected normal curvilinear patterns. No overt evidence of active inflammatory or neoplastic disease was noted.

ULTRASONOGRAPHIC FINDINGS

- Structurally unremarkable abdomen
- Folded spleen
- Minor urinary bladder debris
- Partially full stomach
- Minor age-related abdominal changes

INTERPRETATION OF THE FINDINGS & FURTHER RECOMMENDATIONS

If urinalysis is not already performed, I recommend assessment for potential inflammatory sediment. No evidence of pathology.





PATIENT

Sophie Weimer-Kopf

SPECIES

Canine

BREED

Min. Schnauzer

SEX

Spayed Female

AGE

8 Years

WEIGHT

18.7

INTERPRETED BY

Eric Lindquist, DMV
DABVP, Cert. IVUSS

IMAGING PERFORMED BY

Emily Kirk

HOSPITAL NAME

Shiloh AH

REFERRING VET

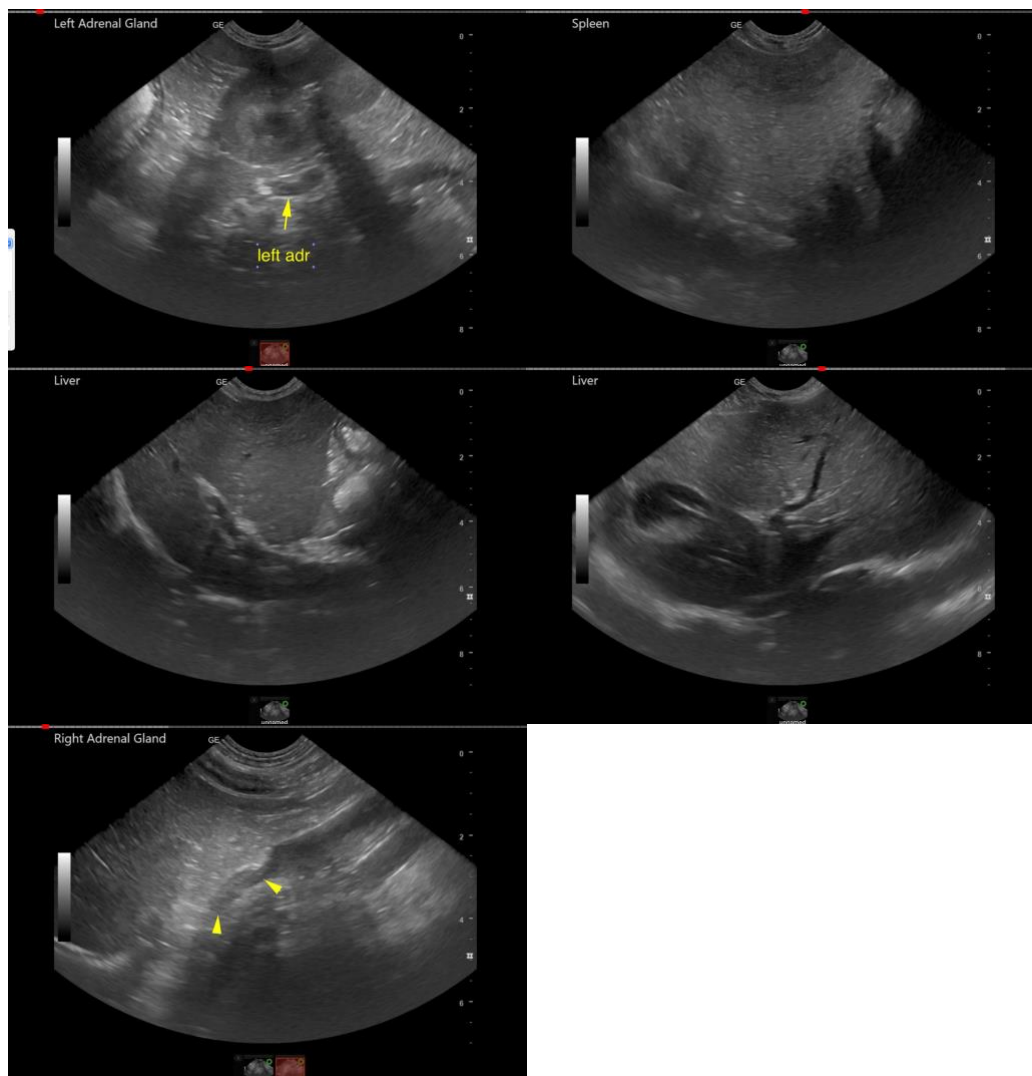
Shana Silverstein

INVOICE

17961

DATE

10/28/22



The information and recommendations provided are based on the images presented by the referring veterinarian. No evaluation can be communicated regarding pathology that was not visible in the image/video clips provided.

Thank you for this referral. If the clinical or image interpretation does not parallel your findings or if I can be of any further assistance please contact me.

Eric Lindquist, DMV, DABVP, Cert. IVUSS, CEO of SonoPath.com
info@SonoPath.com