



## PATIENT

Huckleberry TLVC

## SPECIES

Feline

## BREED

DSH

## SEX

Neutered Male

## AGE

5 Years

## WEIGHT

8.8 Pounds

## PRESENTING CLINICAL SIGNS

History: History of FeLV +. NO PE abnormalities noted. Bloodwork pending for annual evaluation

Abnormal PE/Chem/CBC/UA Results: On echo, noticed soft tissue opacity cranial to heart. Radiographs performed show cranial mediastinal mass.

## ULTRASONOGRAPHIC EXAMINATION OF THE HEART & ABDOMEN

FELINE CARDIAC PARAMETERS	BODY WEIGHT (kg)	HR (BPM)	IVSd (cm)	LVIDd (cm)	LVWd (cm)	FS (%)	EF (%)
NORMAL PARAMETER	-----	150-240	0.3-0.6	1.0-2.1	0.25-0.6	35-67	80-100
PATIENT	--	130	0.43	1.22	0.45	30	--
FELINE CARDIAC PARAMETERS	LA/AO (Boon)	LA/AO HEART BASE (Sisson)	LA 2D 4-chamber long axis AS to FW (Sisson) (cm)	LVOT VEL. (m/s)	RVOT VEL. (m/s)	IVRT (m/)	
NORMAL PARAMETER	<1.5	0.88-1.79	0.7-1.7	<1.6	<1.3	40-60	
PATIENT	1.0	1.3	--	1.00	.60	NM	
Adapted from June Boon, Veterinary Echocardiography, 1998 Sisson D et al. JVIM 1991; 5: 232, Jacobs et al. Am J Vet Res 1985; 46:1705							

## INTERPRETED BY

Eric Lindquist, DMV  
DABVP, Cert. IVUSS

## IMAGING PERFORMED BY

Adrienne Waffle

## HOSPITAL NAME

Torch Lake VC

## REFERRING VET

Adrienne Waffle

## INVOICE

17935

## DATE

10/28/22

## Cardiac Presentation

The echocardiogram in this patient demonstrated normal **left atrial** size based on 3 separate LA measurements. The cranial and caudal **mitral** valve leaflets presented normal linear structure and kinetics. The **left ventricle** presented normal thicknesses with linear contour and was not dilated nor restricted. The **myocardium** presented normal echogenicity without subjective evidence of significant fibrotic or ischemic disease. **Contractility** of the ventricular walls was adequate and in normal range for this patient evidenced by the fractional shortening measurement and subjective evaluation of the different regions and angles of the myocardium. The **left ventricular outflow** tract demonstrated normal laminar flow and subjective structural integrity. The **right atrium** and auricle revealed normal size, structure and content. No evidence of masses was noted or chamber overload. **Tricuspid** valvular assessment demonstrated adequate linear morphology and kinetics. The **right ventricle** was of normal size (1/3 diameter of LV), chordae structure, myocardial echogenicity and thickness. **Pulmonic** tract assessment revealed normal valve structure, laminar flow, and diameter (approx. 1:1 pa/ao ratio). No visible **pericardial** or free pleura fluid was noted or extra cardiac pathology in the visible planes. The cranial **mediastinum and pericardial regions** were free of masses in the visible window.

## Urinary System

The **urinary bladder**, trigone, and pelvic urethra presented normal thicknesses and normal tone. The ureters were not visible which is normal. No uroliths or sediment were visualized, and anechoic urine was present. No evidence of inflammatory or neoplastic changes were noted. Ureteral papillae were normal.



**PATIENT**

Huckleberry TLVC

The **kidneys** revealed normal size and structure, corticomedullary definition and ratio for this age. The cortices presented largely uniform texture with normal echogenic relationship to liver and spleen. Medullary structure differed distinctly from the cortex and no evidence of pelvic dilation was present. The capsules were acceptably uniform without significant irregularities. The left kidney measured 3.0 cm. The right kidney measured 3.0 cm.

**SPECIES**

Feline

**Adrenal Glands**

The regions of the **adrenal glands** revealed no evident pathology.

**BREED**

DSH

**Spleen**

The **spleen** was mildly enlarged with uniform, but subtly micronodular parenchyma, and undulating capsular contour. This is consistent with reactive spleen owing to immune stimulus or early infiltrative disease such as mast cell disease or lymphoma. 25-gauge FNA would be ideal if weight loss is an issue to differentiate early round cell neoplasia versus splenitis or reactive spleen all of which can present in this manner. Cranial folding of the spleen was noted.

**SEX**

Neutered Male

**AGE**

5 Years

**Liver**

The **liver** images submitted revealed subjectively normal liver size, contour, and structure. Parenchymal echogenicity was naturally coarse and hypoechoic to the spleen. Vascular and biliary tracts were of normal volume with no evidence of congestion. The gallbladder presented acceptably thin walls with primarily anechoic content. The cystic and common bile ducts were normal. No pathological hepatic lymphadenopathy was evident. No overt structural evidence of inflammatory, infiltrative or regenerative pathology was evident.

**WEIGHT**

8.8 Pounds

**Gastrointestinal**

Examination of the **gastrointestinal tract** revealed a stomach and intestine free of stasis, of normal wall thickness, acceptable curvilinear mural detail, and peristaltic activity. Small and large intestine demonstrated normal luminal chyme and stool consistency respectively. No obstructive or overt infiltrative disease was noted. No associated abnormal lymphatic activity was noted.

**INTERPRETED BY**

Eric Lindquist, DMV  
DABVP, Cert. IVUSS

**Pancreas**

The base and limbs of the **pancreas** were observed to be largely isoechoic to surrounding omental fat. Pancreatic duct and capsular contour were acceptably normal and parenchyma respected normal curvilinear patterns. No overt evidence of active inflammatory or neoplastic disease was noted.

**IMAGING PERFORMED BY**

Adrienne Waffle

**Other**

A **cranial mediastinal mass** was noted, measuring approximately 5.0 cm, impinging upon the right heart yet not deriving from it. Pleural effusion was noted through the diaphragm, as well as comet tail lung pattern.

**HOSPITAL NAME**

Torch Lake VC

**REFERRING VET**

Adrienne Waffle

**INVOICE**

17935

**Free Abdomen**

The **mesenteric lymph nodes** were enlarged, rounded, hypoechoic and irregular, a grouping of which measured approximately 3.0 cm. Slight free fluid was noted in the abdomen, likely owing to lymphatic congestion.

**DATE**

10/28/22

**ULTRASONOGRAPHIC FINDINGS**



**PATIENT**

Huckleberry TLVC

- Normal echocardiogram
- Mesenteric lymphadenopathy
- Minor splenic enlargement
- Cranial mediastinal mass
- Pleural effusion

**SPECIES**

Feline

**INTERPRETATION OF THE FINDINGS & FURTHER RECOMMENDATIONS**

**BREED**

DSH

Multicentric round cell neoplasia is suspected. FNA of the cranial mediastinal mass, mesenteric lymph nodes and spleen are all indicated and/or pleurocentesis and cytospin to assess for exfoliating neoplasia, such as lymphomatosis or similar. Prognosis is guarded to poor depending upon cytology results and potential response to chemotherapy.

**SEX**

Neutered Male

**AGE**

5 Years

**WEIGHT**

8.8 Pounds

**INTERPRETED BY**

Eric Lindquist, DMV  
DABVP, Cert. IVUSS

**IMAGING PERFORMED BY**

Adrienne Waffle

**HOSPITAL NAME**

Torch Lake VC

**REFERRING VET**

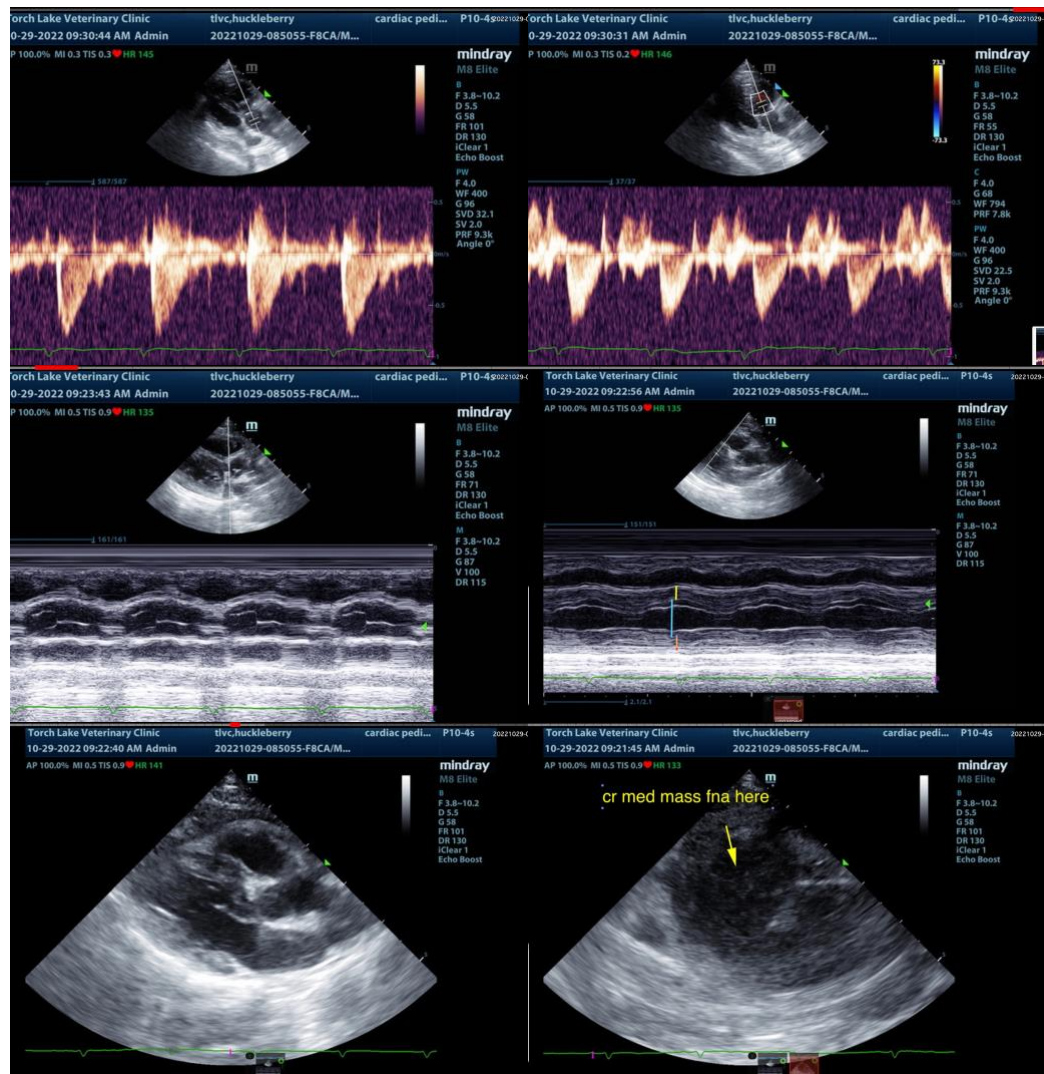
Adrienne Waffle

**INVOICE**

17935

**DATE**

10/28/22





## PATIENT

Huckleberry TLVC

## SPECIES

Feline

## BREED

DSH

## SEX

Neutered Male

## AGE

5 Years

## WEIGHT

8.8 Pounds

## INTERPRETED BY

Eric Lindquist, DMV  
DABVP, Cert. IVUSS

## IMAGING PERFORMED BY

Adrienne Waffle

## HOSPITAL NAME

Torch Lake VC

## REFERRING VET

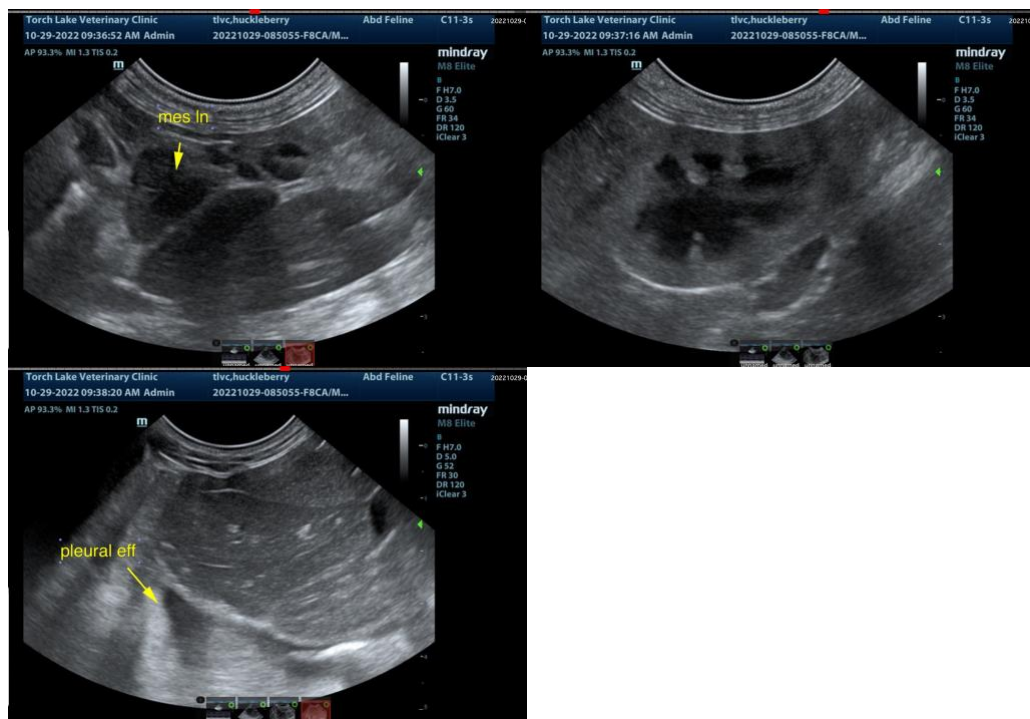
Adrienne Waffle

## INVOICE

17935

## DATE

10/28/22



The information and recommendations provided are based on the images presented by the referring veterinarian. No evaluation can be communicated regarding pathology that was not visible in the image/video clips provided.

Thank you for this referral. If the clinical or image interpretation does not parallel your findings or if I can be of any further assistance please contact me.

**Eric Lindquist**, DMV, DABVP, Cert. IVUSS, CEO of SonoPath.com  
info@SonoPath.com