



**PATIENT PRESENTING CLINICAL SIGNS**

Riley Corsi Recheck echo from 3/17/2021 (report attached)

**SPECIES ULTRASONOGRAPHIC EXAMINATION OF THE HEART**

Canine

**BREED**

Maltese X

**SEX**

Neutered Male

**AGE**

16 Years

**WEIGHT**

16.2 Pounds

CANINE CARDIAC PARAMETERS	MR VMAX (m/s)	TR VMAX (m/s)	LA/AO (Boon method)	LA/AO (Heart Base; Swe)	FS (%)	EF (%)	EPSS (cm)
NORMAL PARAMETER	4.5-5.5	<2.7	1.3	<1.6	28-40	40-100	<0.6
PATIENT	6.0	3.2	1.2	1.51	43		0.2
CANINE CARDIAC PARAMETERS	HR (BPM)	AV VMAX (m/s)	PV MAX (m/s)	BODY WEIGHT (kg)	LA 2D short axis Base view (cm)	LVIDd Avg; 2D and m-mode short axis (cm)	LVIDs Avg; 2D and m-mode short axis (cm)
NORMAL PARAMETER	50-100	0.7-1.7	0.7-1.6				
PATIENT		1.10	0.7		3.31	3.1	

**Cardiac Presentation**

The cardiac presentation revealed minor persistent volume overload of the left atrium. The left ventricle was normal in contractility and internal diameter. Myocardium appeared to be intact without significant remodeling. Aortic insufficiency noted at 4.5 m/sec. Tricuspid insufficiency noted at 3.2 m/sec, consistent with early pulmonary hypertension. However, it appears to be stable. The anterior mitral valve leaflet appeared to have mild prolapse. Complete filling of the left atrium was noted on color flow assessment of the mitral valve. No pericardial or pleural effusion noted. The left and right ventricular outflow tracts were unremarkable except for the aortic insufficiency.

**INTERPRETED BY**

Eric Lindquist, DMV DABVP, Cert. IVUSS

**IMAGING PERFORMED BY**

Shari Reffi, CVT

**HOSPITAL NAME**

AH Roxbury

**ULTRASONOGRAPHIC FINDINGS**

- Stable valvular disease presentation with relatively contained left atrium, minor residual enlargement

**INTERPRETATION OF THE FINDINGS & FURTHER RECOMMENDATIONS**

Recommend continuation of the current protocol and recheck echo in 6 months.

**REFERRING VET**

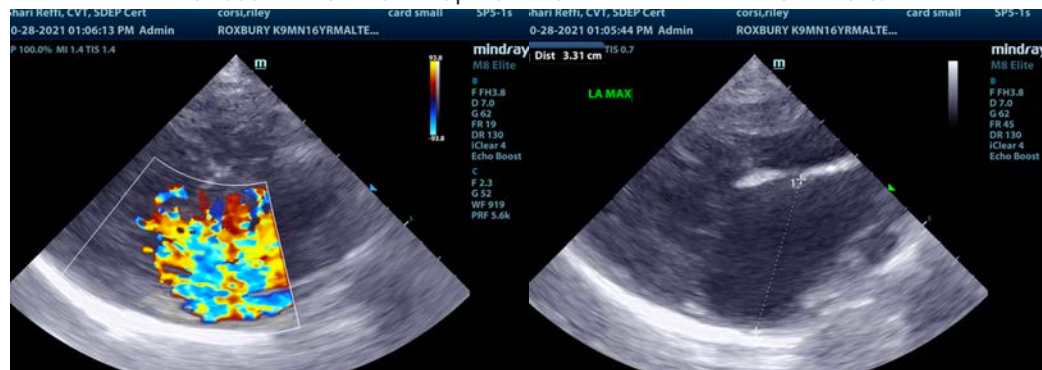
Dr. Elia

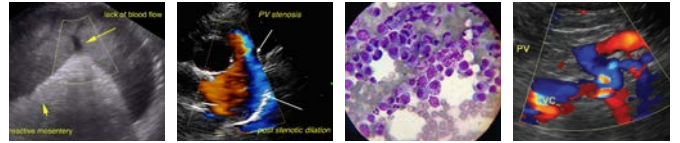
**INVOICE**

26712

**DATE**

10/28/21





**PATIENT**

Riley Corsi

**SPECIES**

Canine

**BREED**

Maltese X

**SEX**

Neutered Male

**AGE**

16 Years

**WEIGHT**

16.2 Pounds

**INTERPRETED BY**

Eric Lindquist, DMV  
DABVP, Cert. IVUSS

**IMAGING PERFORMED BY**

Shari Reffi, CVT

**HOSPITAL NAME**

AH Roxbury

**REFERRING VET**

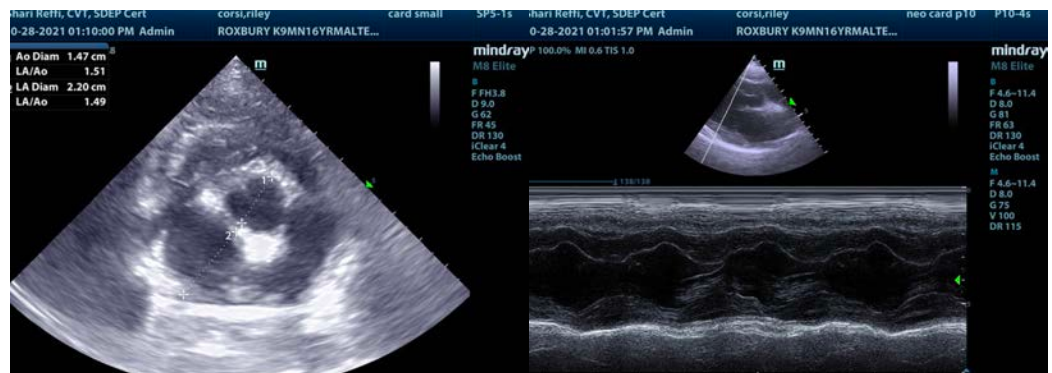
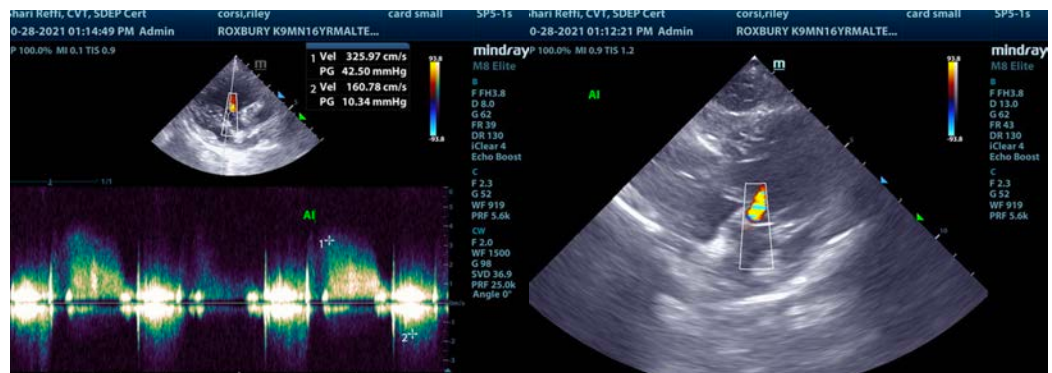
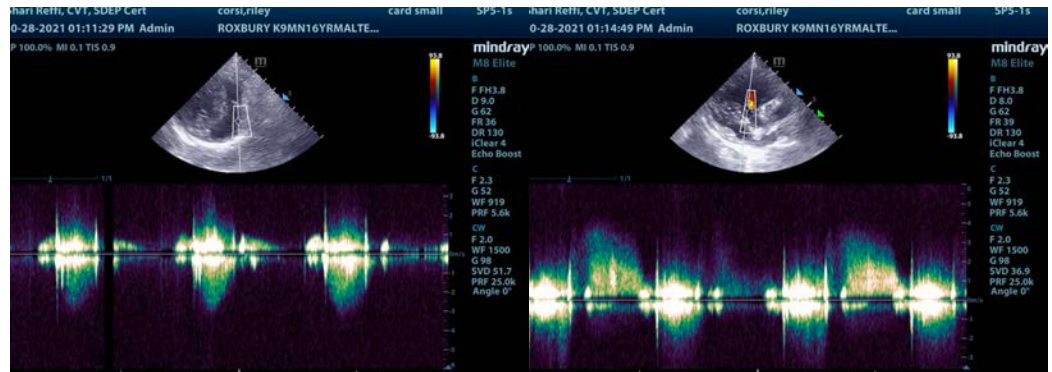
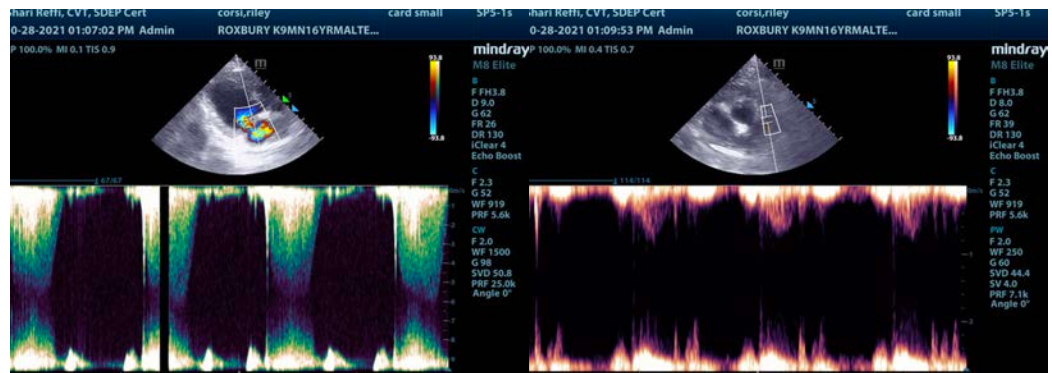
Dr. Elia

**INVOICE**

26712

**DATE**

10/28/21





**PATIENT**

Riley Corsi

The information and recommendations provided are based on the images presented by the referring veterinarian. No evaluation can be communicated regarding pathology that was not visible in the image/video clips provided.

**SPECIES**

Canine

Thank you for this referral. If the clinical or image interpretation does not parallel your findings or if I can be of any further assistance please contact me.

**BREED**

Maltese X

**Eric Lindquist**, DMV, DABVP, Cert. IVUSS, CEO of SonoPath.com  
[info@SonoPath.com](mailto:info@SonoPath.com)

**SEX**

Neutered Male

**AGE**

16 Years

**WEIGHT**

16.2 Pounds

**INTERPRETED BY**

Eric Lindquist, DMV  
DABVP, Cert. IVUSS

**IMAGING  
PERFORMED BY**

Shari Reffi, CVT

**HOSPITAL NAME**

AH Roxbury

**REFERRING VET**

Dr. Elia

**INVOICE**

26712

**DATE**

10/28/21