



PATIENT

Max De La Gala

SPECIES

Canine

BREED

Golden Doodle

SEX

Male

AGE

2 years

WEIGHT

46 lbs

INTERPRETED BY

Eric Lindquist, DMV
DABVP, Cert. IVUSS

IMAGING PERFORMED BY

Mayra Sanchez

HOSPITAL NAME

Sunset AH

REFERRING VET

Dr. Polit

INVOICE

92722

DATE

10/28/21

PRESENTING CLINICAL SIGNS

History: Patient was taken to another DVM on Monday for anorexia for 2 days Diagnosed with pancreatitis and given outpatient treatment Patient presented here yesterday and admitted to hospital for further treatment

CBC = mild anemia, RBC 5.4 (present on CBC on Monday)

Chem = NSF cPL = 226 Digital fecal scan = NPS

ULTRASONOGRAPHIC EXAMINATION OF THE ABDOMEN

Urinary System

The **urinary bladder**, trigone, and pelvic urethra presented normal thicknesses and normal tone. The ureters were not visible which is normal. No uroliths or sediment were visualized and anechoic urine was present. No evidence of inflammatory or neoplastic changes was noted. Ureteral papillae were normal.

The **kidneys** revealed normal size and structure, corticomedullary definition and ratio for this age. The cortices presented largely uniform texture with normal echogenic relationship to liver and spleen. Medullary structure differed distinctly from the cortex and no evidence of pelvic dilation was present. The capsules were acceptably uniform without significant irregularities. The left kidney measured 5.0 cm. The right kidney measured 6.0 cm with an anechoic cyst at the dorsal cortex of the right kidney.

Adrenal Glands

Both **adrenal glands** were visualized and recognized as having normal shape, size, position and echogenicity for this breed. The phrenic vasculature, glandular echogenicity and detail were unremarkable. Capsule, cortex, and medullary definition were normal for this age patient. The left adrenal gland measured 0.5 cm. The right adrenal gland measured 0.6 cm at the cranial pole and 0.4 cm at the caudal pole.

Spleen

The **spleen** presented a smooth homogeneous parenchyma hyperechoic to liver and renal cortical parenchyma. The capsule was smooth without noticeable expansion or deviation from within the spleen or adjacent pathology. The splenic vasculature demonstrated normal volume without signs of congestion or thrombosis. No sonographic evidence of acute or chronic inflammatory, neoplastic, or infarctual changes was noted.

Liver

The **liver** images submitted revealed subjectively normal liver size, contour, and structure. Parenchymal echogenicity was naturally coarse and hypoechoic to the spleen. Vascular and biliary tracts were of normal volume with no evidence of congestion. The gallbladder presented acceptably thin walls with primarily anechoic content. The cystic and common bile ducts were normal. No pathological hepatic lymphadenopathy was evident. No overt structural evidence of inflammatory, infiltrative or regenerative pathology was evident.



PATIENT

Gastrointestinal

Max De La Gala

The **stomach** was empty. The curvilinear patterns were respected. The intestines and colon were normal.

SPECIES

Canine

Pancreas

BREED

Golden Doodle

The base and limbs of the **pancreas** were observed to be largely isoechoic to surrounding omental fat. Pancreatic duct and capsular contour were acceptably normal and parenchyma respected normal curvilinear patterns. No overt evidence of active inflammatory or neoplastic disease was noted.

SEX

Male

ULTRASONOGRAPHIC FINDINGS

Structurally unremarkable abdomen.

AGE

2 years

INTERPRETATION OF THE FINDINGS & FURTHER RECOMMENDATIONS

Dietary indiscretion, food intolerance/indiscretion, structurally insignificant inflammatory bowel or occult parasitism and occult Addison's are all potentials. I cannot rule out minor low-grade pancreatic inflammation.

WEIGHT

46 lbs

INTERPRETED BY

Eric Lindquist, DMV
DABVP, Cert. IVUSS

IMAGING PERFORMED BY

Mayra Sanchez

HOSPITAL NAME

Sunset AH

REFERRING VET

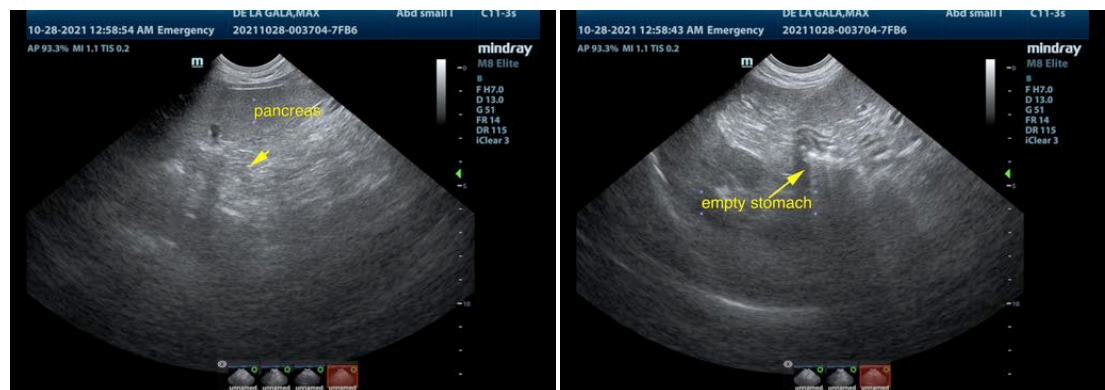
Dr. Polit

INVOICE

92722

DATE

10/28/21





PATIENT

Max De La Gala

SPECIES

Canine

BREED

Golden Doodle

SEX

Male

AGE

2 years

WEIGHT

46 lbs

INTERPRETED BY

Eric Lindquist, DMV
DABVP, Cert. IVUSS

IMAGING PERFORMED BY

Mayra Sanchez

HOSPITAL NAME

Sunset AH

REFERRING VET

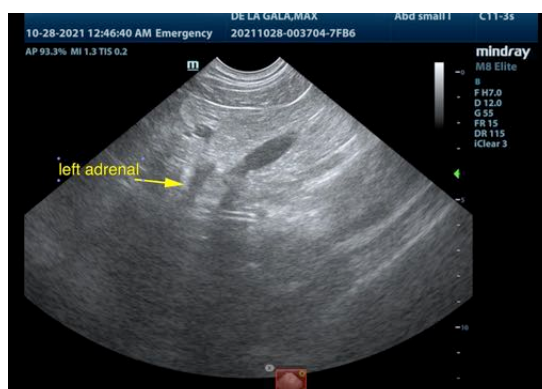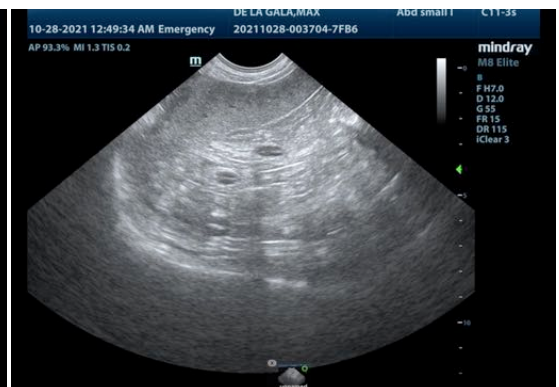
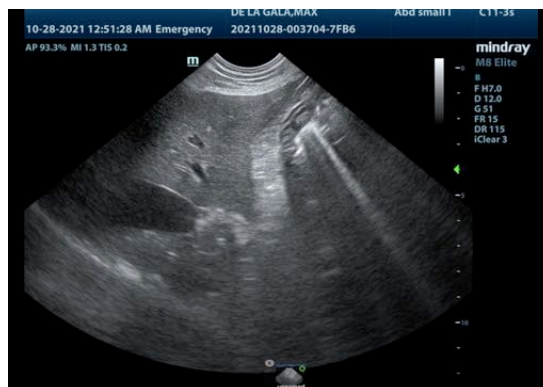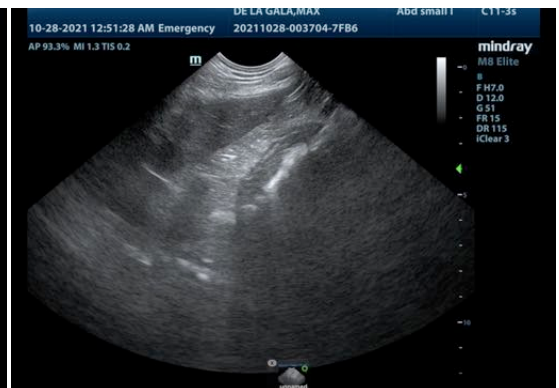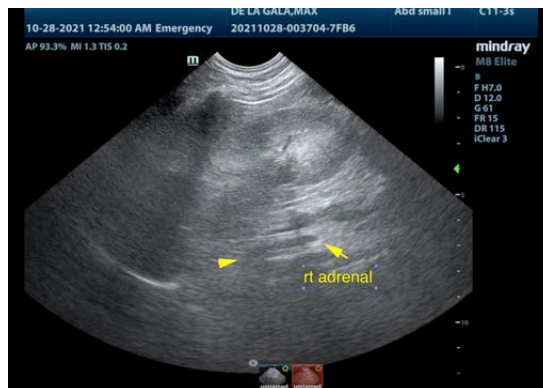
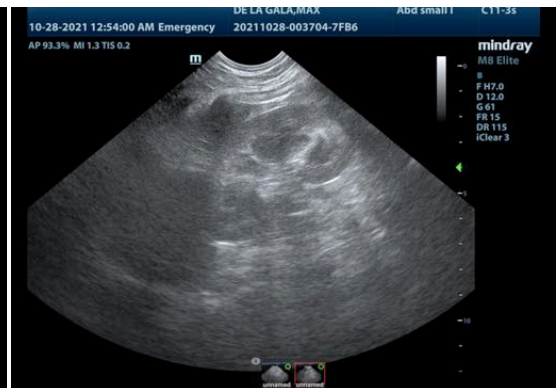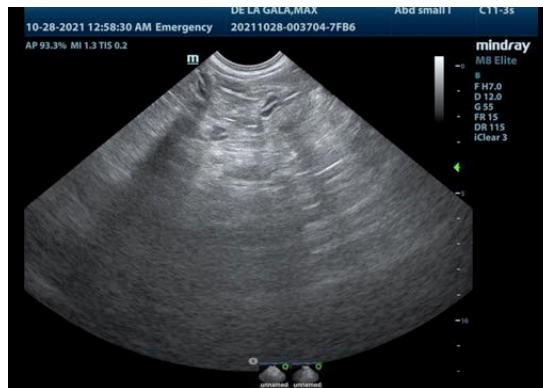Dr. Polit

INVOICE

92722

DATE

10/28/21





PATIENT

Max De La Gala

veterinarian. No evaluation can be communicated regarding pathology that was not visible in the image/video clips provided.

Thank you for this referral. If the clinical or image interpretation does not parallel your findings or if I can be of any further assistance please contact me.

SPECIES

Canine

Eric Lindquist, DMV, DABVP, Cert. IVUSS, CEO of SonoPath.com
info@SonoPath.com

BREED

Golden Doodle

SEX

Male

AGE

2 years

WEIGHT

46 lbs

INTERPRETED BY

Eric Lindquist, DMV
DABVP, Cert. IVUSS

**IMAGING
PERFORMED BY**

Mayra Sanchez

HOSPITAL NAME

Sunset AH

REFERRING VET

Dr. Polit

INVOICE

92722

DATE

10/28/21