



PATIENT

Symbah Moore

SPECIES

Feline

BREED

Domestic Shorthair

SEX

Neutered male

AGE

7 years

WEIGHT

9.1 kg

INTERPRETED BY

Eric Lindquist, DMV
DABVP, Cert. IVUSS

IMAGING PERFORMED BY

Dr. Sra

HOSPITAL NAME

Bridgewater VH and
Wellness Centre

REFERRING VET

Dr. Sra

INVOICE

42157

DATE

10/27/22

PRESENTING CLINICAL SIGNS

History: Patient has glaucoma, owner thinks it is controlled with medication. Has eye enucleation scheduled, but owner does not want to follow through, despite recommendation from eye specialist. Owner concerned regarding possible mass behind the eye

ULTRASONOGRAPHIC EXAMINATION

6 still images and 13 videos were submitted in WMV format

Videos of an eye were evaluated. The anterior chamber was unremarkable. The lens was opacified and irregular. This is consistent with cataracts. The ciliary body was thickened and irregular. This is suggestive for chronic inflammation and remodeling. The posterior chamber was largely anechoic with minor striating debris and seagull sign. This is consistent with detached retina. The globe itself was uniform with curvilinear patterns. The optic nerve and retrobulbar space was unremarkable.

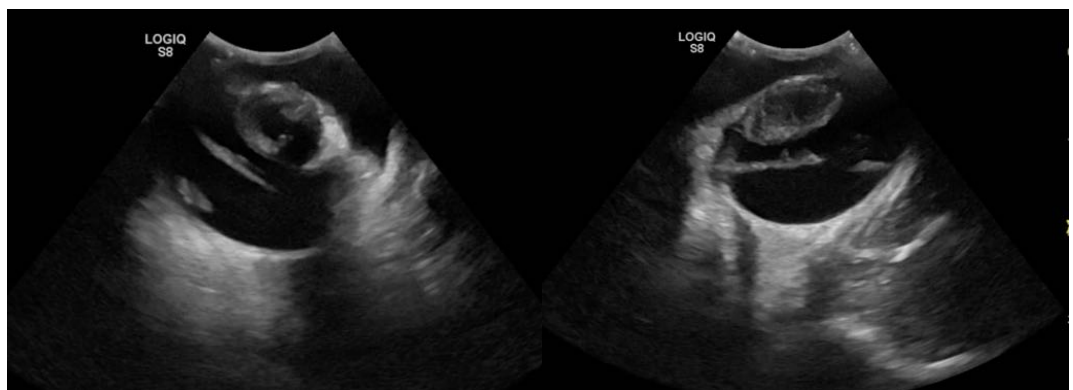
ULTRASONOGRAPHIC FINDINGS

Opacified lens, consistent with cataracts and chronic ciliary body thickening and detached retina.

INTERPRETATION OF THE FINDINGS & FURTHER RECOMMENDATIONS

*****In the future please submit in DICOM format*****

There is no evidence of neoplasia.



The information and recommendations provided are based on the images presented by the referring veterinarian/sonographer. No evaluation can be communicated regarding pathology that was not visible in the image/video clips provided.

Thank you for this referral. If the clinical or image interpretation does not parallel your findings or if I can be of any further assistance please contact me.

Eric Lindquist, DMV, DABVP, Cert. IVUSS, CEO of SonoPath.com
info@SonoPath.com