

**DATE**

10/27/22

PRESENTING CLINICAL SIGNS

Labwork shows mild liver and kidney changes but not enough to explain weight loss. Vomiting, diarrhea, dehydration, weight loss.

Current Medications: None listed.

PATIENT

Rose Kidder

Lab Results: See attached.

Date of Previous IntraPet Ultrasound: No previous.

Sedation: Not required to complete full diagnostic ultrasound.

Stat Report: Not requested.

SPECIES

Feline

Imaging Performed By: Rachel Brilhart, RDMS.

BREED

Domestic Shorthair

ULTRASONOGRAPHIC EXAMINATION OF THE ABDOMEN**Urinary System**

The **urinary bladder**, trigone, and pelvic urethra presented normal thicknesses and normal tone. The ureters were not visible which is normal. No uroliths or sediment were visualized and anechoic urine was present. No evidence of inflammatory or neoplastic changes was noted. Ureteral papillae were normal.

SEX

Spayed female

The left **kidney** revealed severely dystrophic changes with interstitial nephrosis and multi-focal, cortical infarcts and cortical collapse with pelvic and corticomedullary mineralization. The left kidney is subjectively end stage. The right kidney revealed similar changes with pyelectasia, pelvic mineralization, cortical infarcts and interstitial nephrosis. Pelvic mineralization/ calculus/nephrolithiasis measured 1.8 cm in the right renal pelvis. Smaller calculus was noted and measured 0.66 cm. The right kidney measured 3.78 cm. Blood flow to the kidneys was minimal.

AGE

1/18//07

WEIGHT

4.83 lbs

Adrenal Glands

Both **adrenal glands** were visualized and recognized as having normal shape, size, position and echogenicity for this breed. The phrenic vasculature, glandular echogenicity and detail were unremarkable. Capsule, cortex, and medullary definition were normal for this age patient.

INTERPRETED BY

Eric Lindquist, DMV
DABVP, Cert. IVUSS

Spleen

The **spleen** in this patient was uniform, yet volume contracted. Hydration status should be assessed.

HOSPITAL NAME

Bay Country VH

Liver

The **liver** images from right and left intercostal as well as subcostal views revealed subjectively normal liver size, contour, and structure. Some age-related parenchymal remodeling was noted but likely not clinically significant at this time. Vascular and biliary tracts were of normal volume and no evidence of congestion was noted. The gallbladder presented some dependent debris with essentially normal contour. The cystic and common bile ducts were normal. No overt evidence of active inflammatory, infiltrative or regenerative pathology was noted but should be paired with current or past LE elevations regarding any clinical significance to this presentation. The hepatic lymph nodes were unremarkable.

REFERRING VET

Dr. Smith

INVOICE

42190

Gastrointestinal

Examination of the **gastrointestinal tract** revealed a stomach and intestine free of stasis, of normal wall thickness, acceptable curvilinear mural detail, and peristaltic activity. Small and large intestine demonstrated normal luminal chyme and stool consistency respectively. The mesenteric lymph nodes were reactive and measured up to 1.0 x 0.4 cm.

Pancreas

The base and limbs of the **pancreas** were observed to be largely isoechoic to surrounding omental fat. Pancreatic duct and capsular contour were acceptably normal and parenchyma respected normal curvilinear patterns. No overt evidence of active inflammatory or neoplastic disease was noted.

Free Abdomen

Poor abdominal fat content was noted in this patient.

ULTRASONOGRAPHIC FINDINGS

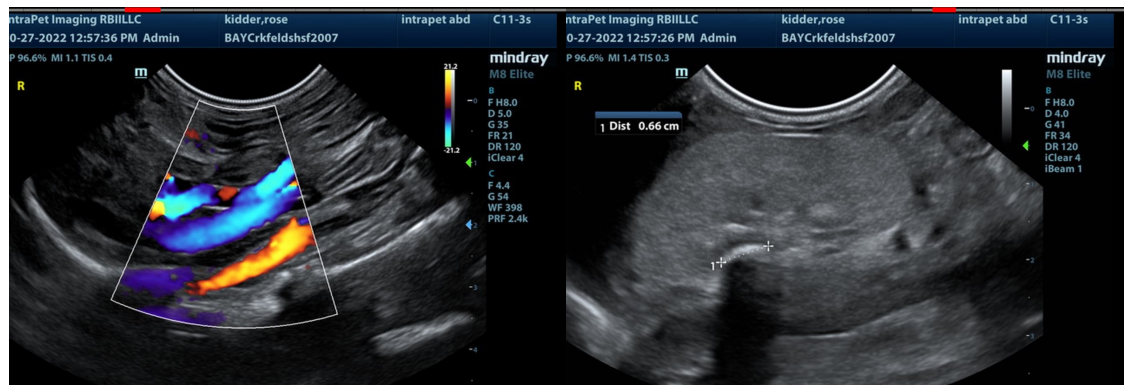
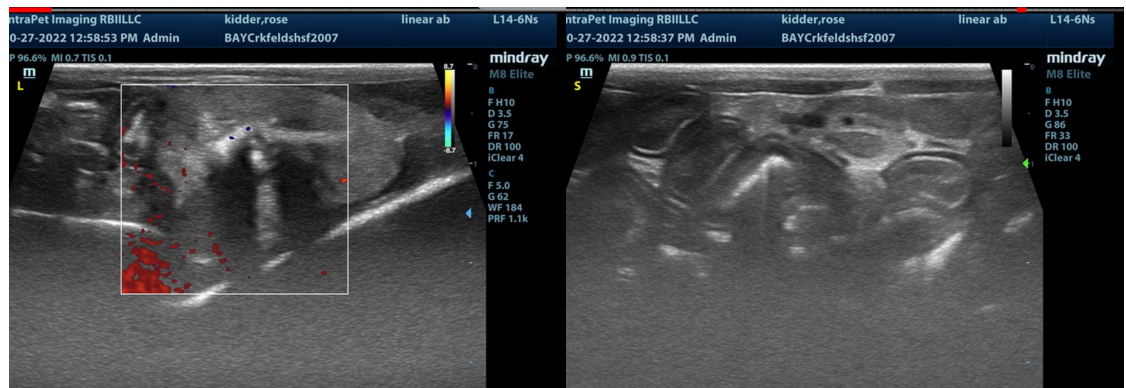
Severe renal dystrophy, interstitial nephrosis pattern.

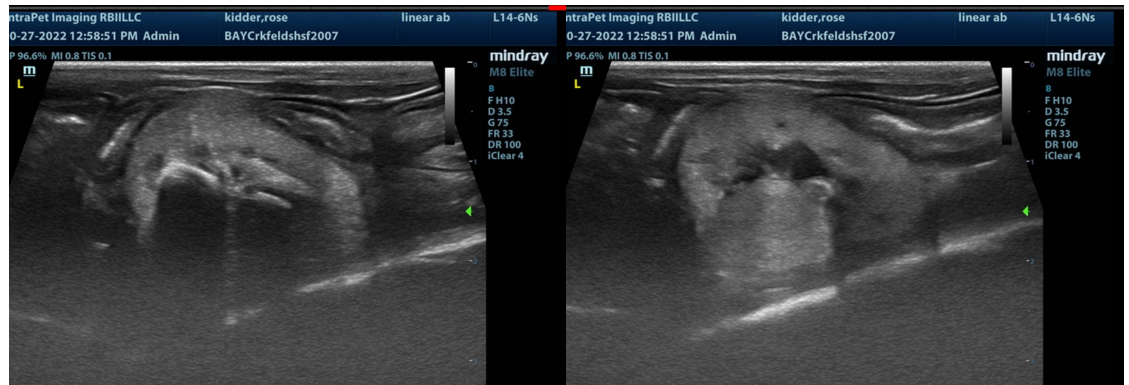
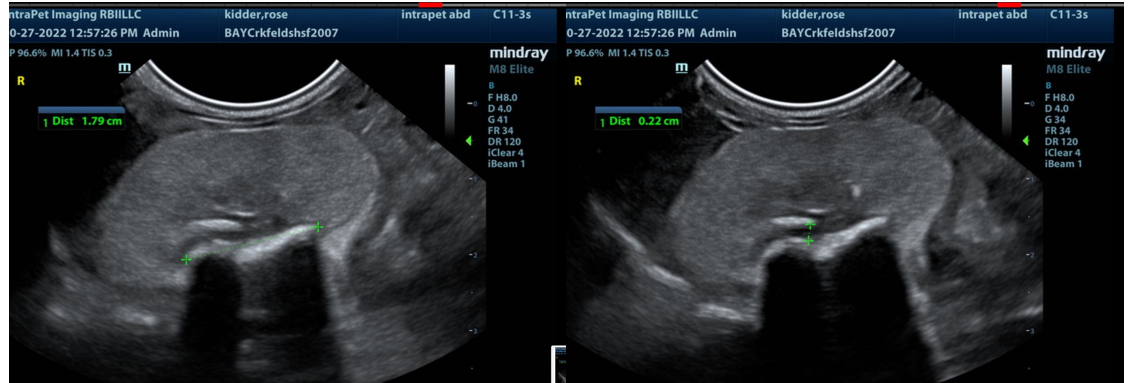
Poor body score.

Otherwise, geriatric abdomen.

INTERPRETATION OF THE FINDINGS & FURTHER RECOMMENDATIONS

The kidneys appear subjectively near end stage. Renal values, blood pressure measurements and urinalysis should be monitored carefully in this patient. Malassimilation of nutrients may be playing a role.





The information and recommendations provided are based on the images presented by the referring veterinarian. No evaluation can be communicated regarding pathology that was not visible in the image/video clips provided.

Thank you for this referral. If the clinical or image interpretation does not parallel your findings or if I can be of any further assistance please contact me.

Eric Lindquist, DMV, DABVP, Cert. IVUSS, CEO of SonoPath.com
 Eric.Lindquist@SonoPath.com