



PATIENT

Bron McFarquhar

PRESENTING CLINICAL SIGNS

re check prev u/s 10/26 showed persistent gastric luminal distention with ingesta Patient has been NPO for 24 hours no vomiting

SPECIES

Canine

LIMITED ULTRASONOGRAPHIC EXAMINATION

The stomach was empty. No evidence of foreign body or obstruction. The retention is resolved. The small intestine and colon were unremarkable.

BREED

Mastiff X

ULTRASONOGRAPHIC FINDINGS

- Resolved gastrointestinal presentation

SEX

Neutered Male

INTERPRETATION OF THE FINDINGS & FURTHER RECOMMENDATIONS

No further therapy recommended, other than assessment of causes of initial insult.

AGE

4 Years

WEIGHT

53.5 Pounds

INTERPRETED BY

Eric Lindquist, DMV

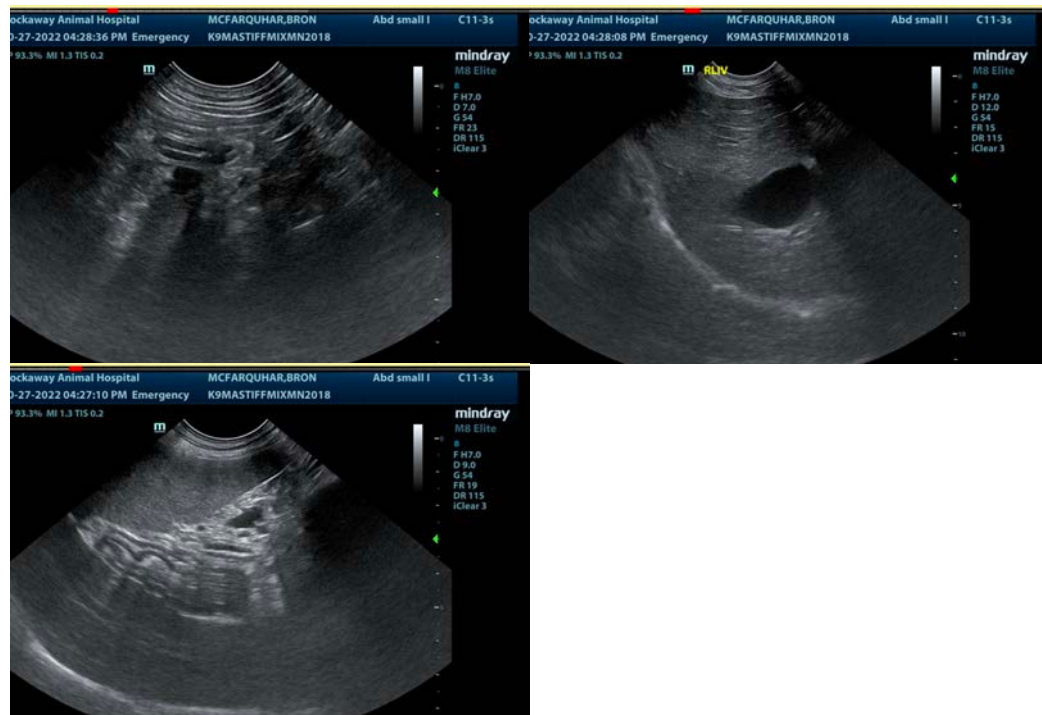
DABVP, Cert. IVUSS

IMAGING PERFORMED BY

Jenn

HOSPITAL NAME

Rockaway AH



REFERRING VET

Dr. Maniar

The information and recommendations provided are based on the images presented by the referring veterinarian/sonographer. No evaluation can be communicated regarding pathology that was not visible in the image/video clips provided.

INVOICE

42395

Thank you for this referral. If the clinical or image interpretation does not parallel your findings or if I can be of any further assistance please contact me.

Eric Lindquist, DMV, DABVP, Cert. IVUSS, CEO of SonoPath.com

info@SonoPath.com

DATE

10/27/22