



PATIENT

Marley Taylor

SPECIES

Canine

BREED

Labrador Mix

SEX

Neutered male

AGE

11 years

WEIGHT

69 lbs

INTERPRETED BY

Eric Lindquist, DMV
DABVP, Cert. IVUSS

IMAGING PERFORMED BY

Anthony Smatt

HOSPITAL NAME

The Pets I Love

REFERRING VET

Dr. Szpicek

INVOICE

92704

DATE

10/27/21

PRESENTING CLINICAL SIGNS

History: patient has had numerous blood work performed and the liver enzymes has been increasing each time, despite being on liver supplements and medications Here for a single organ ultrasound of the liver

Abnormal PE/Chem/CBC/UA Results: May 2021 - ALT - 250/Alp 228 and neutrophils mildly high this was the last blood work

ULTRASONOGRAPHIC EXAMINATION

Liver

The **liver** revealed slight, coarse architecture with isoechoic, expansive 5.7 cm nodule. Other, hypoechoic nodular changes were noted in the liver. Increased portal markings were noted in the liver. Minor gallbladder sand was noted in the cystic duct.

Gastrointestinal

The **stomach** revealed a minor amount of gas and ingesta. The remainder of the intestinal tract was not visualized.

Pancreas

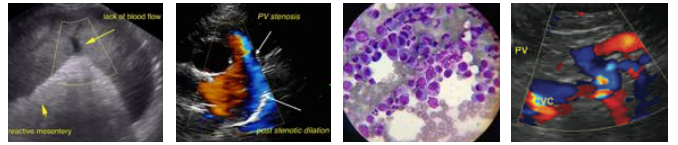
The visible **pancreas** was unremarkable.

ULTRASONOGRAPHIC FINDINGS

Hepatic remodeling with pronounced nodular hyperplasia versus emerging round cell or carcinoma type neoplasia. Gallbladder sand, yet not likely a clinical issue.

INTERPRETATION OF THE FINDINGS & FURTHER RECOMMENDATIONS

Bile acid profile is indicated.



PATIENT

Marley Taylor

SPECIES

Canine

BREED

Labrador Mix

SEX

Neutered male

AGE

11 years

WEIGHT

69 lbs

INTERPRETED BY

Eric Lindquist, DMV
DABVP, Cert. IVUSS

IMAGING PERFORMED BY

Anthony Smatt

HOSPITAL NAME

The Pets I Love

REFERRING VET

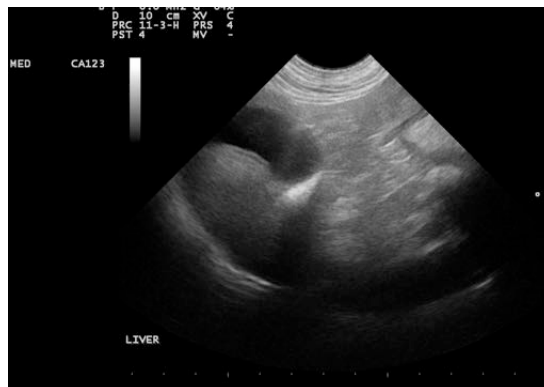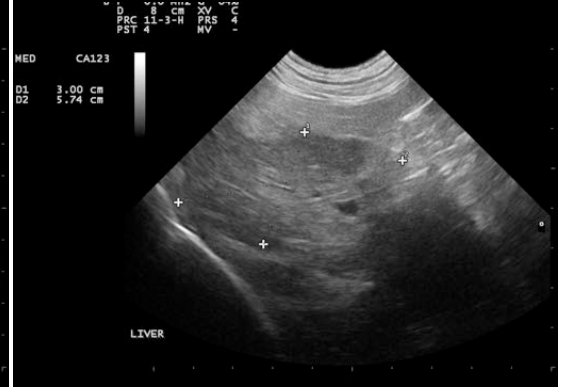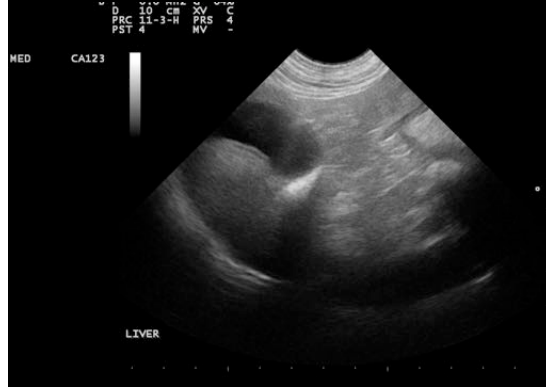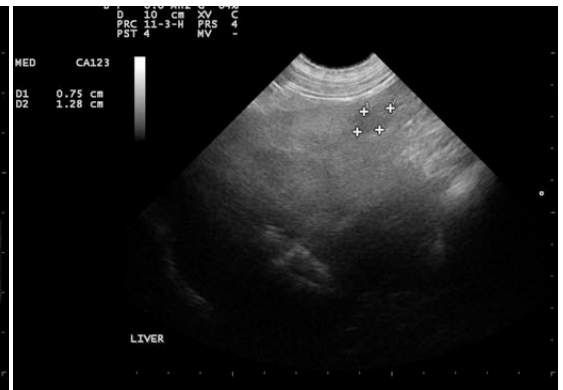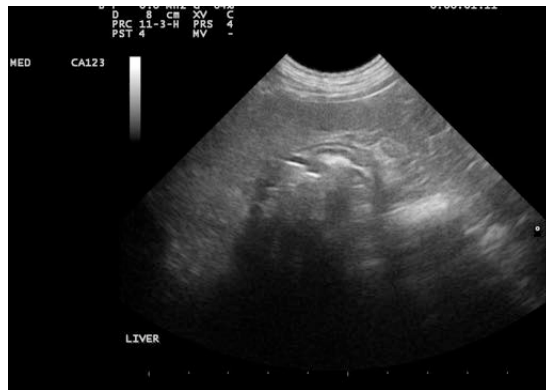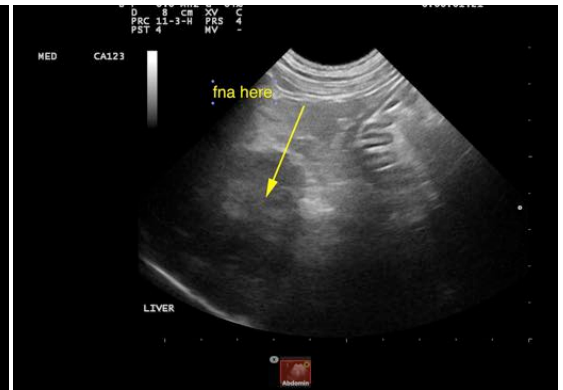
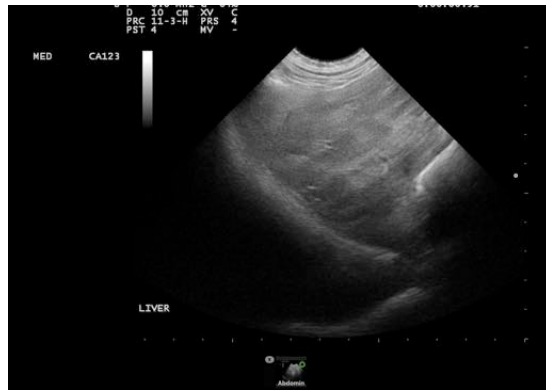Dr. Szpicek

INVOICE

92704

DATE

10/27/21





PATIENT

Marley Taylor

veterinarian. No evaluation can be communicated regarding pathology that was not visible in the image/video clips provided.

Thank you for this referral. If the clinical or image interpretation does not parallel your findings or if I can be of any further assistance please contact me.

SPECIES

Canine

Eric Lindquist, DMV, DABVP, Cert. IVUSS, CEO of SonoPath.com
info@SonoPath.com

BREED

Labrador Mix

SEX

Neutered male

AGE

11 years

WEIGHT

69 lbs

INTERPRETED BY

Eric Lindquist, DMV
DABVP, Cert. IVUSS

**IMAGING
PERFORMED BY**

Anthony Smatt

HOSPITAL NAME

The Pets I Love

REFERRING VET

Dr. Szpicek

INVOICE

92704

DATE

10/27/21