



**PATIENT**

Wallace Shnyer

**PRESENTING CLINICAL SIGNS**

History: III/VI murmur  
BUN 37, Cr 2.8, Amy 1346, PSL 31

**SPECIES**

Feline

**BREED**

Domestic Shorthair

**SEX**

Neutered male

**AGE**

14 years

**WEIGHT**

**INTERPRETED BY**

Eric Lindquist, DMV  
DABVP, Cert. IVUSS

**IMAGING PERFORMED BY**

Jessica Miller, RDMS

**HOSPITAL NAME**

Warren AH

**REFERRING VET**

Dr. Brian

**ULTRASONOGRAPHIC EXAMINATION OF THE HEART**

The echocardiogram in this patient demonstrated normal **left atrial** size based on 3 separate LA measurements. The cranial and caudal **mitral** valve leaflets presented normal linear structure and kinetics. The **left ventricle** presented normal thicknesses with linear contour and was not dilated nor restricted. Mild **myocardial** remodeling was noted in this patient. **Contractility** of the ventricular walls was adequate and in normal range for this patient evidenced by the fractional shortening measurement and subjective evaluation of the different regions and angles of the myocardium. The **left ventricular outflow** tract demonstrated normal laminar flow and subjective structural integrity. The **right atrium** and auricle revealed normal size, structure and content. No evidence of masses was noted or chamber overload. Trivial **tricuspid** insufficiency was noted at 2.5 m/sec. The **right ventricle** was of normal size (1/3 diameter of LV), chordae structure, myocardial echogenicity and thickness. **Pulmonic** tract assessment revealed normal valve structure, laminar flow, and diameter (approx. 1:1 pa/ao ratio). No visible **pericardial** or free pleura fluid was noted or extra cardiac pathology in the visible planes. The cranial **mediastinum and pericardial regions** were free of masses in the visible window. The patient was significantly tachycardic at the time of the sonogram.

FELINE CARDIAC PARAMETERS	BODY WEIGHT (kg)	HR (BPM)	IVSd (cm)	LVIDd (cm)	LVWd (cm)	FS (%)	EF (%)
NORMAL PARAMETER	-----	150-240	0.3-0.6	1.0-2.1	0.25-0.6	35-67	80-100
PATIENT		228	0.54	1.56	0.58	37	71
FELINE CARDIAC PARAMETERS	LA/AO (Boon)	LA/AO HEART BASE (Sisson)	LA 2D 4-chamber long axis AS to FW (Sisson) (cm)	LVOT VEL. (m/s)	RVOT VEL. (m/s)	IVRT (m/)	
NORMAL PARAMETER	<1.5	0.88-1.79	0.7-1.7	<1.6	<1.3	40-60	
PATIENT	1.15	1.16	1.3	1.0	1.12	NM	
Adapted from June Boon, Veterinary Echocardiography, 1998 Sisson D et al. JVIM 1991; 5: 232, Jacobs et al. Am J Vet Res 1985; 46:1705							

**INVOICE**

92635

**DATE**

10/26/21

**ULTRASONOGRAPHIC FINDINGS**

Essentially flow murmur.  
Mild myocardial remodeling, yet not clinically significant.  
Structurally unremarkable heart with tachycardia.



**PATIENT**

Wallace Shnyer

**INTERPRETATION OF THE FINDINGS & FURTHER RECOMMENDATIONS**

Thyroid and blood pressure assessment is recommended. EKG is recommended to assess for pathological tachyarrhythmia.

**SPECIES**

Feline

Benign flow murmurs are common in cats. This may be owing to volume shifts, tachycardia, benign (DRVOTO) right ventricular outflow changes, trivial turbulence in any of the valvular apparatuses, or possibly excessive stethoscope pressure against the chest according to a recent study These are physiologically benign and unrelated to specific pathology.

**BREED**

Domestic Shorthair

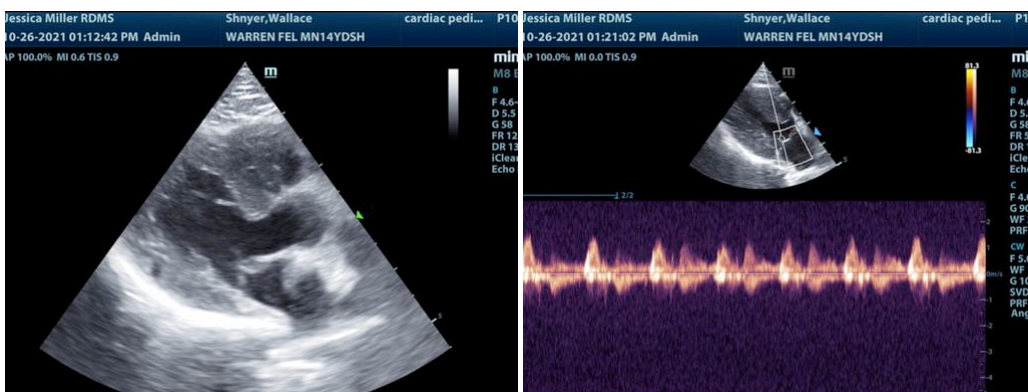
**SEX**

Neutered male

**AGE**

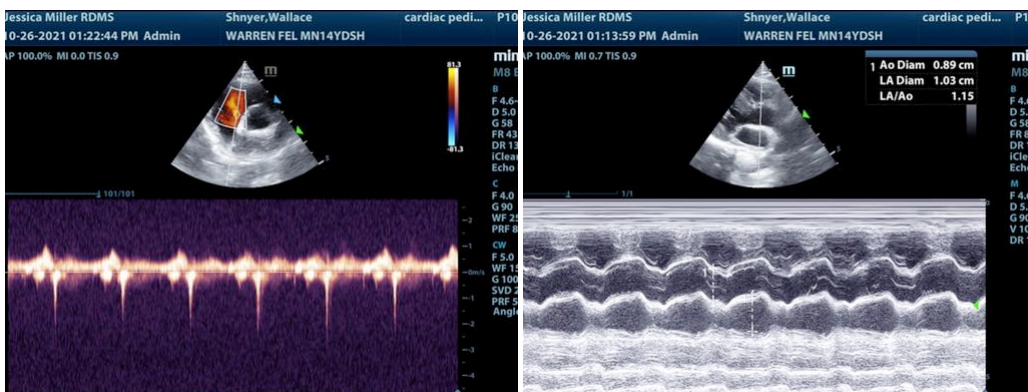
14 years

**WEIGHT**



**INTERPRETED BY**

Eric Lindquist, DMV  
DABVP, Cert. IVUSS

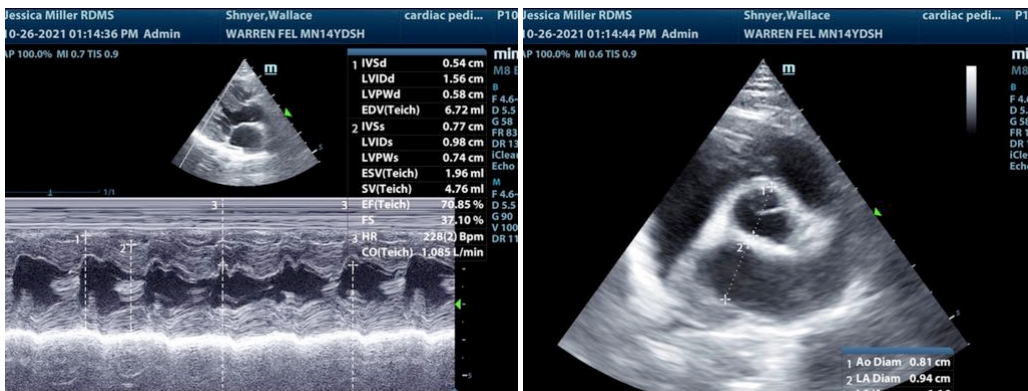


**IMAGING PERFORMED BY**

Jessica Miller, RDMS

**HOSPITAL NAME**

Warren AH



**REFERRING VET**

Dr. Brian

**INVOICE**

92635

**DATE**

10/26/21



**PATIENT**

Wallace Shnyer

**SPECIES**

Feline

**BREED**

Domestic Shorthair

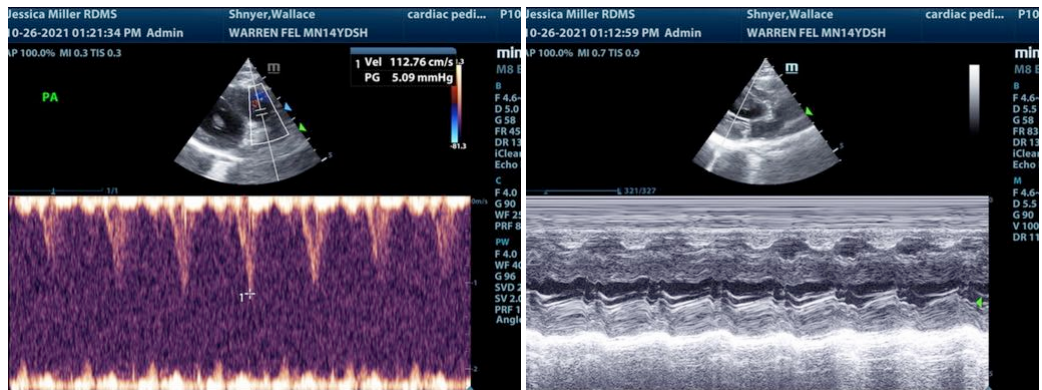
**SEX**

Neutered male

**AGE**

14 years

**WEIGHT**



The information and recommendations provided are based on the images presented by the referring veterinarian. No evaluation can be communicated regarding pathology that was not visible in the image/video clips provided.

Thank you for this referral. If the clinical or image interpretation does not parallel your findings or if I can be of any further assistance please contact me.

**Eric Lindquist**, DMV, DABVP, Cert. IVUSS, CEO of SonoPath.com  
info@SonoPath.com

**INTERPRETED BY**

Eric Lindquist, DMV  
DABVP, Cert. IVUSS

**IMAGING PERFORMED BY**

Jessica Miller, RDMS

**HOSPITAL NAME**

Warren AH

**REFERRING VET**

Dr. Brian

**INVOICE**

92635

**DATE**

10/26/21