

PATIENT PRESENTING CLINICAL SIGNS

PATIENT
Tyler Hurley
History: V/VI murmur, having syncopal episodes. No current meds.
Abnormal PE/Chem/CBC/UA Results: WNL

SPECIES

Feline

BREED

Domestic Shorthair

SEX

Neutered male

AGE

13 years

WEIGHT

9.7 lbs

INTERPRETED BY

Eric Lindquist, DMV
DABVP, Cert. IVUSS

IMAGING PERFORMED BY

Jessica Miller, RDMS

HOSPITAL NAME

Warren AH

REFERRING VET

Dr. Nicole

INVOICE

92648

DATE

10/26/21

ULTRASONOGRAPHIC EXAMINATION OF THE HEART

The echocardiogram in this patient demonstrated normal **left atrial** size and structure with no evidence of “smoke” or thrombi. The cranial and caudal **mitral valve** leaflets appeared mildly thickened with some insufficiency noted on Doppler. The **left ventricle** presented excessive free wall and septal thicknesses with hypertrophic thicknesses compared to normal for this species. The **myocardium** presented essentially normal echogenicity without immediate signs of fibrotic or ischemic disease. **Contractility** of the ventricular walls was considered excessive for this patient evidenced by the elevated fractional shortening measurement. The **left ventricular outflow** tract demonstrated turbulent laminar flow. Subjective assessment of the **right atrium** and auricle revealed normal size, structure and content. No evidence of masses was noted. **Tricuspid** valvular assessment demonstrated linear morphology. The **right ventricle** was of normal size with normal chordae structure, myocardial echogenicity and thickness. **Pulmonic** tract assessment revealed normal valve structure, laminar flow, and diameter. No visible **pericardial** or free pleura fluid was noted. No echographically detectable evidence of infiltrative disease was visible. The **mediastinum** was free of masses in the visible window.

| FELINE CARDIAC PARAMETERS | BODY WEIGHT | HR (BPM) | IVSd (cm) | LVIDd (cm) | LVWd (cm) | FS (%) | EF (%) |
|--|-----------------|------------------------------------|---|--------------------|--------------------|--------------|-----------|
| NORMAL PARAMETER | ----- | 150-240 | 0.3-0.6 | 1.0-2.1 | 0.25-0.6 | 35-67 | 80-100 |
| PATIENT | 9.7 lbs | 168 | 0.74 | 0.95 | 0.81 | 61 | 93 |
| FELINE CARDIAC PARAMETERS | LA/AO (Boon) | LA/AO HEART BASE (Sisson) | LA 2D 4-chamber long axis AS to FW (Sisson) (cm) | LVOT VEL. (m/s) | RVOT VEL. (m/s) | IVRT (m/) | |
| NORMAL PARAMETER | <1.5 | 0.88-1.79 | 0.7-1.7 | <1.6 | <1.3 | 40-60 | |
| PATIENT | 1.45 | 1.47 | 1.9 | 1.24 | 0.88 | NM | |
| Adapted from June Boon, Veterinary Echocardiography, 1998 Sisson D et al. JVIM 1991; 5: 232, Jacobs et al. Am J Vet Res 1985; 46:1705 | | | | | | | |

ULTRASONOGRAPHIC FINDINGS

Compensated left ventricular hypertrophy. Consistent with hypertrophic cardiomyopathy. Not clinically significant at this time.

Complicating effector organ pathology such as hyperthyroidism and hypertension should be ruled out.



PATIENT

Tyler Hurley

INTERPRETATION OF THE FINDINGS & FURTHER RECOMMENDATIONS

No therapy is recommended at this time. Recheck echocardiogram is recommended in 6 months.

SPECIES

Feline

BREED

Domestic Shorthair

SEX

Neutered male

AGE

13 years

WEIGHT

9.7 lbs

INTERPRETED BY

Eric Lindquist, DMV
DABVP, Cert. IVUSS

IMAGING PERFORMED BY

Jessica Miller, RDMS

HOSPITAL NAME

Warren AH

REFERRING VET

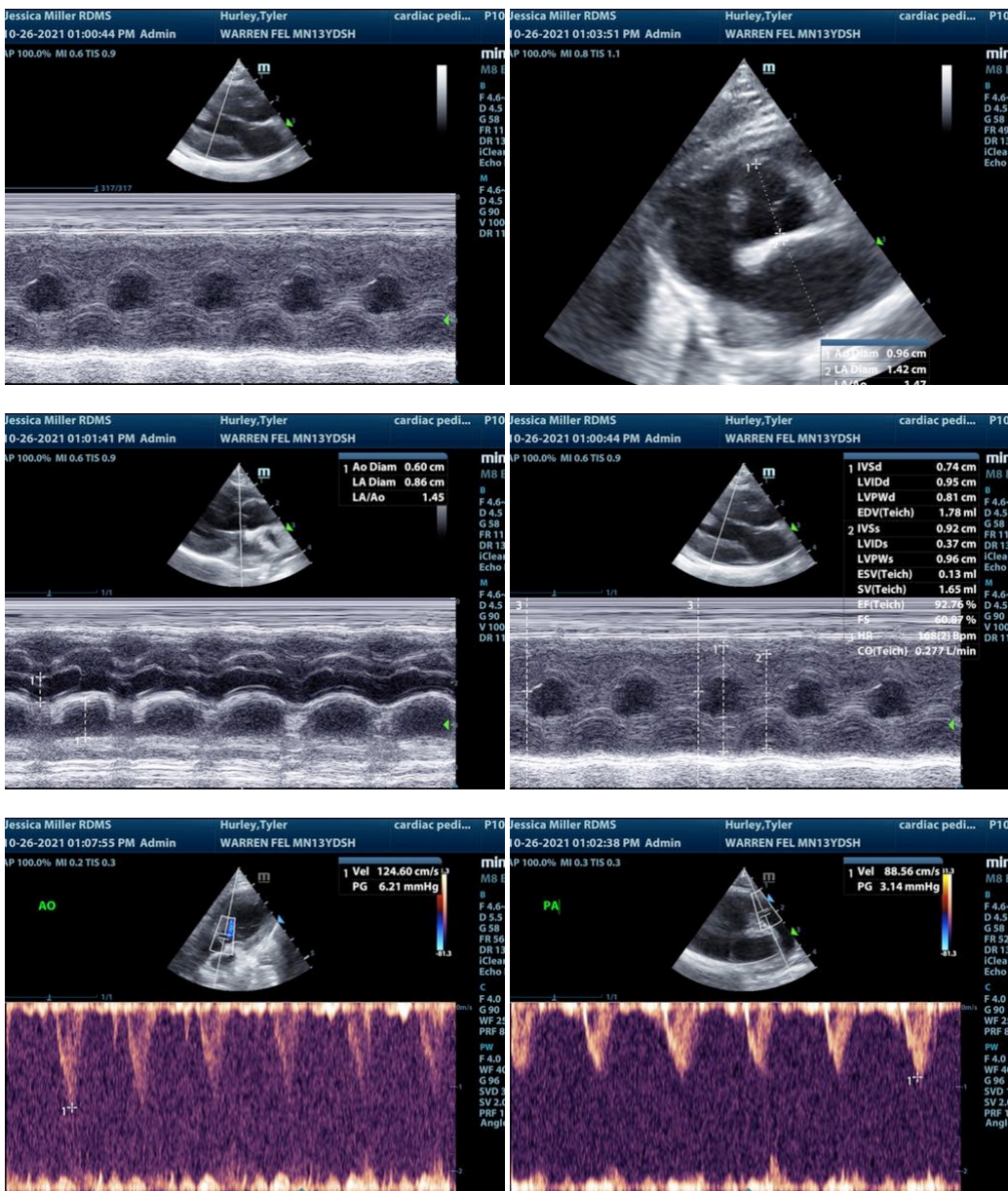
Dr. Nicole

INVOICE

92648

DATE

10/26/21





PATIENT

Tyler Hurley

SPECIES

Feline

BREED

Domestic Shorthair

SEX

Neutered male

AGE

13 years

WEIGHT

9.7 lbs

INTERPRETED BY

Eric Lindquist, DMV
DABVP, Cert. IVUSS

**IMAGING
PERFORMED BY**

Jessica Miller, RDMS

HOSPITAL NAME

Warren AH

REFERRING VET

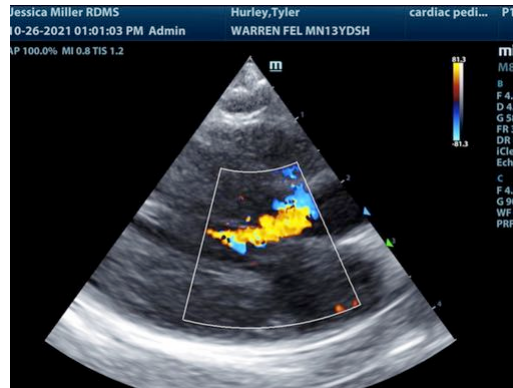
Dr. Nicole

INVOICE

92648

DATE

10/26/21



The information and recommendations provided are based on the images presented by the referring veterinarian. No evaluation can be communicated regarding pathology that was not visible in the image/video clips provided.

Thank you for this referral. If the clinical or image interpretation does not parallel your findings or if I can be of any further assistance please contact me.

Eric Lindquist, DMV, DABVP, Cert. IVUSS, CEO of SonoPath.com
info@SonoPath.com