



**PATIENT PRESENTING CLINICAL SIGNS**

Luna Ghelli History: ITP was well controlled lethargy

**SPECIES ULTRASONOGRAPHIC EXAMINATION OF THE ABDOMEN**

Canine

**Urinary System**

**BREED**

Labrador Mix

The **urinary bladder**, trigone, and pelvic urethra presented normal thicknesses and normal tone. The pelvic urethra was imaged 2.0 cm beyond the cystourethral junction. The ureters were not visible which is normal. No uroliths or sediment were visualized and anechoic urine was present. No evidence of inflammatory or neoplastic changes was noted. Ureteral papillae were normal.

**SEX**

Spayed Female

The **kidneys** revealed normal size and structure, corticomedullary definition and ratio for this age. The cortices presented largely uniform texture with normal echogenic relationship to liver and spleen. Medullary structure differed distinctly from the cortex and no evidence of pelvic dilation was present. The capsules were acceptably uniform without significant irregularities. The right kidney measured 6.12 cm. The left kidney measured 6.53 cm.

**AGE**

3 years

**WEIGHT**

64.5 lbs

**Adrenal Glands**

Both **adrenal glands** were visualized and recognized as having normal shape, size, position and echogenicity for this breed. The phrenic vasculature, glandular echogenicity and detail were unremarkable. Capsule, cortex, and medullary definition were normal for this age patient. The right adrenal gland measured 2.16 x 1.0 cm at the cranial pole and 0.49 cm at the caudal pole. The left adrenal gland measured 1.5 x 0.5 cm at the caudal pole and 0.47 cm at the cranial pole.

**INTERPRETED BY**

Eric Lindquist, DMV  
DABVP, Cert. IVUSS

**IMAGING PERFORMED BY**

Jenn

**Spleen**

The **spleen** presented a smooth homogeneous parenchyma hyperechoic to liver and renal cortical parenchyma. The capsule was smooth without noticeable expansion or deviation from within the spleen or adjacent pathology. The splenic vasculature demonstrated normal volume without signs of congestion or thrombosis. No sonographic evidence of acute or chronic inflammatory, neoplastic, or infarctual changes was noted.

**HOSPITAL NAME**

Rockaway AH

**REFERRING VET**

Dr. Maniar

**Liver**

Exam of the cranial abdomen demonstrated excessive **liver** size and swollen contour. Mild, coarse architecture was noted with increased portal markings and minor parenchymal remodeling is suggestive of an inflammatory component. Minor echogenic gallbladder wall was noted with a minor amount of sand. This is likely owing to Prednisone therapy.

**INVOICE**

92627

**DATE**

10/26/21

**Gastrointestinal**

Examination of the **gastrointestinal tract** revealed a stomach and intestine free of stasis, of normal wall thickness, acceptable curvilinear mural detail, and peristaltic activity. There was retention of ingesta



**PATIENT**

Luna Ghelli

noted in the stomach. Small and large intestine demonstrated normal luminal chyme and stool consistency respectively. No obstructive or overt infiltrative disease was noted. No associated abnormal lymphatic activity was noted.

**SPECIES**

Canine

**Pancreas**

The base and limbs of the **pancreas** were observed to be largely isoechoic to surrounding omental fat. Pancreatic duct and capsular contour were acceptably normal and parenchyma respected normal curvilinear patterns. No overt evidence of active inflammatory or neoplastic disease was noted.

**BREED**

Labrador Mix

**ULTRASONOGRAPHIC FINDINGS**

**SEX**

Spayed Female

Benign hepatopathy.

Minor gallbladder sand was noted.

**AGE**

3 years

Otherwise, unremarkable abdomen.

**INTERPRETATION OF THE FINDINGS & FURTHER RECOMMENDATIONS**

**WEIGHT**

64.5 lbs

There was no evidence of primary pathology playing a role in this case. Ursodiol therapy can be considered as a preventative.

**INTERPRETED BY**

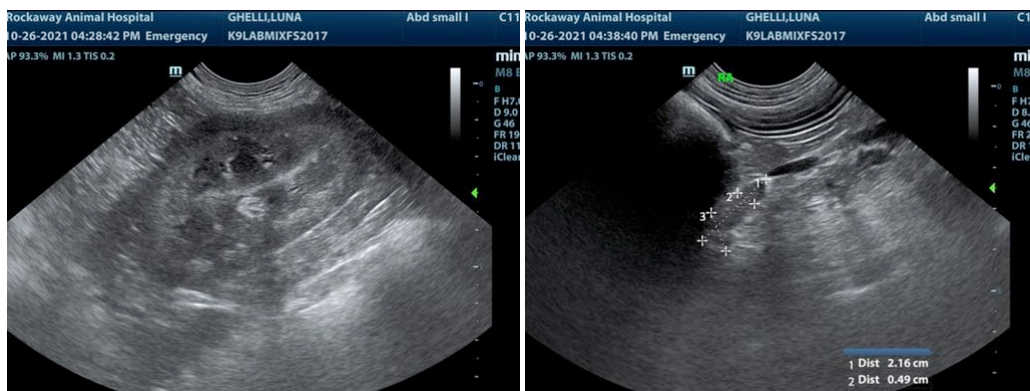
Eric Lindquist, DMV  
DABVP, Cert. IVUS

**IMAGING PERFORMED BY**

Jenn

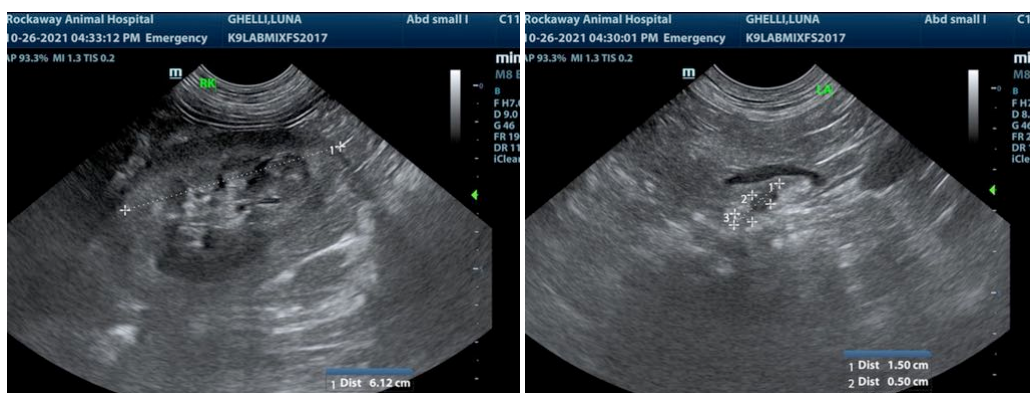
**HOSPITAL NAME**

Rockaway AH



**REFERRING VET**

Dr. Maniar



**INVOICE**

92627

**DATE**

10/26/21



**PATIENT**

Luna Ghelli

**SPECIES**

Canine

**BREED**

Labrador Mix

**SEX**

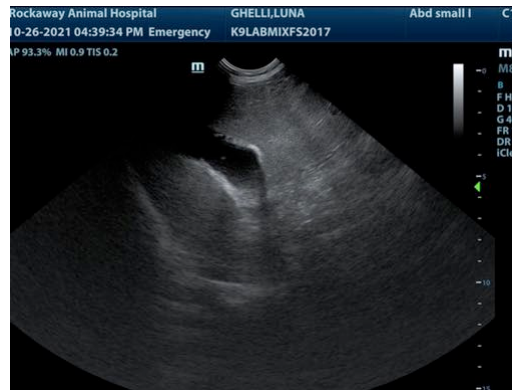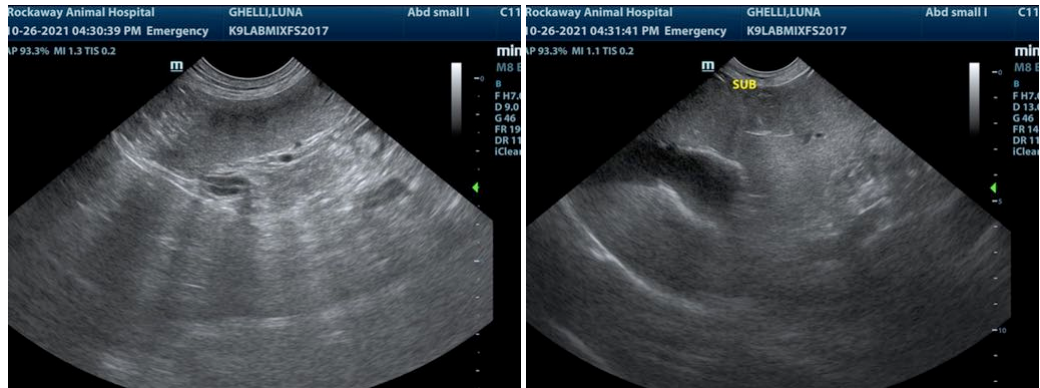
Spayed Female

**AGE**

3 years

**WEIGHT**

64.5 lbs



**INTERPRETED BY**

Eric Lindquist, DMV  
DABVP, Cert. IVUSS

**IMAGING PERFORMED BY**

Jenn

**HOSPITAL NAME**

Rockaway AH

**REFERRING VET**

Dr. Maniar

**INVOICE**

92627

**DATE**

10/26/21

The information and recommendations provided are based on the images presented by the referring veterinarian. No evaluation can be communicated regarding pathology that was not visible in the image/video clips provided.

Thank you for this referral. If the clinical or image interpretation does not parallel your findings or if I can be of any further assistance please contact me.

**Eric Lindquist, DMV, DABVP, Cert. IVUSS, CEO of SonoPath.com**  
info@SonoPath.com