



PATIENT

Kakashi Pineda

PRESENTING CLINICAL SIGNS

History: vomiting HGE lethargy

SPECIES

Canine

ULTRASONOGRAPHIC EXAMINATION OF THE ABDOMEN

Urinary System

BREED

Boston Terrier

The **urinary bladder**, trigone, and pelvic urethra presented normal thicknesses and normal tone. The ureters were not visible which is normal. No uroliths or sediment were visualized and anechoic urine was present. No evidence of inflammatory or neoplastic changes was noted. Ureteral papillae were normal.

SEX

Male

The **kidneys** revealed normal size and structure, corticomedullary definition and ratio for this age. The cortices presented largely uniform texture with normal echogenic relationship to liver and spleen. Medullary structure differed distinctly from the cortex and no evidence of pelvic dilation was present.

AGE

5 months

The capsules were acceptably uniform without significant irregularities. The right kidney measured 4.25 cm. The left kidney measured 4.57 cm.

WEIGHT

13.6 lbs

Adrenal Glands

Both **adrenal glands** were visualized and recognized as having normal shape, size, position and echogenicity for this breed. The phrenic vasculature, glandular echogenicity and detail were unremarkable. Capsule, cortex, and medullary definition were normal for this age patient. The right adrenal gland measured 1.58 x 0.44 cm at the caudal pole and 0.78 cm at the cranial pole. The left adrenal gland measured 1.43 x 0.41 cm at the caudal pole and 0.4 cm at the cranial pole.

INTERPRETED BY

Eric Lindquist, DMV
DABVP, Cert. IVUSS

IMAGING PERFORMED BY

Jenn

Spleen

The **spleen** presented a smooth homogeneous parenchyma hyperechoic to liver and renal cortical parenchyma. The capsule was smooth without noticeable expansion or deviation from within the spleen or adjacent pathology. The splenic vasculature demonstrated normal volume without signs of congestion or thrombosis. No sonographic evidence of acute or chronic inflammatory, neoplastic, or infarctual changes was noted.

HOSPITAL NAME

Rockaway AH

REFERRING VET

Dr. Maniar

Liver

The **liver** images submitted revealed subjectively normal liver size, contour, and structure. Parenchymal echogenicity was naturally coarse and hypoechoic to the spleen. Vascular and biliary tracts were of normal volume with no evidence of congestion. The gallbladder presented acceptably thin walls with primarily anechoic content. The cystic and common bile ducts were normal. No pathological hepatic lymphadenopathy was evident. No overt structural evidence of inflammatory, infiltrative or regenerative pathology was evident.

INVOICE

92628

DATE

10/26/21



PATIENT

Gastrointestinal

Kakashi Pineda

The **gastrointestinal tract** revealed an edematous wall and hyperperistalsis with no loss of mural detail. Minor enhanced surrounding fat was noted around the regions of the gastrointestinal serosa. There was no evidence of foreign body or neoplastic criteria. Images from the stomach, small intestine and colon were presented. This is most consistent with gastroenteritis owing to viral, bacterial/endotoxin or possible parasitic disease.

SPECIES

Canine

BREED

Pancreas

Boston Terrier

The **pancreas** was mildly hypoechoic to the surrounding mesentery. Low-grade pancreatic inflammation is suspected.

SEX

Male

ULTRASONOGRAPHIC FINDINGS

Gastroenteritis pattern, non-specific.

AGE

5 months

Low-grade pancreatic inflammation is suspected.

WEIGHT

13.6 lbs

INTERPRETATION OF THE FINDINGS & FURTHER RECOMMENDATIONS

There was no evidence of foreign matter. Supportive care should prove effective.

INTERPRETED BY

Eric Lindquist, DMV
DABVP, Cert. IVUSS

IMAGING PERFORMED BY

Jenn

HOSPITAL NAME

Rockaway AH

REFERRING VET

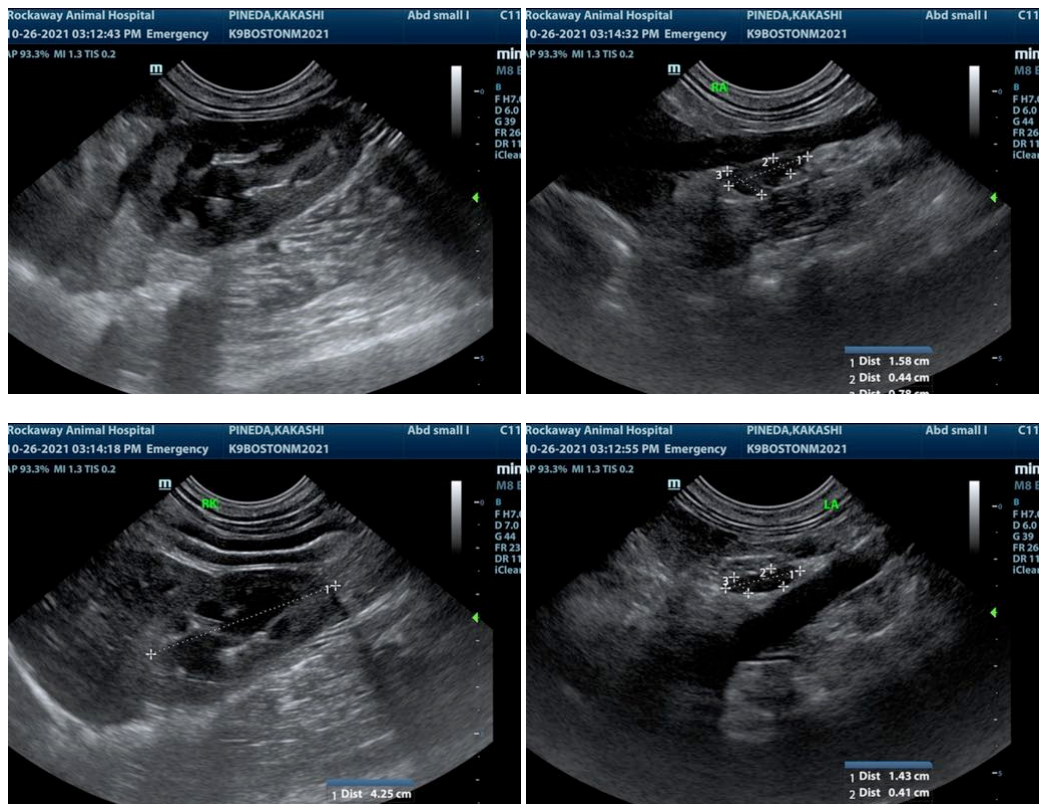
Dr. Maniar

INVOICE

92628

DATE

10/26/21





PATIENT

Kakashi Pineda

SPECIES

Canine

BREED

Boston Terrier

SEX

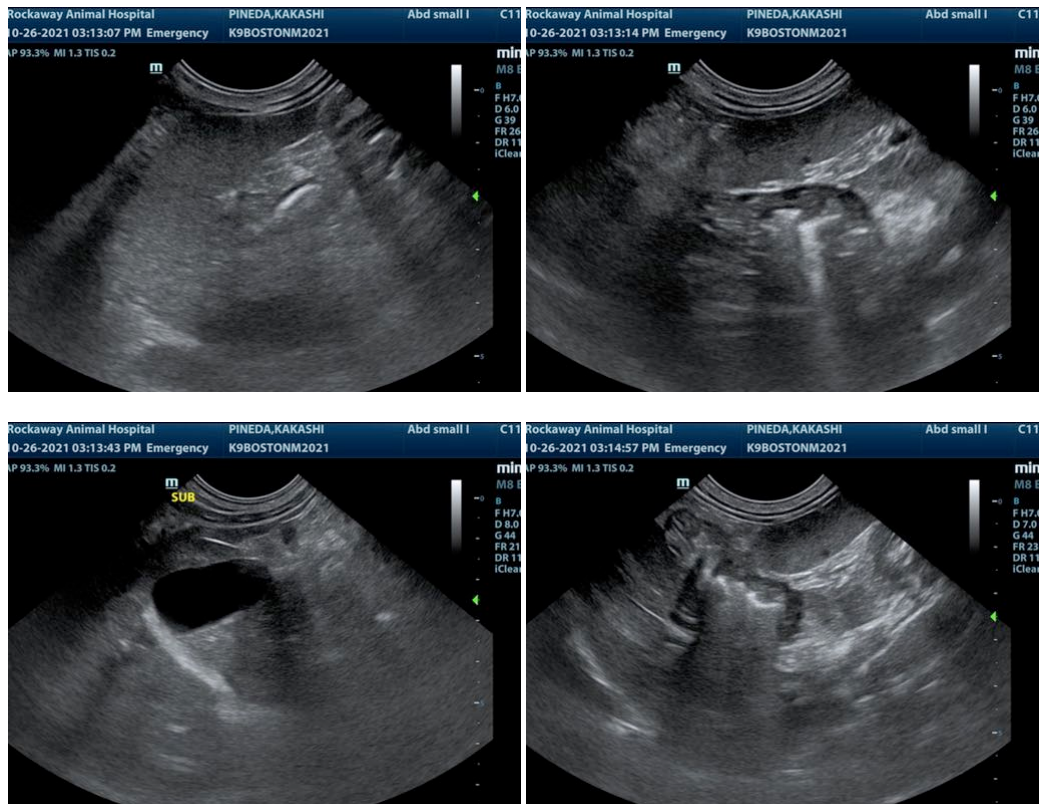
Male

AGE

5 months

WEIGHT

13.6 lbs



INTERPRETED BY

Eric Lindquist, DMV
DABVP, Cert. IVUSS

IMAGING PERFORMED BY

Jenn

HOSPITAL NAME

Rockaway AH

REFERRING VET

Dr. Maniar

INVOICE

92628

DATE

10/26/21

The information and recommendations provided are based on the images presented by the referring veterinarian. No evaluation can be communicated regarding pathology that was not visible in the image/video clips provided.

Thank you for this referral. If the clinical or image interpretation does not parallel your findings or if I can be of any further assistance please contact me.

Eric Lindquist, DMV, DABVP, Cert. IVUSS, CEO of SonoPath.com
info@SonoPath.com