



PATIENT

Cookie Drucker

SPECIES

Canine

BREED

Bichon Frise Poodle

SEX

Neutered male

AGE

11 years

WEIGHT

13 lbs

INTERPRETED BY

Eric Lindquist, DMV
DABVP, Cert. IVUSS

IMAGING PERFORMED BY

Dr. Gabriel

HOSPITAL NAME

Central Jersey AH

REFERRING VET

Dr. Gabriel

INVOICE

92681

DATE

10/27/21

PRESENTING CLINICAL SIGNS

History: PU/PD, weight loss still eating normally started him on 3 unites vetsulin twice daily liver appear enlarged on abdominal palpation

Abnormal PE/Chem/CBC/UA Results: blood work shows blood glucose 400mg/dl (ALT 204). (AST 144), (ALP 2224) (GGT 18)(triglyceride 396) urine has 3 + ketones and 3 + glucose

ULTRASONOGRAPHIC EXAMINATION OF THE ABDOMEN

Urinary System

The **urinary bladder**, trigone, and pelvic urethra presented normal thicknesses and normal tone. The ureters were not visible which is normal. No uroliths or sediment were visualized and anechoic urine was present. No evidence of inflammatory or neoplastic changes was noted. Ureteral papillae were normal.

The **kidneys** were normal in size and contour; however, a minor hyperechoic ring was noted at the corticomedullary junction. This is consistent with diabetic nephropathy. This is likely from glucosuria. However, assessment for proteinuria is also warranted. This is an idiopathic finding, but an expected finding in diabetic patients. The left kidney measured 4.19 cm.

Adrenal Glands

Both **adrenal glands** were visualized and recognized as having normal shape, size, position and echogenicity for this breed. The phrenic vasculature, glandular echogenicity and detail were unremarkable. Capsule, cortex, and medullary definition were normal for this age patient. The left adrenal gland measured 0.5 cm.

Spleen

The **spleen** in this patient was mildly enlarged with uniform parenchyma and was folded upon itself cranially. This is a positional variant and is not pathological. There was no evidence of significant disease.

Liver

The **liver** revealed diffuse, hyperechogenicity with coarse architecture. The gallbladder and common bile duct were unremarkable.

Gastrointestinal

Examination of the **gastrointestinal tract** revealed a stomach and intestine free of stasis, of normal wall thickness, acceptable curvilinear mural detail, and peristaltic activity. Small and large intestine demonstrated normal luminal chyme and stool consistency respectively. No obstructive or overt infiltrative disease was noted. No associated abnormal lymphatic activity was noted.



PATIENT

Pancreas

Cookie Drucker

The **pancreas** revealed hyperechoic changes in the right limb. This is consistent with fibrosis or remodeling.

SPECIES

Canine

ULTRASONOGRAPHIC FINDINGS

Diabetic related abdominal changes with vacuolar hepatopathy liver pattern.

BREED

Diabetic nephropathy.

Bichon Frise Poodle

Pancreatic remodeling.

SEX

Neutered male

INTERPRETATION OF THE FINDINGS & FURTHER RECOMMENDATIONS

If adrenal disease is suspected in this patient further imaging under sedation may be necessary to obtain images of the adrenal glands. FNA of the liver would be appropriate for further definition. However, subjectively it appears benign.

AGE

11 years

Potential Causes of Diabetic Dysregulation

WEIGHT

13 lbs

This is a suggestive checkoff list when faced with an unregulated diabetic patient:

INTERPRETED BY

Eric Lindquist, DMV
DABVP, Cert. IVUSS

- UTI
- Dietary indiscretion/intolerance
- Pancreatitis
- Hyperthyroidism/hypothyroidism
- Exogenous steroids (including topical eye meds)

IMAGING PERFORMED BY

Dr. Gabriel

Cushing's

HOSPITAL NAME

Central Jersey AH

Acromegaly

Owner compliance

REFERRING VET

Dr. Gabriel

Insulin quality issues

Antibodies to insulin

Underlying Neoplasia

INVOICE

92681

Diffuse liver disease

DATE

10/27/21



PATIENT

Cookie Drucker

SPECIES

Canine

BREED

Bichon Frise Poodle

SEX

Neutered male

AGE

11 years

WEIGHT

13 lbs

INTERPRETED BY

Eric Lindquist, DMV
DABVP, Cert. IVUSS

IMAGING PERFORMED BY

Dr. Gabriel

HOSPITAL NAME

Central Jersey AH

REFERRING VET

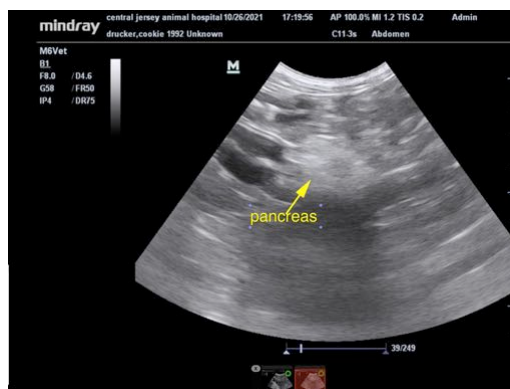
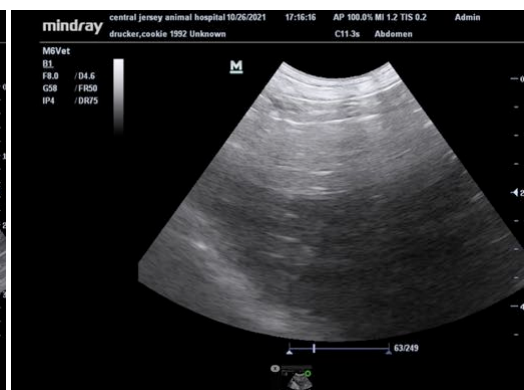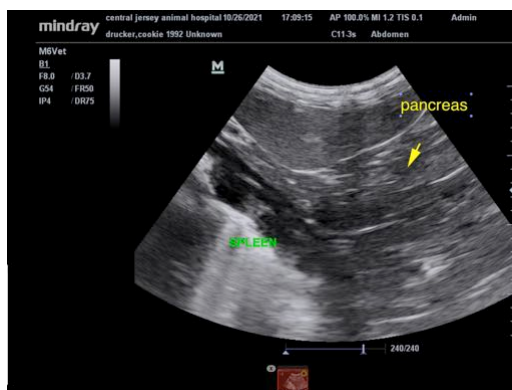
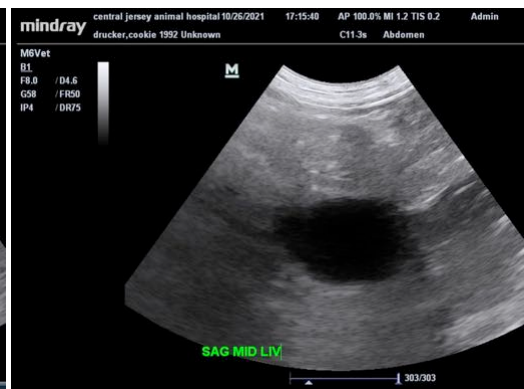
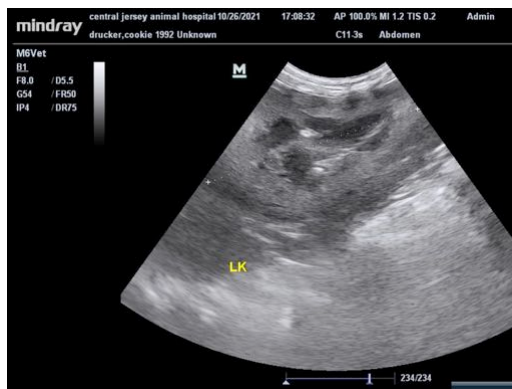
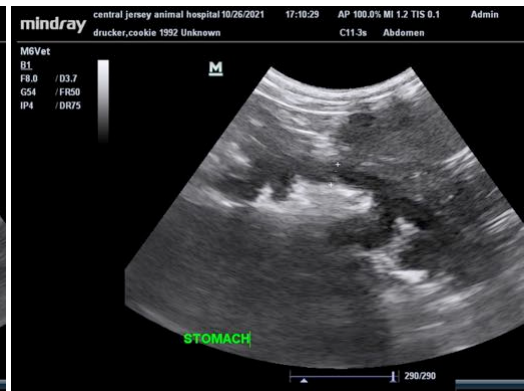
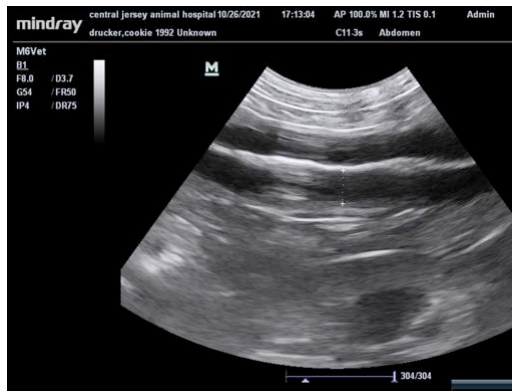Dr. Gabriel

INVOICE

92681

DATE

10/27/21



The information and recommendations provided are based on the images presented by the referring



PATIENT

Cookie Drucker

veterinarian. No evaluation can be communicated regarding pathology that was not visible in the image/video clips provided.

Thank you for this referral. If the clinical or image interpretation does not parallel your findings or if I can be of any further assistance please contact me.

SPECIES

Canine

Eric Lindquist, DMV, DABVP, Cert. IVUSS, CEO of SonoPath.com
info@SonoPath.com

BREED

Bichon Frise Poodle

SEX

Neutered male

AGE

11 years

WEIGHT

13 lbs

INTERPRETED BY

Eric Lindquist, DMV
DABVP, Cert. IVUSS

**IMAGING
PERFORMED BY**

Dr. Gabriel

HOSPITAL NAME

Central Jersey AH

REFERRING VET

Dr. Gabriel

INVOICE

92681

DATE

10/27/21