



PATIENT

Coco Casiano

PRESENTING CLINICAL SIGNS

Concern of urinary and prostatic issues. Patient is dribbling dark urine. Bacteruria and pyuria on UA, UCS negative, urine specific gravity 1.051.

SPECIES

Canine

ULTRASONOGRAPHIC EXAMINATION OF THE ABDOMEN

BREED

Labrador

Urinary System

The **urinary bladder**, trigone, and pelvic urethra presented normal thicknesses and normal tone. The ureters were not visible which is normal. Sand and small bladder stones were noted and measured 0.66 cm. No evidence of inflammatory or neoplastic changes was noted. Ureteral papillae were normal.

SEX

Neutered male

The prostate in this patient was enlarged at 4.24 x 3.34 cm with a 2.5 cm echogenic cyst or abscess in the right lobe and smaller cysts that measured 1.0 x 0.5 cm in the left lobe. Multi-focal areas of mineralization are noted. This is strongly suggestive for prostatic carcinoma. The prostate was significantly vascular on power Doppler assessment.

AGE

10 years

The **kidneys** revealed normal size and structure, corticomedullary definition and ratio for this age. The cortices presented largely uniform texture with normal echogenic relationship to liver and spleen. Medullary structure differed distinctly from the cortex and no evidence of pelvic dilation was present. The capsules were acceptably uniform without significant irregularities. The left kidney measured 7.5 cm. The right kidney measured 7.5 cm.

INTERPRETED BY

Eric Lindquist, DMV
DABVP, Cert. IVUSS

Adrenal Glands

Both **adrenal glands** were visualized and recognized as having normal shape, size, position and echogenicity for this breed. The phrenic vasculature, glandular echogenicity and detail were unremarkable. Capsule, cortex, and medullary definition were normal for this age patient. The left adrenal gland measured 2.55 x 0.82 cm. The right adrenal gland measured 2.39 x 1.36 cm at the cranial pole and 0.9 cm at the caudal pole.

IMAGING PERFORMED BY

Eric Lindquist, DMV
DABVP, Cert. IVUSS

HOSPITAL NAME

Butler VH

Spleen

REFERRING VET

Dr. Sereda

The **spleen** presented a smooth homogeneous parenchyma hyperechoic to liver and renal cortical parenchyma. The capsule was smooth without noticeable expansion or deviation from within the spleen or adjacent pathology. The splenic vasculature demonstrated normal volume without signs of congestion or thrombosis. No sonographic evidence of acute or chronic inflammatory, neoplastic, or infarctual changes was noted.

INVOICE

92630

Liver

DATE

10/26/21

The **liver** images submitted revealed subjectively normal liver size, contour, and structure. Parenchymal echogenicity was naturally coarse and hypoechoic to the spleen. Vascular and biliary tracts were of normal volume with no evidence of congestion. The gallbladder presented acceptably thin walls with primarily anechoic content. The cystic and common bile ducts were normal. No pathological hepatic lymphadenopathy was evident. No overt structural evidence of inflammatory, infiltrative or regenerative pathology was evident.



PATIENT

Coco Casiano

Gastrointestinal

SPECIES

Canine

Examination of the **gastrointestinal tract** revealed retention of ingesta in the stomach. The intestines were free of stasis, of normal wall thickness, acceptable curvilinear mural detail, and peristaltic activity. Small and large intestine demonstrated normal luminal chyme and stool consistency respectively. No obstructive or overt infiltrative disease was noted. No associated abnormal lymphatic activity was noted.

BREED

Labrador

Pancreas

SEX

Neutered male

The base and limbs of the **pancreas** were observed to be largely isoechoic to surrounding omental fat. Pancreatic duct and capsular contour were acceptably normal and parenchyma respected normal curvilinear patterns. No overt evidence of active inflammatory or neoplastic disease was noted.

AGE

10 years

ULTRASONOGRAPHIC FINDINGS

Mineralizing prostatic mass, strongly suspicious for carcinoma with possible abscessation.

Bladder sand and small stones.

INTERPRETED BY

Eric Lindquist, DMV
DABVP, Cert. IVUSS

INTERPRETATION OF THE FINDINGS & FURTHER RECOMMENDATIONS

Ultrasound-guided FNA with minor potential for trailing would be recommended as well as ultrasound-guided drainage of the cysts. Injection of antibiotic into the cyst is recommended if they appear flocculent or infected. If definitive cytology reveals prostatic carcinoma the following information may prove effective.

IMAGING PERFORMED BY

Eric Lindquist, DMV
DABVP, Cert. IVUSS

HOSPITAL NAME

Butler VH

REFERRING VET

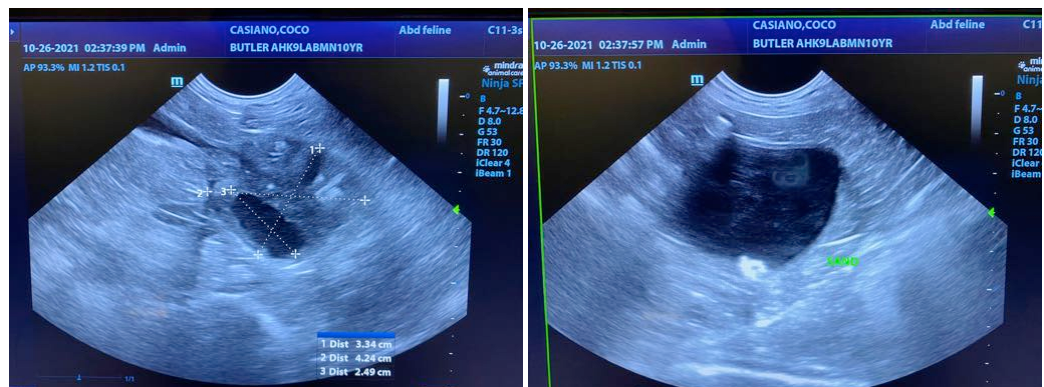
Dr. Sereda

INVOICE

92630

DATE

10/26/21





PATIENT

Coco Casiano

SPECIES

Canine

BREED

Labrador

SEX

Neutered male

AGE

10 years

INTERPRETED BY

Eric Lindquist, DMV
DABVP, Cert. IVUS

IMAGING PERFORMED BY

Eric Lindquist, DMV
DABVP, Cert. IVUS

HOSPITAL NAME

Butler VH

REFERRING VET

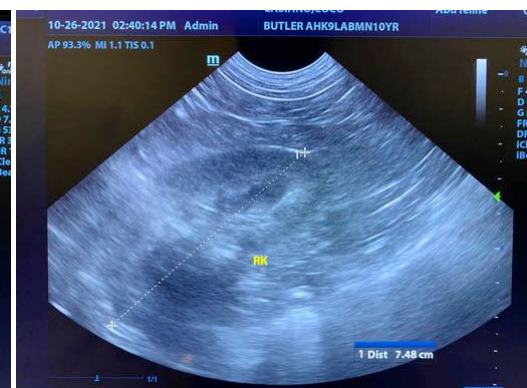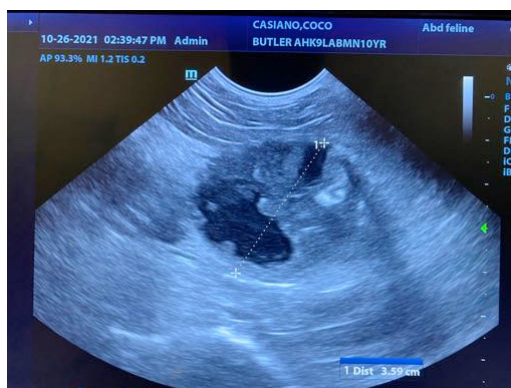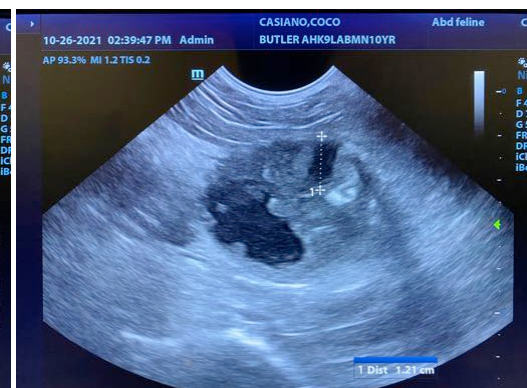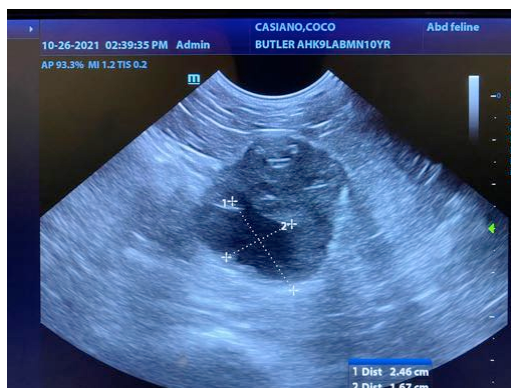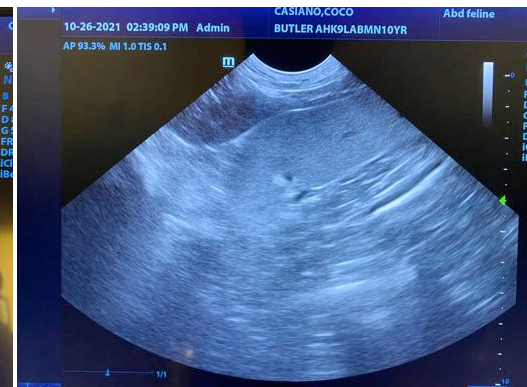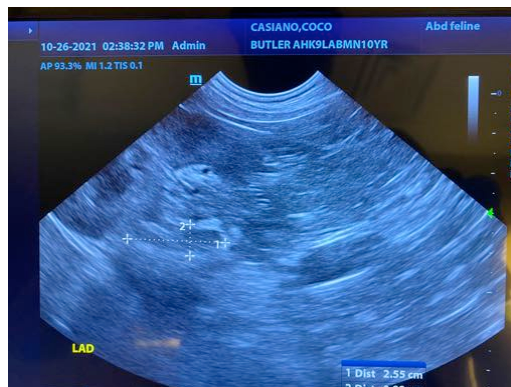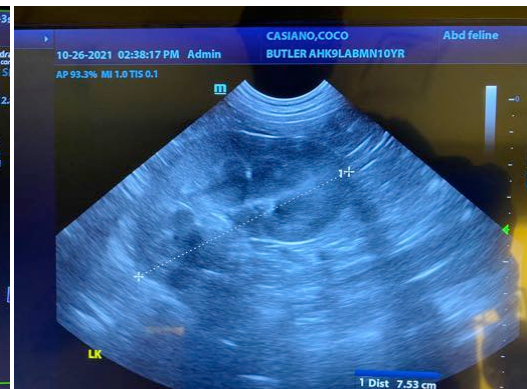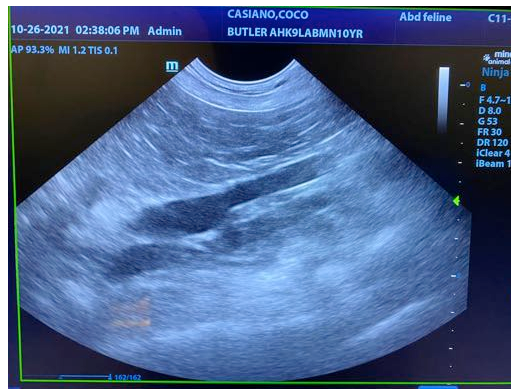Dr. Sereda

INVOICE

92630

DATE

10/26/21





PATIENT

veterinarian. No evaluation can be communicated regarding pathology that was not visible in the image/video clips provided.

Coco Casiano

Thank you for this referral. If the clinical or image interpretation does not parallel your findings or if I can be of any further assistance please contact me.


SPECIES

Canine

Eric Lindquist, DMV, DABVP, Cert. IVUSS, CEO of SonoPath.com
Info@SonoPath.com

BREED

Labrador



The following is an applicable excerpt from the *Curbside Guide to Diagnosis & Treatment of Sonographic Disease* offered by SonoPath.com Lindquist, Frank, Lobetti, and Modler.

SEX

Neutered male

An essential quick guide for every general practitioner and sonographer.

<https://sonopath.com/products/curbside-guide-editing-due-release-12012015>

AGE

10 years

Canine Prostatic Neoplasia

<http://www.sonopath.com/ProstaticCarcinoma>

INTERPRETED BY


Eric Lindquist, DMV
DABVP, Cert. IVUSS

IMAGING PERFORMED BY

Eric Lindquist, DMV
DABVP, Cert. IVUSS

HOSPITAL NAME

Butler VH



Long axis of the prostate in a neutered male dog with prostatic carcinoma. The prostatic gland (between calipers) is significantly enlarged. Multiple hyperechoic foci consistent with mineralization are seen. Note the low echogenicity of the prostatic parenchyma rendering the urethral pathway relatively hyperechoic. Also note the presence of power Doppler signal in the organ periphery which is not seen in normal prostatic glands and benign prostatic hyperplasia.

REFERRING VET

Dr. Sereda

Description: Prostatic neoplasia is frequently seen in dogs and can be diagnosed via ultrasonographic examination. The most commonly diagnosed prostatic neoplasms are adenocarcinoma and undifferentiated carcinoma. Transitional cell carcinoma (TCC) frequently spreads from the urinary bladder and urethra to the prostatic tissue (see the “Transitional Cell Carcinoma” chapter for more details). Metastatic squamous cell carcinoma, lymphoma, hemangiosarcoma, and leiomyosarcoma have been reported, but are less prevalent. Prostatic neoplasia has been documented in cats, but is quite rare.

INVOICE

92630

DATE

10/26/21

Clinical Signs: Prostatic neoplasia presents in both neutered and intact males; however, a 2002 study suggested that neutered males were at greater risk for developing prostatic neoplasia than intact males. Typically, prostatic neoplasia is seen in older dogs (mean age of 10 years). Breed predilection includes mixed breed dogs, Shetland Sheepdogs, Dobermans, Scottish Terriers, and Airedale Terriers. Clinical signs and commonly reported signs from owners typically include: stranguria, frequent urinations,



PATIENT

hematuria, dyschezia, weight loss, and decreased appetite. Other findings upon physical examination include fever, ataxia, pain upon rectal examination, and pain upon spinal palpation.

Coco Casiano

SPECIES

Diagnostics: Ultrasonographic examination should be performed if prostatic neoplasia is suspected. Common ultrasonographic findings include an enlarged, irregular prostate that typically has a hypoechoic appearance. Multifocal, poorly coalescing hyperechoic foci are also seen in prostatic malignancies. Hyperechoic foci are due to mineralization of the prostate; they cause far field shadowing. Cystic components can also be observed and are thought to indicate abscessation and/or necrosis. It can be difficult to differentiate chronic bacterial prostatitis from a prostatic neoplasia; however, regional lymphadenopathy is much more common with prostatic neoplasia than it is with chronic bacterial prostatitis. Malignancies of the prostate have often metastasized by the time of diagnosis. Frequent sites of metastases include the sublumbar lymph nodes, the pelvis, lumbar vertebrae, and the lungs. If metastases to the pelvis or lumbar vertebrae have occurred, bony lysis will often be noted radiographically. Metastasis to the liver, brain, kidney and spleen may occur. A definitive diagnosis of a prostatic neoplasm can be achieved through biopsy as well as fine needle aspiration (FNA) or through ultrasound-guided traumatic catheterization.

Canine

BREED

Labrador

SEX

Neutered male

AGE

10 years

A complete and thorough workup includes a CBC, biochemical profile, urinalysis, as well as three radiographic views of the thorax, an abdominal ultrasound, and an ultrasound-guided prostatic biopsy or FNA, if indicated. Urinalysis may reveal hematuria and pyuria. Prostatic fluid analysis can also be helpful in identifying neoplastic cells.

INTERPRETED BY

Eric Lindquist, DMV
DABVP, Cert. IVUSS

IMAGING PERFORMED BY

Eric Lindquist, DMV
DABVP, Cert. IVUSS

Treatment: Unfortunately, once diagnosed, prostatic carcinoma offers a poor prognosis; prostatectomy, chemotherapy, and radiation therapy have proven unsuccessful in improving quality or length of life. Nonsteroidal anti-inflammatory drugs (NSAIDs), such as deracoxib, meloxicam, and piroxicam, have been used for their palliative, anti-neoplastic properties with prostatic carcinomas. Certain tumors, including various carcinomas (e.g. TCC, prostatic carcinoma, mammary carcinoma, squamous cell carcinoma) overexpress COX-2, which converts arachidonic acid to prostaglandin G₂ (PGG₂)/prostaglandin H₂ (PGH₂), and ultimately to prostaglandin E₂ (PGE₂). The metabolite, PGE₂, is associated with increased inflammation, tumor invasiveness, angiogenesis, and reduced apoptosis. In vivo and in vitro, NSAIDs inhibit COX-2, resulting in the suppression of PGE₂, and thereby inhibiting tumor growth and metastasis. This effect has been achieved with both non-selective COX inhibitors as well as COX-2 inhibitors (the latter will suppress COX-1 at increased doses).

HOSPITAL NAME

Butler VH

REFERRING VET

Dr. Sereda

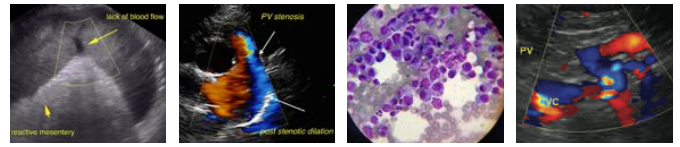
INVOICE

92630

DATE

10/26/21

Some cases of prostatic carcinoma are managed palliatively with cyst/abscess ultrasound-guided drainage, antibiotic infusion, systemic antibiotics, and NSAID treatment and/or chemotherapy. Anecdotally, it has been observed that patients that often present clinical signs of hematuria or dysuria owing to cyst or abscess formation may be treated with repeat ultrasound-guided drainage. This appears to work especially well if there is a considerable cystic component to the prostatic tumor. The key is to image the prostate adequately, drain any cysts that are present, sample the abnormal parenchyma (FNA or biopsy), and potentially infuse antibiotics directly into the cystic cavities if a suppurative fluid is retrieved. The patient should be monitored clinically over time and reevaluated to see if cysts recur. Every case responds differently to treatment, and the behavior of parenchymal and cystic growth will vary.



PATIENT

Coco Casiano

Currently, investigational studies involving fluoroscopic-guided direct chemotherapeutic embolization through the iliac arteries as well as urethral stent placement are offered by select tertiary veterinary facilities that have an interventional radiology department. Ultrasound-guided endoscopic diode laser ablation through a perineal urethrostomy is also being attempted as a salvage and palliative procedure.

SPECIES

Canine

Conclusion: Prostatic neoplasia is more commonly detected in neutered male dogs than intact males. Diagnosis is typically obtained using ultrasound, cytology, and histopathology. Unfortunately, traditional therapy typically yields a guarded to poor long-term prognosis, but palliation with NSAIDs and/or chemotherapy can temporarily improve clinical signs. Investigational techniques may provide additional therapeutic options but are currently experimental.

BREED


Labrador

SEX

Neutered male

AGE

10 years



Long axis of the prostate in a dog with prostatic carcinoma with cystourethral junction to the left. Note the typical “starry sky” pattern of prostatic carcinoma with multiple echogenic foci representing mineralizations (arrow) on a relatively hypoechoic background created by the neoplastic infiltrate. Considerable vascularity is present throughout the parenchyma noted on power Doppler.

INTERPRETED BY


Eric Lindquist, DMV
DABVP, Cert. IVUSS

IMAGING PERFORMED BY

Eric Lindquist, DMV
DABVP, Cert. IVUSS

HOSPITAL NAME

Butler VH



Long axis of the prostate in a dog with prostatic carcinoma during ultrasound guided sampling. The prostatic mass is largely isoechoic to surrounding fat in this particular example and can easily be missed without correct gain and focal point adjustments. The needle trajectory is seen as a weakly echogenic interface (arrowheads). Note the echo yield is limited technically by the steep insonation angle here. Note the sharp deviation of the descending colon owing to the prostatic mass effect upon it (arrow). This colonic deviation was a key point toward identifying this isoechoic prostatic mass in this case.

REFERRING VET

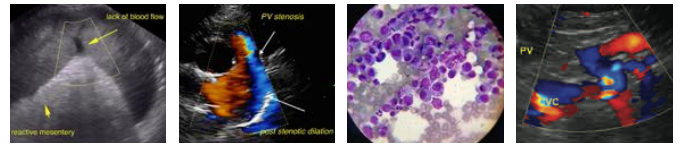
Dr. Sereda

INVOICE

92630

DATE

10/26/21



PATIENT

Coco Casiano

SPECIES

Canine

BREED

Labrador

SEX

Neutered male

AGE

10 years

INTERPRETED BY

Eric Lindquist, DMV
DABVP, Cert. IVUSS

**IMAGING
PERFORMED BY**

Eric Lindquist, DMV
DABVP, Cert. IVUSS

HOSPITAL NAME

Butler VH

REFERRING VET



Dr. Sereda

INVOICE

92630

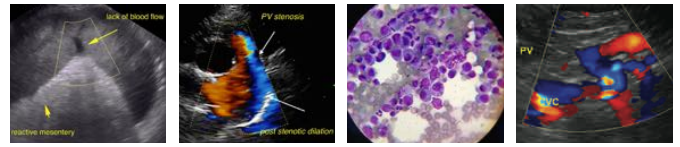
DATE

10/26/21



Long axis of the prostate in a dog with prostatic carcinoma during ultrasound guided sampling. The prostatic mass is largely isoechoic to surrounding fat in this particular example and can easily be missed without correct gain and focal point adjustments. The needle trajectory is seen as a weakly echogenic interface (arrowheads). Note the echo yield is limited technically by the steep insonation angle here. Note the sharp deviation of the descending colon owing to the prostatic mass effect upon it (arrow). This colonic deviation was a key point toward identifying this isoechoic prostatic mass in this case.

Long axis of the prostate in a neutered male dog with prostatic carcinoma. Note that prostatic carcinomas are not necessarily large and commonly similar in echogenicity and echotexture as compared to the surrounding peritoneal fat. Proper scanning technique tracing the bladder neck and urethra is essential not to miss the lesion.



PATIENT

Coco Casiano

SPECIES

Canine

BREED

Labrador

SEX

Neutered male

AGE

10 years

INTERPRETED BY

Eric Lindquist, DMV
DABVP, Cert. IVUSS

IMAGING PERFORMED BY

Eric Lindquist, DMV
DABVP, Cert. IVUSS

HOSPITAL NAME

Butler VH

REFERRING VET


Dr. Sereda

INVOICE


92630

DATE

10/26/21



Short axis of the prostate in a dog with cystic prostatic carcinoma. Multifocal intraparenchymal cyst-like lesions with anechoic to hypoechoic content are seen. Asymmetric enlargement is noted. The regular bilobed shape and typical dorsal notch are lost. The echotexture in this particular prostatic mass is reminiscent of the occasional prostatic lymphoma that can occur as exemplified in the next image.



Cross section of the prostate in a dog with enlarged irregular prostate. The regular parenchymal echoarchitecture is displaced by two well delineated hypoechoic nodules (arrows). Note the generalized swelling of the gland. The sonographic appearance resembles prostatitis and abscessation, yet the diagnosis was significantly different on USG FNA (prostatic lymphoma). Note: abscessation can be differentiated from proliferative nodules with power Doppler as signals are negative with abscessation or necrosis and typically positive with tissue proliferation.

References:

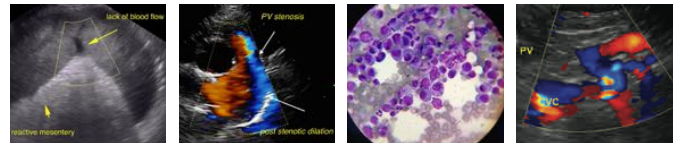
Cerf DJ, Lindquist EC. Palliative ultrasound-guided endoscopic laser ablation of transitional cell carcinomas of the lower urinary tract in dogs. *J Am Vet Med Assoc* 2012;240(1):51-60.

Culp, WTN. Interventional oncology and the management of urinary tract cancer. Proceedings from the American College of Veterinary Internal Medicine, New Orleans, LA, May 30-June 2, 2012.

Francey T. Prostatic Diseases. In: Ettinger SJ, Feldman EC, eds. *Textbook of Veterinary Internal Medicine 7th ed.* Philadelphia, PA: WB Saunders; 2010:2047-58.

Hecht S. Male Reproductive Tract. In: Pennick D, D'Anjou MA, eds. *Atlas of Small Animal Ultrasonography.* Ames, IA: Blackwell Publishing; 2008:417-43.

Milner RJ. Do NSAIDs make a difference in cancer. Proceedings from the American College of Veterinary Internal Medicine, Denver, CO, June 15-18, 2011.



PATIENT

Coco Casiano

Mohammed SI, Khan KN, Sellers RS, et al. Expression of cyclooxygenase-1 and 2 in naturally-occurring canine cancer. *Prostag Leukotr Ess* 2004;70(5):479-83.

Nyland, TG, Mattoon JS. *Small Animal Diagnostic Ultrasound 2nd ed.* Philadelphia, PA: WB Saunders; 2002:250-66.

SPECIES

Canine

Sorenmo KU, Goldschmidt MH, Shofer FS, et al. Evaluation of cyclooxygenase-1 and cyclooxygenase-2 expression and the effect of cyclooxygenase inhibitors in canine prostatic carcinoma. *Vet Comp Oncol* 2004;2(1):13-23.

BREED

Labrador

SEX

Neutered male

AGE

10 years

INTERPRETED BY

Eric Lindquist, DMV
DABVP, Cert. IVUSS

**IMAGING
PERFORMED BY**

Eric Lindquist, DMV
DABVP, Cert. IVUSS

HOSPITAL NAME

Butler VH

REFERRING VET

Dr. Sereda

INVOICE

92630

DATE

10/26/21