



PATIENT

Heidi Dahdouli

SPECIES

Feline

BREED

Domestic Shorthair

SEX

Spayed female

AGE

13 years

WEIGHT

15 lbs

INTERPRETED BY

Eric Lindquist, DMV
DABVP, Cert. IVUSS

IMAGING PERFORMED BY

Jenn

HOSPITAL NAME

Rockaway AH

REFERRING VET

Dr. Maniar

INVOICE

42121

DATE

10/25/22

PRESENTING CLINICAL SIGNS

History: had bladder mass removal 1 week prior owner picked up today and went into resp distress in car

ULTRASONOGRAPHIC EXAMINATION

The chest in this patient revealed multiple areas of lung consolidation. Minimal view of the heart revealed no evidence of volume overload and no tachycardia.

LA:AO June Boon 1.0

HR 160 bpm

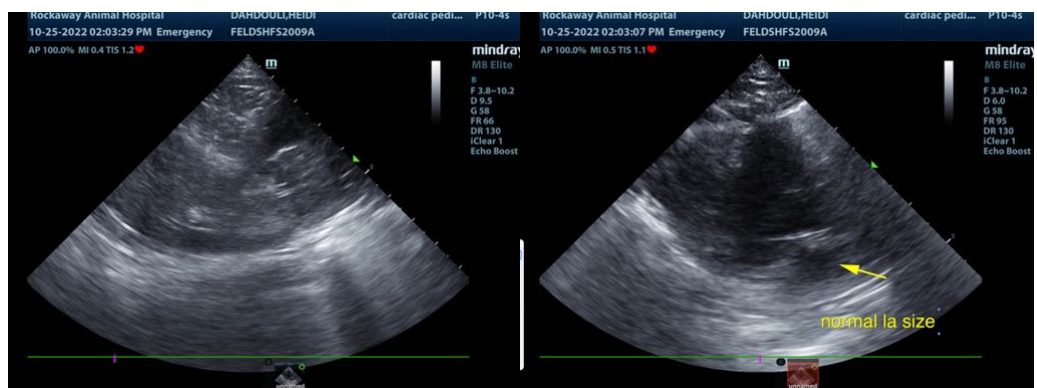
Rapid view of the liver revealed no evidence of pathology.

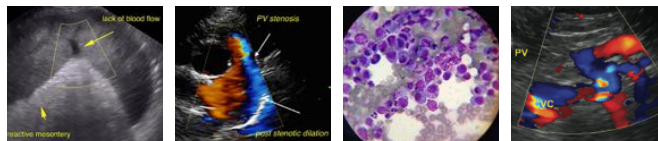
ULTRASONOGRAPHIC FINDINGS

Come tail lung pattern, consistent with alveolar disease, thromboembolic disease, pneumonitis and pneumonia are all possible given the sudden onset.

INTERPRETATION OF THE FINDINGS & FURTHER RECOMMENDATIONS

Primary respiratory protocol is warranted. There was no evidence of cardiac disease.





PATIENT

Heidi Dahdouli

SPECIES

Feline

BREED

Domestic Shorthair

SEX

Spayed female

AGE

13 years

WEIGHT

15 lbs

INTERPRETED BY

Eric Lindquist, DMV
DABVP, Cert. IVUSS

**IMAGING
PERFORMED BY**

Jenn

HOSPITAL NAME

Rockaway AH

REFERRING VET

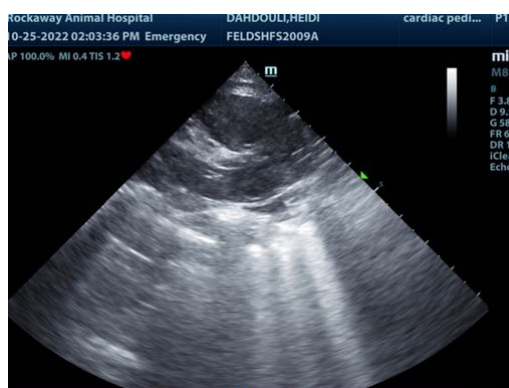Dr. Maniar

INVOICE

42121

DATE

10/25/22



The information and recommendations provided are based on the images presented by the referring veterinarian/sonographer. No evaluation can be communicated regarding pathology that was not visible in the image/video clips provided.

Thank you for this referral. If the clinical or image interpretation does not parallel your findings or if I can be of any further assistance please contact me.

Eric Lindquist, DMV, DABVP, Cert. IVUSS, CEO of SonoPath.com
info@SonoPath.com