



PATIENT

Guinness Paynter

SPECIES

Canine

BREED

Dachshund

SEX

Neutered male

AGE

14 years

WEIGHT

1 lb

INTERPRETED BY

Eric Lindquist, DMV
DABVP, Cert. IVUSS

**IMAGING
PERFORMED BY**

Pascucci

HOSPITAL NAME

American AH

REFERRING VET

Dr. Stockmal

INVOICE

42143

DATE

10/25/22

PRESENTING CLINICAL SIGNS

History: Presented to ER last night because his abdomen was bloated and uncomfortable to the touch but is otherwise normal. Mass effect in caudal abd on rads, suspect hemoabdomen, anemia found. Presented to us for ultrasound today.
Abnormal PE/Chem/CBC/UA Results: HCT 26%, Neu 18.9k, Lymph 0.8, Eos 0.2, Glob 3.9

ULTRASONOGRAPHIC EXAMINATION OF THE ABDOMEN

Urinary System

The **urinary bladder**, trigone, and pelvic urethra presented normal thicknesses and normal tone. The ureters were not visible which is normal. No uroliths or sediment were visualized and anechoic urine was present. No evidence of inflammatory or neoplastic changes was noted. Ureteral papillae were normal.

The **right kidney** revealed largely normal size and structure, corticomedullary definition and ratio (cortex 1/3 of medulla) were essentially maintained with some age-related loss of curvilinear patterns regarding the capsule and C/M junction. The cortices presented largely uniform texture with some increased echogenicity expected for his age patient. Medullary structure differed distinctly from that of the cortex and no evidence of pelvic dilation was present. The right kidney measured 4.0 cm. The left kidney was not visualized.

Adrenal Glands

The **adrenal glands** are not visualized.

Spleen

Minimal images of the **spleen** were visualized, yet appeared unremarkable.

Liver

A large, cystic, mixed echogenic peripherally inflamed mass was noted in this patient. The mass appears to be deriving from the left liver. There are parenchymal portions of the mass noted. The mass occupies the majority of the abdomen. The mass appears to be deviating the spleen caudally, yet I cannot completely rule out the potential of splenic involvement. The right liver presented some nodular changes. The gallbladder revealed a minor amount of debris.

Gastrointestinal

The **gastrointestinal tract** was deviated owing to masses effects.



PATIENT

Pancreas

Guinness Paynter

The **pancreas** was obscured by the mass.

SPECIES

Canine

Free Abdomen

A minor amount of fluid was noted.

BREED

Dachshund

ULTRASONOGRAPHIC FINDINGS

Extensive cystic and parenchymal hepatic mass, possibly resectable.

SEX

Neutered male

Free fluid noted.

INTERPRETATION OF THE FINDINGS & FURTHER RECOMMENDATIONS

AGE

14 years

CT is warranted for further definition. Some hemorrhage may be owing to the mass itself. Dramatic hemoabdomen may have been present. The left kidney was not visualized. I cannot rule out renal or splenic involvement in the mass.

WEIGHT

1 lb

ABOUT SONOPATH CT SERVICES:

INTERPRETED BY

Eric Lindquist, DMV
DABVP, Cert. IVUSS

SonoPath CT Services are offered at the SonoPath Imaging and Veterinary Education Center, 141 Main St (rt 206), Andover, New Jersey, a 20-minute drive west on route 80/206 North from the route 80/287 interchange/Parsippany, New Jersey. More information can be found at <https://sonopath.com/services/sonopath-ct-services>

IMAGING PERFORMED BY

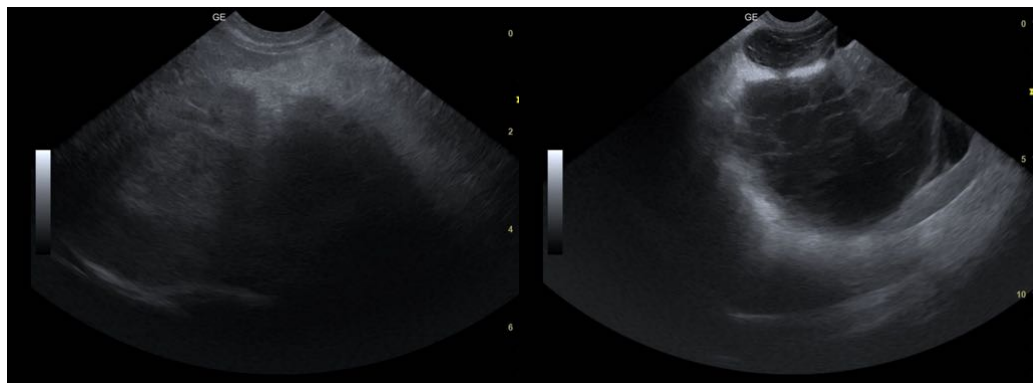
Pascucci

HOSPITAL NAME

American AH

REFERRING VET

Dr. Stockmal



INVOICE

42143

DATE

10/25/22



PATIENT

Guinness Paynter

SPECIES

Canine

BREED

Dachshund

SEX

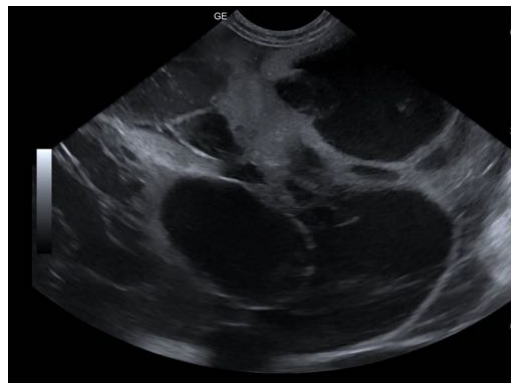
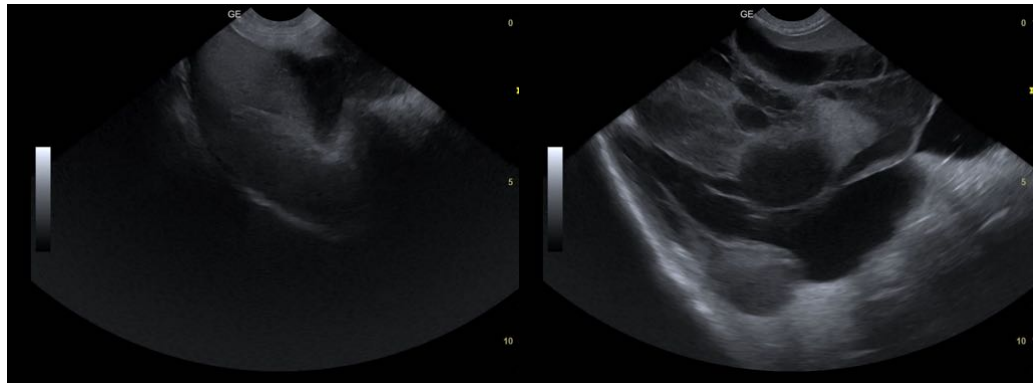
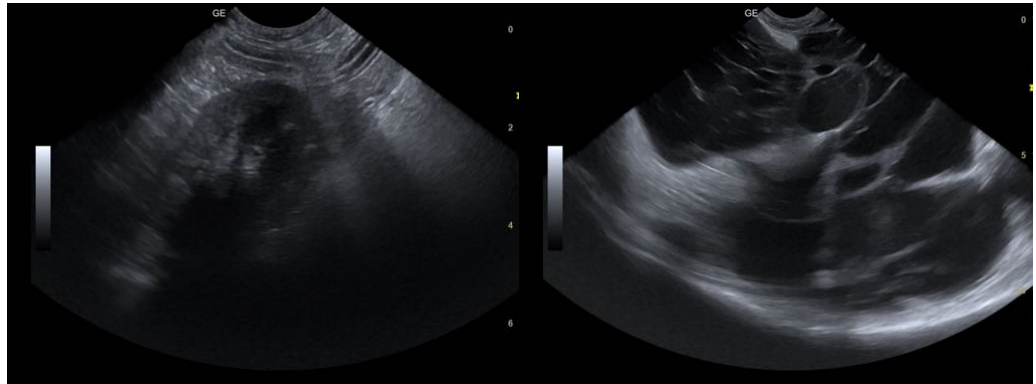
Neutered male

AGE

14 years

WEIGHT

1 lb



INTERPRETED BY

Eric Lindquist, DMV
DABVP, Cert. IVUSS

IMAGING PERFORMED BY

Pascucci

HOSPITAL NAME

American AH

REFERRING VET

Dr. Stockmal

INVOICE

42143

DATE

10/25/22

The information and recommendations provided are based on the images presented by the referring veterinarian/sonographer. No evaluation can be communicated regarding pathology that was not visible in the image/video clips provided.

Thank you for this referral. If the clinical or image interpretation does not parallel your findings or if I can be of any further assistance please contact me.

Eric Lindquist, DMV, DABVP, Cert. IVUSS, CEO of SonoPath.com
info@SonoPath.com