



**PATIENT**

TJ Waller

**PRESENTING CLINICAL SIGNS**

RDVM treated for pancreatitis, then performed an exploratory laparotomy a couple of weeks ago. Pancreatic mass seems to be wrapped up in omentum and bowel. Abnormal PE/Chem/CBC/UA Results: No lab work sent.

**SPECIES**

Canine

**ULTRASONOGRAPHIC EXAMINATION OF THE ABDOMEN**

**Urinary System**

The **urinary bladder**, trigone, and pelvic urethra presented normal thicknesses and normal tone. The ureters were not visible which is normal. No uroliths or sediment were visualized and anechoic urine was present. No evidence of inflammatory or neoplastic changes were noted. Ureteral papillae were normal.

**BREED**

Jack Russell Terrier X

**SEX**

Male

The **kidneys** revealed normal size and structure, corticomedullary definition and ratio for this age. The cortices presented largely uniform texture with normal echogenic relationship to liver and spleen. Medullary structure differed distinctly from the cortex and no evidence of pelvic dilation was present. The capsules were acceptably uniform without significant irregularities. The left kidney measured 4.0 cm. The right kidney measured 4.0 cm with an anechoic cyst noted in the cranial pole.

**AGE**

12 Years

**Adrenal Glands**

The **right adrenal gland** visualized and recognized as having normal shape, size, position and echogenicity for this breed. The phrenic vasculature, glandular echogenicity and detail were unremarkable. Capsule, cortex, and medullary definition were normal for this age patient. The right adrenal gland measured 0.6 cm. The region of the **left adrenal gland** was unremarkable.

**WEIGHT**

15 Pounds

**Spleen**

The **spleen** presented a smooth homogeneous parenchyma hyperechoic to liver and renal cortical parenchyma. The capsule was smooth without noticeable expansion or deviation from within the spleen or adjacent pathology. The splenic vasculature demonstrated normal volume without signs of congestion or thrombosis. No sonographic evidence of acute or chronic inflammatory, neoplastic, or infarctual changes were noted.

**INTERPRETED BY**

Eric Lindquist, DMV  
DABVP, Cert. IVUSS

**Liver**

The **liver** was coarse in architecture with increased portal markings. Hypoechoic micronodular changes noted. The liver was particularly swollen in the caudate process with lobar hypertrophy. The gallbladder was unremarkable. No evidence of biliary disease.

**IMAGING PERFORMED BY**

Harold Mike Beard

**HOSPITAL NAME**

West Prince AH

**Gastrointestinal**

The **stomach** revealed a moderate amount of stasis with edematous wall. The distal small intestine was unremarkable

**REFERRING VET**

Dr. Mike Pallone

**Pancreas**

Extensive right limb **pancreatic** inflammation noted with enhanced surrounding mesentery enveloping the pyloric outflow and duodenum, likely the cause of gastric stasis. An area of approximately 3.0 cm x 3.0 cm revealed an anechoic, undifferentiated region with suspected debris, consistent with pancreatic abscessation. Hyperechoic granulation bed noted around the structure, which appeared to be in the right base of the pancreas.

**INVOICE**

26619

**DATE**

10/25/21



**PATIENT**

TJ Waller

**ULTRASONOGRAPHIC FINDINGS**

- Extensive pancreatic necrosis and abscessation
- Gastroduodenitis with delayed outflow

**SPECIES**

Canine

**INTERPRETATION OF THE FINDINGS & FURTHER RECOMMENDATIONS**

Recommend return to exploratory surgery in this patient with expectations of debridement, liberation of adhesions, and drainage as well as culture and biopsies. Mild potential for underlying neoplasia. There is a possibility of penetrating foreign body in this patient that may not be visible, such as a toothpick or similar that may have passed through the gastric wall.

**BREED**

Jack Russell Terrier X

**SEX**

Male

**AGE**

12 Years

**WEIGHT**

15 Pounds

**INTERPRETED BY**

Eric Lindquist, DMV  
DABVP, Cert. IVUS

**IMAGING PERFORMED BY**

Harold Mike Beard

**HOSPITAL NAME**

West Prince AH

**REFERRING VET**

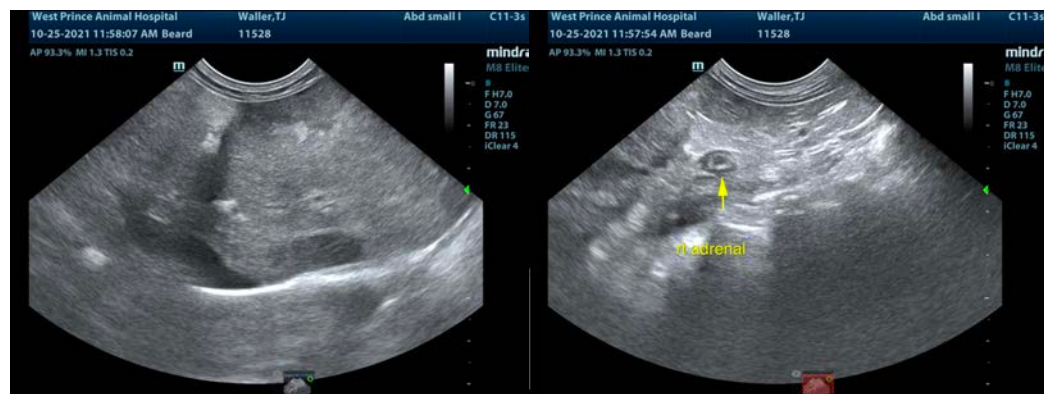
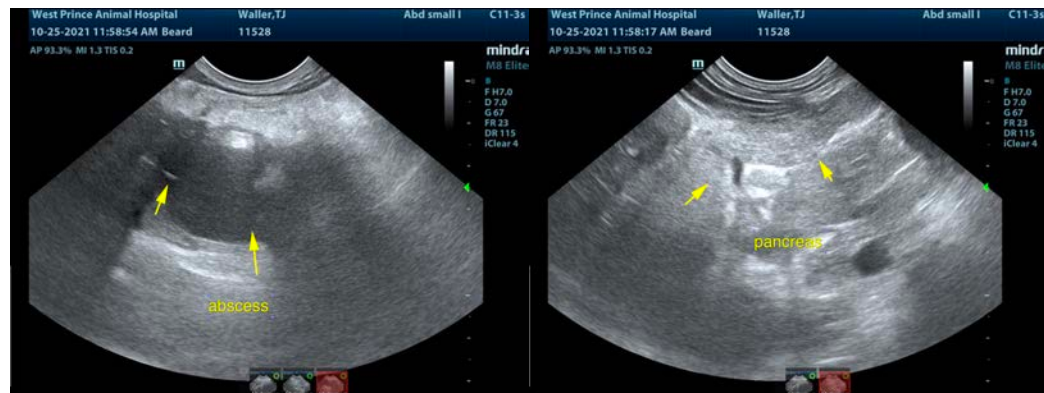
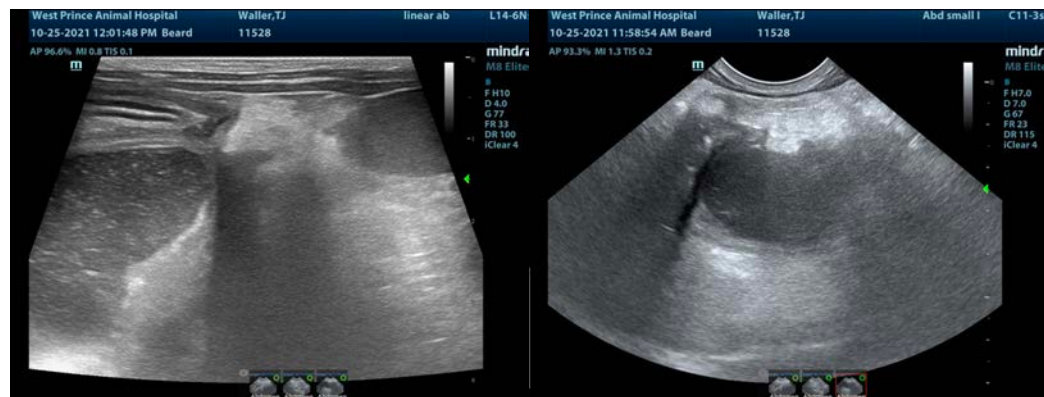
Dr. Mike Pallone

**INVOICE**

26619

**DATE**

10/25/21





**PATIENT**

TJ Waller

**SPECIES**

Canine

**BREED**

Jack Russell Terrier X

**SEX**

Male

**AGE**

12 Years

**WEIGHT**

15 Pounds

**INTERPRETED BY**

Eric Lindquist, DMV  
DABVP, Cert. IVUSS

**IMAGING PERFORMED BY**

Harold Mike Beard

**HOSPITAL NAME**

West Prince AH

**REFERRING VET**

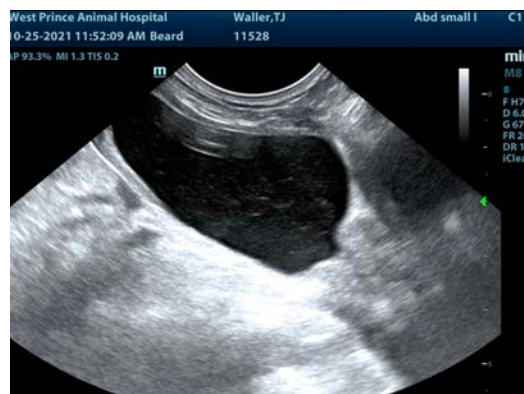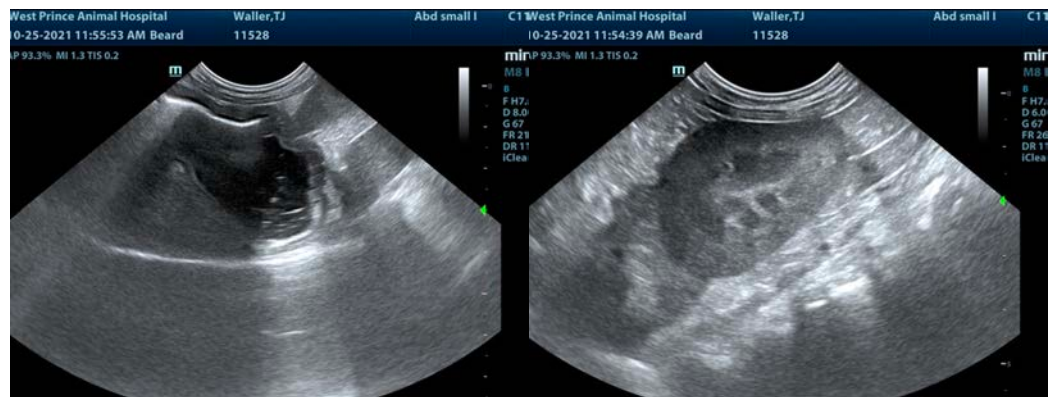
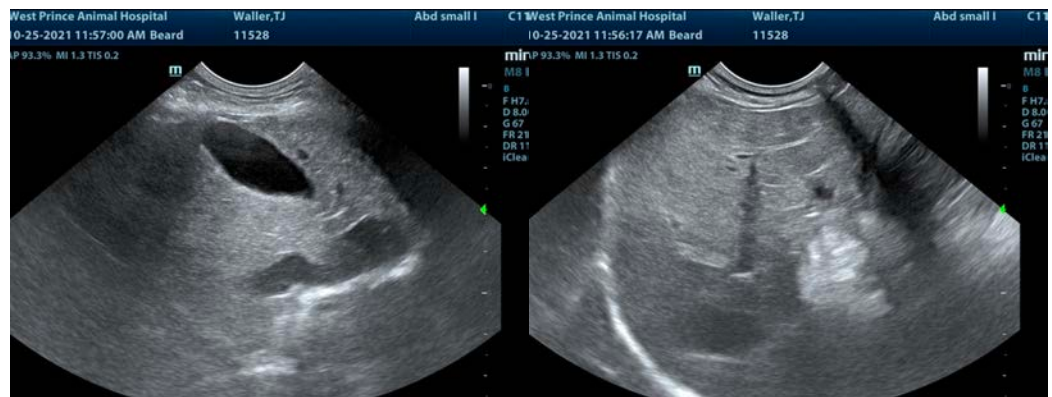
Dr. Mike Pallone

**INVOICE**

26619

**DATE**

10/25/21



The information and recommendations provided are based on the images presented by the referring veterinarian. No evaluation can be communicated regarding pathology that was not visible in the image/video clips provided.

Thank you for this referral. If the clinical or image interpretation does not parallel your findings or if I can be of any further assistance please contact me.

Eric Lindquist, DMV, DABVP, Cert. IVUSS, CEO of SonoPath.com  
[info@SonoPath.com](mailto:info@SonoPath.com)