



PATIENT

Rocky Katayama

PRESENTING CLINICAL SIGNS

Chronic intermittent diarrhea (vomiting/weight loss). Presented 10/22 abd. free fluid, albumin 1.5, now 1.4, on Hetastarch, Cerenia, famotadine, buprenex, clindamycin.

SPECIES

Canine

ULTRASONOGRAPHIC EXAMINATION OF THE ABDOMEN

Urinary System

BREED

Chihuahua

The **urinary bladder**, trigone, and pelvic urethra presented normal thicknesses and normal tone. The ureters were not visible which is normal. No uroliths or sediment were visualized and anechoic urine was present. No evidence of inflammatory or neoplastic changes were noted. Ureteral papillae were normal.

SEX

Intact Male

The prostate was mildly heterogeneous and mildly irregular and microcystic, measuring 2.6 cm, consistent with BPH.

AGE

7 Years

The **kidneys** revealed normal size and structure, corticomedullary definition and ratio for this age. The cortices presented largely uniform texture with normal echogenic relationship to liver and spleen. Medullary structure differed distinctly from the cortex and no evidence of pelvic dilation was present. The capsules were acceptably uniform without significant irregularities. The right kidney measured 3.6 cm. The left kidney measured 4.46 cm.

Adrenal Glands

WEIGHT

10.8 Pounds

Both **adrenal glands** were visualized and recognized as having normal shape, size, position and echogenicity for this breed. The phrenic vasculature, glandular echogenicity and detail were unremarkable. Capsule, cortex, and medullary definition were normal for this age patient. The right adrenal gland measured 1.5 cm x 0.48 cm at the caudal pole and 0.55 cm at the cranial pole. The left adrenal gland measured 1.62 cm x 0.34 cm at the caudal pole and 0.38 cm at the cranial pole.

INTERPRETED BY

Eric Lindquist, DMV
DABVP, Cert. IVUSS

Spleen

The **spleen** revealed a focal hypoechoic 1.0 cm nodule in the mid body.

IMAGING PERFORMED BY

Kelly Vazquez

Liver

The **liver** was slightly subnormal in size. Mild increased portal markings noted. The gallbladder was unremarkable.

HOSPITAL NAME

Westwood Regional

The portal vein revealed a thrombus measuring approximately 2.0 cm x 0.8 cm. Portal vein/vena cava ratio was normal. No evidence of shunting. The thrombus appeared to be partially occlusive. Mild regional inflammation noted associated with the portal vein.

REFERRING VET

Dr. Taylor McConnell

Pleural effusion was noted through the diaphragm as well as mild ascites.

Gastrointestinal

The **stomach** revealed some retention of ingesta. The small intestine and colon were unremarkable.

INVOICE

26622

Pancreas

The **pancreas** was heterogeneous with mixed echogenic changes. Low-grade inflammation is suspected.

DATE

10/25/21



PATIENT

Rocky Katayama

Free Abdomen

SPECIES

Canine

The testicles were imaged and found to be uniform. No evident pathology. The testicles measured 2.4 cm each.

Free fluid noted in the caudal abdomen. Reactive mesentery noted in the mid abdomen.

BREED

Chihuahua

ULTRASONOGRAPHIC FINDINGS

- Protein losing disease with portal vein thrombosis, ascites, and pleural effusion

SEX

Intact Male

If no significant proteinuria is present, then the protein loss is likely GI related. Antithrombin 3 loss is likely the cause of the hypercoagulable state. The free fluid in the abdomen could be justified by both low oncotic pressure as well as portal vein thrombus and prehepatic portal hypertension. Plasma transfusion is strongly recommended in this patient as well as full coagulation panel with D-dimers. Plavix therapy, repetitive plasma transfusions and hetastarch all indicated. Target albumin after therapy to 2.0 or greater. Recheck sonogram in 72 hours to assess the presence of the portal vein thrombus to ensure it is not increasing in size as well as the presence of effusion, which ideally would be resolved with increasing oncotic pressures. Very guarded prognosis. The patient is at risk for sudden death owing to pulmonary thromboembolic disease. Renal thrombosis may also be an issue in this patient.

AGE

7 Years

WEIGHT

10.8 Pounds

PLE Therapy

Part or all of this protocol may be considered based on your clinical impression of the patient:

INTERPRETED BY

Eric Lindquist, DMV
DABVP, Cert. IVUSS

OBJECTIVE: keep albumin levels > 2 g/dl, avoid thromboembolism and cavitory effusions, monitor concurrent PLN (Wheaton Terrier PLE/PLN) and liver disease:

Plasma 10 mL / kilogram IV over 4 hours

Or **Human albumin** 2 ml/kg/h over 10 hours. Total daily volume 20.l/kg/day

And Colloids/Hetastarch

10 to 20 mL per kilogram per day and dogs

10 to 15 mL per kilogram per day cats

(Can bolus first 1/3 of dose over 15 minutes)

& maintain on LRS maintenance otherwise.

Metronidazole (10-20 mg/kg po bid)

Famotidine 1 mg/kg Iv Im po dc Sid /bid

Sucralfate 0.5-1 g po tid dogs, 0.5 g bid cats in slurry Or **Misoprostol** 1-5 ug/kg po tid

Diet: Highly digestible high quality protein, low fiber, low fat diet (< 15% of dry matter). Hydrolyzed protein or novel protein. Purina HA or Royal Canine HP or similar.

Prednisone or prednisolone 2 mg/kg bid x 3-5 days then 2 mg/kg sid. **Chlorambucil** in refractive severe IBD/alimentary lymphoma cases (monitor cbc for rare bone marrow suppression) 4 mg/m² Q 24-48 hours.

Cobalamine (B12) 250-1500 ug/dog weekly x 6 weeks.

Calcium supplementation if necessary.

Aspirin 0.5-1 mg/kg/day or **Clopidrel** (Plavix) 1-5 mg/kg/day.

IMAGING PERFORMED BY

Kelly Vazquez

HOSPITAL NAME

Westwood Regional

REFERRING VET

Dr. Taylor McConnell

INVOICE

26622

For an additional charge, internal medicine consult can be utilized through SonoPath.com. You can select the internal medicine drop down at <http://spa.sonopath.com/>.

DATE

10/25/21



PATIENT

Rocky Katayama

One of the world's top internists & SonoPath associate Dr. Remo Lobetti BVSc, MMedVet, PhD, DECVIM can evaluate your case through SonoPath. <https://sonopath.com/resources/sonopath-services/internal-medicine-teleconsultation-services>

SPECIES

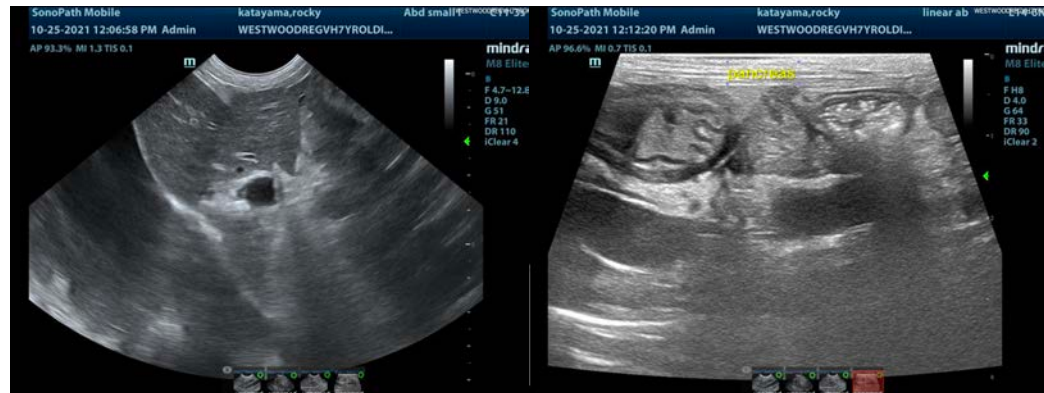
Canine

BREED

Chihuahua

SEX

Intact Male

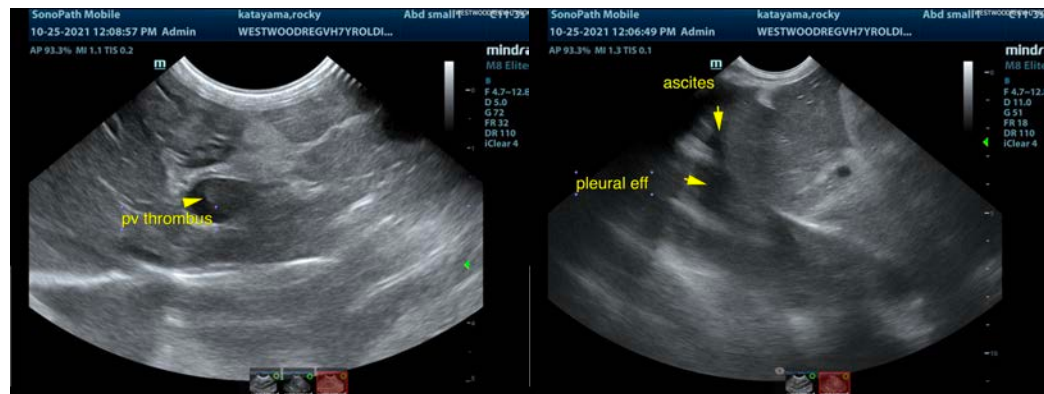


AGE

7 Years

WEIGHT

10.8 Pounds



INTERPRETED BY

Eric Lindquist, DMV
DABVP, Cert. IVUSS

IMAGING PERFORMED BY

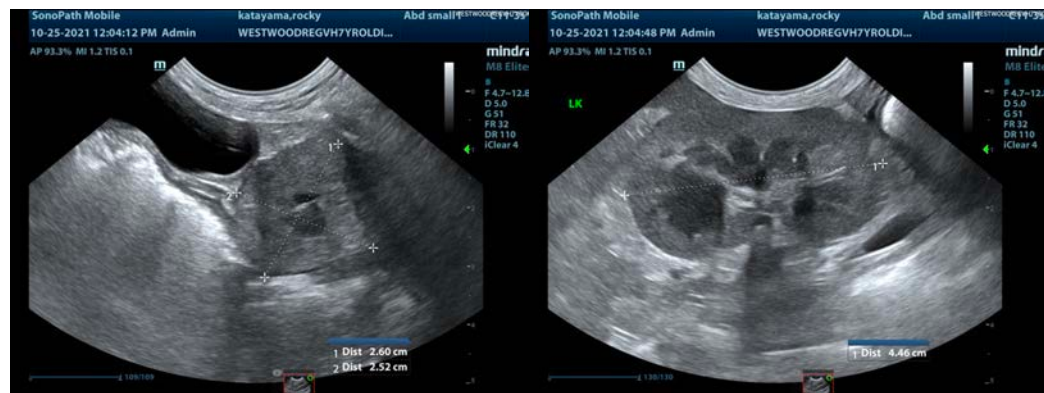
Kelly Vazquez

HOSPITAL NAME

Westwood Regional

REFERRING VET

Dr. Taylor McConnell



INVOICE

26622

DATE

10/25/21



PATIENT

Rocky Katayama

SPECIES

Canine

BREED

Chihuahua

SEX

Intact Male

AGE

7 Years

WEIGHT

10.8 Pounds

INTERPRETED BY

Eric Lindquist, DMV
DABVP, Cert. IVUSS

IMAGING PERFORMED BY

Kelly Vazquez

HOSPITAL NAME

Westwood Regional

REFERRING VET

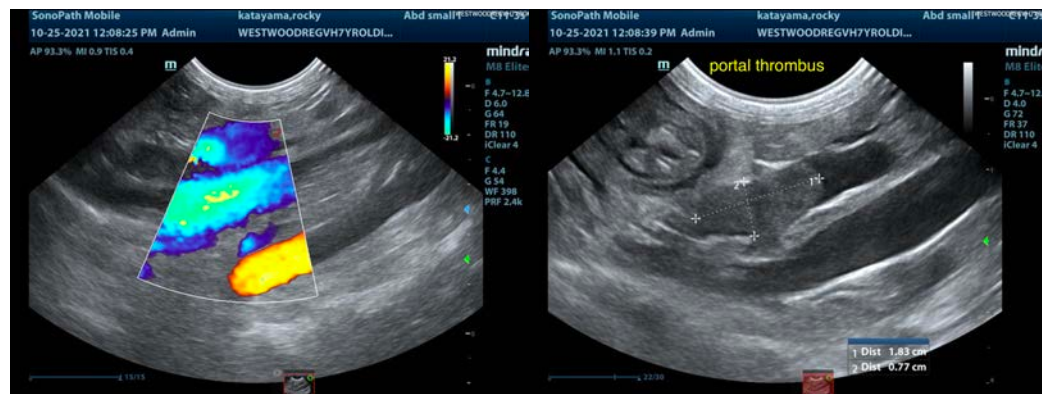
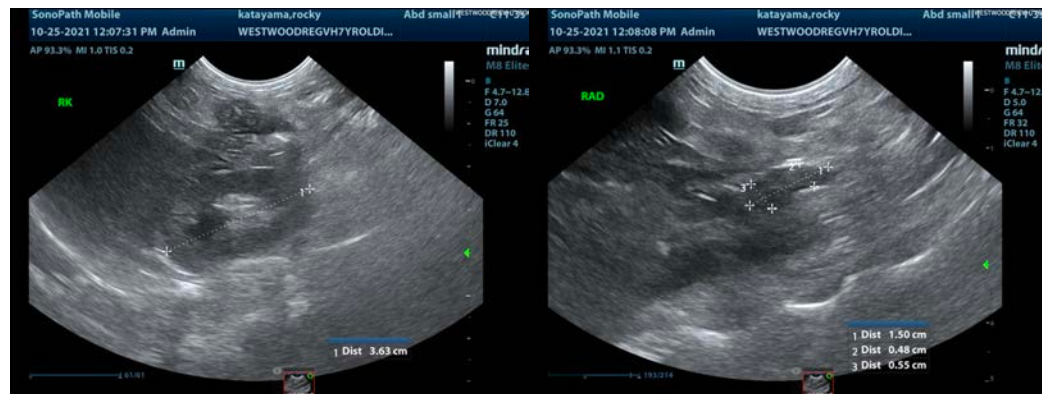
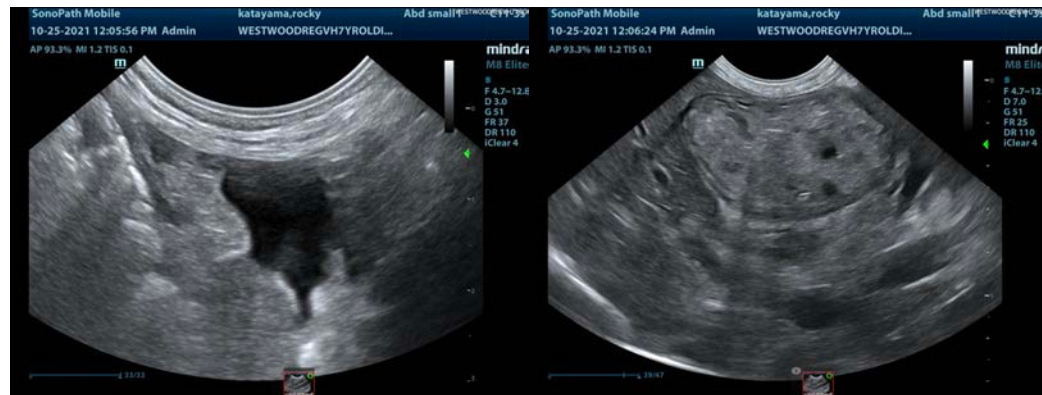
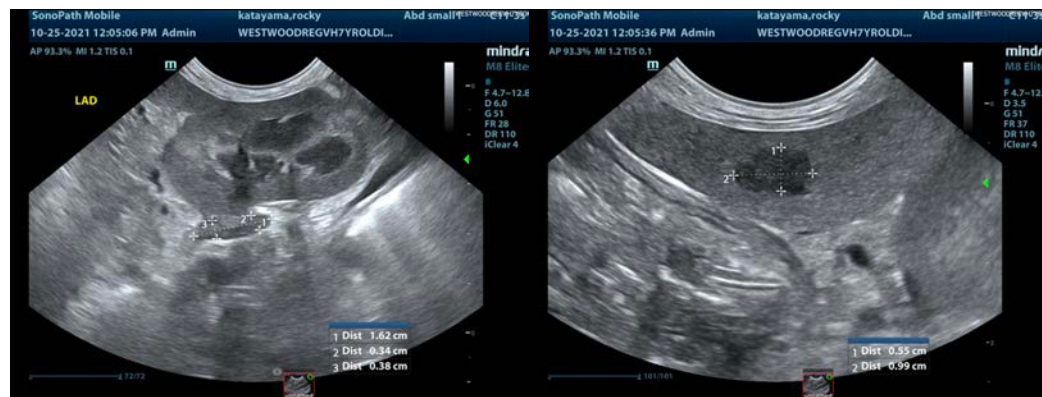
Dr. Taylor McConnell

INVOICE

26622

DATE

10/25/21





PATIENT

Rocky Katayama

SPECIES

Canine

BREED

Chihuahua

SEX

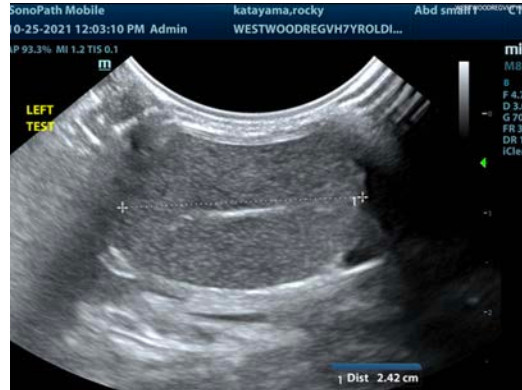Intact Male

AGE

7 Years

WEIGHT

10.8 Pounds



The information and recommendations provided are based on the images presented by the referring veterinarian. No evaluation can be communicated regarding pathology that was not visible in the image/video clips provided.

Thank you for this referral. If the clinical or image interpretation does not parallel your findings or if I can be of any further assistance please contact me.


Eric Lindquist, DMV, DABVP, Cert. IVUSS, CEO of SonoPath.com
info@SonoPath.com

INTERPRETED BY

Eric Lindquist, DMV
DABVP, Cert. IVUSS

IMAGING PERFORMED BY

Kelly Vazquez



The following is an applicable excerpt from the *Curbside Guide to Diagnosis & Treatment of Sonographic Disease* offered by SonoPath.com Lindquist, Frank, Lobetti, and Modler.

An essential quick guide for every general practitioner and sonographer.

<https://sonopath.com/products/curbside-guide-editing-due-release-12012015>

HOSPITAL NAME

Westwood Regional

Protein-Losing Enteropathy (PLE)

<http://www.sonopath.com/PLE>

REFERRING VET

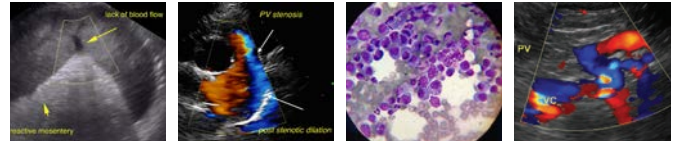
Dr. Taylor McConnell

INVOICE

26622

DATE

10/25/21



PATIENT

Rocky Katayama

SPECIES

Canine

BREED

Chihuahua

SEX

Intact Male

AGE

7 Years

WEIGHT

10.8 Pounds

INTERPRETED BY

Eric Lindquist, DMV
DABVP, Cert. IVUSS

IMAGING PERFORMED BY

Kelly Vazquez

HOSPITAL NAME

Westwood Regional

REFERRING VET

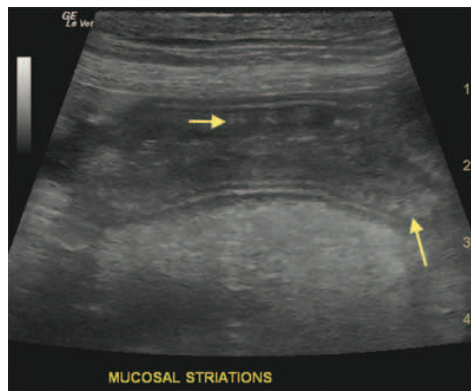
Dr. Taylor McConnell

INVOICE

26622

DATE

10/25/21



Long axis of the jejunum in a dog with protein losing enteropathy. Note the presence of multiple vertical hyperechoic mucosal striations (small arrow) - also described as “tiger stripe pattern” – pathognomonic for lacteal dilation. Groupings of striations creating a nebulous echogenic mucosal appearance as seen here can be referred to as “mucosal fogging” (large arrow).

Description: Protein-losing enteropathy (PLE) is characterized by conditions or disease processes that cause protein loss through the gastrointestinal (GI) mucosa. Clinical signs related to hypoalbuminemia will occur when albumin levels drop below 1.5 g/dl; a loss of oncotic pressure will ensue and precipitate ascites, thoracic effusion, and peripheral edema. Causes of PLE may include: inflammatory changes to the gastrointestinal mucosa or inflammatory bowel disease (IBD); food allergies resulting in IBD; ulcerative disease; granulomatous disease (fungal disease); immunoproliferative enteropathy; neoplasia (lymphoma being most common); and lymphangiectasia. Intussusception and parasitic infection can result in PLE in young animals. Lymphangiectasia typically occurs as a secondary disease process, with lymphatic duct dilation secondary to underlying inflammation or neoplastic cells. Primary lymphangiectasia is a congenital disease typically found in young dogs, especially Basenjis and Norwegian Lundehunds. Some breeds, such as Wheaten Terriers, Rottweilers, German Shepherds, Norwegian Lundehunds, Yorkshire Terriers, and Basenjis, are more predisposed to PLE than others. Heritability has been demonstrated in Wheaten Terriers and Basenjis. Yorkshire Terriers are ten times more likely to develop IBD and nine times more likely to suffer hypocalcemia and hypomagnesemia with IBD.

Clinical Signs: Canine patients are typically the most susceptible to PLE (cats are less commonly affected), and will often display anorexia, weight loss, vomiting, and diarrhea. Interestingly, some patients may present with pleural or peritoneal effusion secondary to severe hypoalbuminemia, but may not exhibit primary signs of gastrointestinal disease, such as diarrhea or vomiting. Ascites and/or pleural effusion or subcutaneous edema can occur subsequent to hypoalbuminemia. Signs of thromboembolic disease, such as dyspnea due to pulmonary thromboembolism, can occur secondary to a lack of anti-thrombin III (AT-III).

Diagnostics: Typical laboratory abnormalities include hypoalbuminemia and/or hypoglobulinemia. If globulin levels are within normal limits, they are usually at the lower end of normal. Lymphocytes and cholesterol may be decreased, especially in cases of lymphangiectasia, due to a loss of lymphocytes and cholesterol in the lymph. A regenerative anemia can occur due to blood loss, although anemia due to iron deficiency may ensue in chronic cases. Hypocalcemia may transpire secondary to albumin loss (pseudohypocalcemia) or the calcium can be truly subnormal as a result of hypovitaminosis D due to PLE. Hypomagnesemia is common as well. Severe PLE can lead to a decline in AT-III levels, which can then result in a prothrombotic state. Thus, AT-III levels should be measured in severely hypoalbuminemic patients.



PATIENT

Rocky Katayama

SPECIES

Canine

BREED

Chihuahua

SEX

Intact Male

AGE

7 Years

WEIGHT

10.8 Pounds

INTERPRETED BY

Eric Lindquist, DMV
DABVP, Cert. IVUSS

IMAGING PERFORMED BY

Kelly Vazquez

HOSPITAL NAME

Westwood Regional

REFERRING VET

Dr. Taylor McConnell

INVOICE

26622

DATE

10/25/21

The clinician should consider ultrasound as a non-invasive method to help determine the cause of hypoalbuminemia. Ultrasound can be utilized to evaluate the GI tract, kidneys, liver, and adrenals. It will also help identify the potential sources of albumin loss (GI or renal), whether there is a lack of albumin production (liver), or if the condition is linked to hypoadrenocorticism (adrenal), which may also be associated with hypoalbuminemia (the ultrasound may reveal isoechoic flattened adrenals < 0.32 cm). These findings should also be considered in combination with a bile acid test to rule out hepatic insufficiency, a urine protein-creatinine (UPC) ratio to assess for urine protein loss, and a fecal Alpha 1-Proteinase Inhibitor test to assess for GI protein loss. An ACTH stimulation test may be indicated if hypoadrenocorticism is clinically suspected.

One should measure serum TLI, folate, and B₁₂ levels to evaluate for evidence of small intestinal bacteria overgrowth or to establish the presence of small intestinal disease due to cobalamin loss and elevated folate levels. The TLI will also confirm exocrine pancreatic insufficiency as a differential diagnosis for diarrhea and weight loss. A fecal exam should be submitted to rule out parasites.

Sonographic abnormalities may include thickening of the intestinal wall and mucosal striations. One study has shown that the presence of mucosal striations has a sensitivity of 75% and specificity of 96% in dogs that have PLE; however, mucosal stippling appears to be a non-specific finding. Administration of corn oil (0.5-1 ml/kg) one hour prior to the ultrasound will enhance the visibility of mucosal striations in the small intestine during the sonogram. Solitary masses or focal intestinal thickening and lymphadenopathy can be evaluated, and sometimes fine needle aspiration (FNA) of a mass or enlarged lymph node may yield a diagnosis, especially in cases of lymphoma. If the results are inconclusive, then surgical biopsy should ideally be guided by an intraoperative ultrasound, especially if the lesions are focal. An ultrasound-guided core biopsy would only be considered if a bowel mass was large enough to biopsy the tissue without sampling through to the lumen, which could result in the leakage of bowel contents and subsequent peritonitis.

A definitive diagnosis of PLE can only be obtained via histopathology. This is preferably achieved with a surgically obtained full-thickness biopsy or an endoscopic-guided biopsy performed the morning after the patient has eaten a high-fat meal so that the lacteals are dilated and lymphangiectasia can be adequately diagnosed. There may be some increased risk to obtaining full-thickness biopsies in patients with severe hypoalbuminemia due to decreased healing and increased risk of dehiscence. Thus, the cost-benefit of full-thickness biopsy versus an endoscopic biopsy should be considered on a case-by-case basis.

Endoscopy should be performed using two approaches—via the stomach to biopsy the duodenum, and via the colon to biopsy the ileum—thereby maximizing the information one can yield from biopsy. Yet, transmural disease, such as lymphoma affecting the muscularis and submucosa, is not typically assessed very readily via endoscopy. A sonogram of the GI tract can help determine whether the pathology is luminal and thus available for sampling through endoscopy, or mural or serosal and therefore necessitating surgical biopsy.



PATIENT

Rocky Katayama

Treatment: Therapy for PLE is dependent on the underlying disease process. Given that a significant fraction of PLE cases are the result of a food allergy causing IBD, whether or not lymphangiectasia is concurrent, dietary trials with a hydrolyzed protein diet or a novel protein diet are a good choice, especially if IBD has been confirmed on biopsy. If, however, severe lymphangiectasia has been diagnosed, a fat-restricted diet is preferred. In some cases, a specially formulated homemade diet may be most appropriate and should be determined in consultation with a veterinary nutritionist.

SPECIES

Canine

BREED

Chihuahua

Empirical broad-spectrum deworming should be pursued using fenbendazole at 50 mg/kg PO Q24hr for 5 days; repeat in 2 weeks. Treating for small intestinal bacterial overgrowth can also be considered, especially if there is evidence of elevated folate levels. In such cases, one should administer metronidazole (15mg/kg PO BID) or tylosin (10-20 mg/kg PO BID).

SEX

Intact Male

If IBD has been confirmed, immunosuppressive therapy with prednisone should be administered at 2 mg/kg/day for a 2-4 week induction period. Subsequently, the patient should be weaned slowly to 1 mg/kg/day, and eventually dosed every other day. In large and giant breed dogs, dosing per body surface area is recommended to avoid overdosing and the precipitation of severe side effects; the recommended dose is 30-40mg/m² for large breed dogs. Concurrently administering azathioprine (Immunuran) (2mg/kg PO Q24hr for 10 days, then 1 mg/kg PO Q24hr, and eventually every other day on alternate days to the prednisone; note that alternative protocols exist at a dose of 1-2 mg/kg PO Q24hr) can be considered if the patient is nonresponsive to prednisone alone. Cyclosporine is an alternative immunosuppressant; however, it can be quite expensive, especially in large dog breeds, and should be dosed at 3-5mg/kg PO Q12-24hr to start. Blood cyclosporine levels should be evaluated 7 days after initiating treatment; one can adjust the dosage at that point if need be. Concomitant use of ketoconazole (2.5-5 mg/kg PO BID) inhibits some metabolism of cyclosporine, leading to higher blood concentrations of the latter without increasing the overall dose (or cost to the owner). Typically, the dose of cyclosporine can be cut in half when dosed in conjunction with ketoconazole.

AGE

7 Years

WEIGHT

10.8 Pounds

INTERPRETED BY

Eric Lindquist, DMV
DABVP, Cert. IVUSS

IMAGING PERFORMED BY

Kelly Vazquez

HOSPITAL NAME

Westwood Regional

In the presence of effusions, colloid therapy may be beneficial and can include hetastarch at 10-20 ml/kg, which can be given as an initial bolus and the rest over 4-6 hours, or, alternatively, over a 24-hour period as a CRI (1-2 ml/kg/hr; do not to exceed 20 ml/kg/24 hours). Fresh frozen plasma is typically ineffective at raising albumin levels; however, in an emergency situation, one can give it at 10-20 ml/kg IV over 3-4 hours. Human albumin is more effective at raising serum albumin levels; it also helps provide oncotic support during diagnostic procedures, such as obtaining biopsies, for example. Repeat administration can result in anaphylactic reactions, but that outcome is rare.

REFERRING VET

Dr. Taylor McConnell

Diuretics can be utilized in the face of severe ascites, but they are not particularly effective. Spironolactone is preferred (2 mg/kg PO BID) and low-dose lasix can be added if necessary (1-2 mg/kg PO BID). Abdominocentesis should only be pursued if the patient is experiencing discomfort due to exaggerated abdominal distention. Excessive drainage will cause further depletion of the protein supply, which runs counter to restoring balanced protein levels and can also often result in rapid fluid shifts, leading to acute hypovolemia and hypotension.

INVOICE

26622

Anticoagulant therapy is suggested in the face of severe hypoalbuminemia (less than 1.5 g/dl). Therapeutic options include clodiprogel (2 mg/kg PO Q24hr) or aspirin (1 mg/kg PO Q24hr) in the hopes

DATE

10/25/21



PATIENT

Rocky Katayama

of preventing a potential thromboembolic episode, which can be the source of sudden death in cases of significant hypoalbuminemia in which there has been AT-III loss.

SPECIES

Canine

Patients should be supplemented with cobalamin (vitamin B₁₂) at 25-50 ug/kg once weekly for 4-6 weeks, then once every other week to once a month as needed.

BREED

Chihuahua

If ionized calcium levels are decreased with corresponding clinical signs of hypocalcemia, calcium levels should be corrected with parenteral calcium gluconate (50-150 mg/kg IV over 12-24 hours). Long-term supplementation may be necessary for dogs suffering from concurrent hypovitaminosis D, secondary to IBD; this would entail administering calcitriol as well as oral calcium (calcium carbonate). In the face of hypomagnesemia, magnesium sulphate (1mEq/kg/day IV) or magnesium oxide 10-20 mg/kg PO BID (milk of magnesia) may be utilized for magnesium supplementation; however, the latter may cause diarrhea.

SEX

Intact Male

AGE

7 Years

Conclusion: PLE can be a challenging disease syndrome to treat given the multiple possible underlying etiologies and the severity of clinical sequelae characteristic of severe hypoalbuminemia. It is important, if possible, to obtain a definitive diagnosis, and addressing all potential comorbid issues is crucial to the success of its management. Dietary therapy is an important factor in long-term treatment as is attending to the underlying cause of the disease.

WEIGHT

10.8 Pounds

INTERPRETED BY

Eric Lindquist, DMV
DABVP, Cert. IVUSS

IMAGING PERFORMED BY

Kelly Vazquez

HOSPITAL NAME

Westwood Regional

REFERRING VET

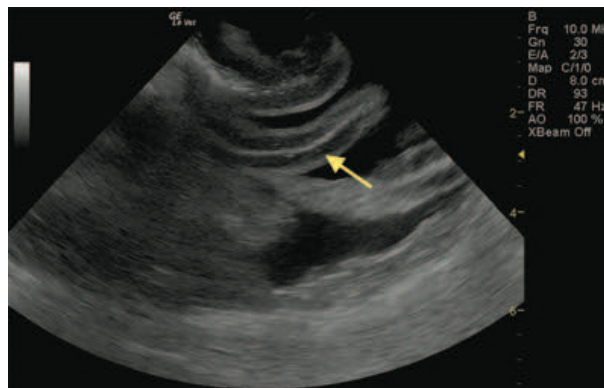
Dr. Taylor McConnell

INVOICE

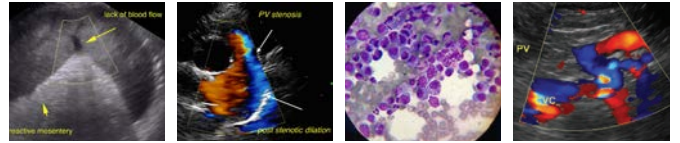
26622

DATE

10/25/21



Small intestine of a dog with protein losing enteropathy. A moderate amount of anechoic peritoneal effusion is present as sequel to the hypoalbuminemia (albumin < 1.5 g/dl). Note the generalized increased mucosal echogenicity and presence of multiple echogenic foci (arrow) throughout the small intestinal mucosa compatible with dilated lacteals. When these foci are seen with standard scanning frequency (8 mHz), then high resolution linear probe should be employed for further investigation of the mucosae and GI wall similar to the title image or the following one.



PATIENT

Rocky Katayama

SPECIES

Canine

BREED

Chihuahua

SEX

Intact Male

AGE

7 Years

WEIGHT

10.8 Pounds

INTERPRETED BY

Eric Lindquist, DMV
DABVP, Cert. IVUSS

IMAGING PERFORMED BY

Kelly Vazquez

HOSPITAL NAME

Westwood Regional

REFERRING VET

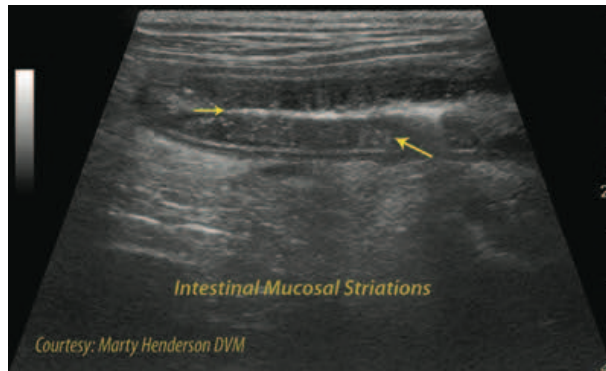
Dr. Taylor McConnell

INVOICE

26622

DATE

10/25/21



Long axis of the jejunum in a dog with protein losing enteropathy. Note the multiple vertical hyperechoic mucosal striations (long arrow) pathognomonic for lacteal dilation. Also note the presence of a hyperechoic line (small arrow) within the mucosa paralleling the submucosa in the small intestine consistent with a dilated draining lymph vessel. A small amount of anechoic effusion is seen.

References:

Dossin O, Lavoué R. Protein-losing enteropathies in dogs. *Vet Clin North Am Small Anim Pract* 2011;41(2):399-418.

Gaschen L, Kircher P, Stüssi A, et al. Comparison of ultrasonographic findings with clinical activity index (CIBIDAI) and diagnosis in dogs with chronic enteropathies. *Vet Radiol Ultrasound* 2008;49(1):56-64.

Gow AGG, Else R, Evans H, et al. Hypovitaminosis D in dogs with inflammatory bowel disease and hypoalbuminemia. *J Small Anim Pract* 2011;52(8):411-18.

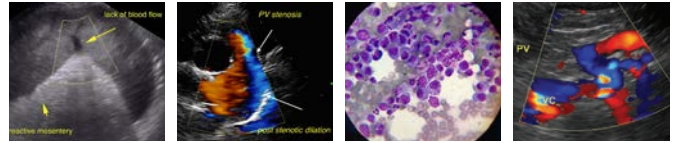
Hill SL. Diagnosis of protein-losing enteropathies. Proceedings from the American College of Veterinary Internal Medicine, Seattle, WA, June 4-7, 2013.

Kimmel SE, Waddell LS, Michel KE. Hypomagnesemia and hypocalcemia associated with protein losing enteropathy in Yorkshire terriers: five cases (1992-1998). *J Am Vet Med Assoc* 2000;217(5):703-6.

Lindquist E, Casey D, Frank J. Intraoperative ultrasound for precise biopsy and resection of transabdominally detected intestinal lesions in 3 cats. Proceedings from the European College of Veterinary Internal Medicine, Porto, Portugal, September 8-10, 2009.

Littier R. Protein losing enteropathy: causes, clinical signs and diagnosis. *In Pract* 2013;35(7):373-81.

Littman MP, Dambach DM, Vaden SL, Giger U. Familial protein-losing enteropathy and protein-losing nephropathy in Soft Coated Wheaten Terriers: 222 cases (1983-1997). *J Vet Intern Med* 2000;14(1):68-80.



PATIENT

Rocky Katayama

Lobetti R, Lindquist E, Frank J, et al. Adrenal gland ultrasonography in dogs with hypoadrenocorticism. Proceedings from the American College of Veterinary Internal Medicine, Seattle, WA, June 4-7, 2013.

SPECIES

Canine

Neiger R. Protein-losing enteropathy (PLE) in dogs. Proceedings from the World Small Animal Veterinary Association Congress, Auckland, New Zealand, March 6-9, 2013.

BREED

Chihuahua

Pollard RE, Johnson EG, Pesavento PA, et al. Effects of corn oil administered orally on conspicuity of ultrasonographic small intestinal lesions in dogs with lymphangiectasia. *Vet Radiol Ultrasound* 2013;54(4):390-97.

SEX

Intact Male

Rodríguez-Alarcón C, Beristáin-Ruiz D, Pérez-Casio F, et al. Protein-losing enteropathy in a dog with lymphangiectasia, lymphoplasmacytic enteritis and pancreatic exocrine insufficiency. *Vet Q* 2012;32(3-4):193-97.

AGE

7 Years

Valerie J Parker, Lisa M Freeman. Nutritional management of protein-losing nephropathy in dogs. *Compend Contin Educ Pract Vet* 2012;34(7):1-5.

Wenger M, Mueller C, Kook PH, Reusch CE. Ultrasonographic evaluation of adrenal glands in dogs with primary hypoadrenocorticism or mimicking diseases. *Vet Rec* 2010;167(6):207-10.

WEIGHT

10.8 Pounds

Willard MD. Protein-losing enteropathies: not what you might expect. Proceedings from the American College of Veterinary Internal Medicine, Seattle, WA, June 4-7, 2013.

INTERPRETED BY

Eric Lindquist, DMV
DABVP, Cert. IVUSS

**IMAGING
PERFORMED BY**

Kelly Vazquez

HOSPITAL NAME

Westwood Regional

REFERRING VET

Dr. Taylor McConnell

INVOICE

26622

DATE

10/25/21