



PATIENT

Zeus Comerford

PRESENTING CLINICAL SIGNS

Mast cell tumor removed from Right hip on 5/12/21. Staging. No health concerns.

SPECIES

Canine

ULTRASONOGRAPHIC EXAMINATION OF THE ABDOMEN

Urinary System

The **urinary bladder**, trigone, and pelvic urethra presented normal thicknesses and normal tone. The ureters were not visible which is normal. No uroliths or sediment were visualized and anechoic urine was present. No evidence of inflammatory or neoplastic changes were noted. Ureteral papillae were normal. The pelvic urethra was imaged 2.0 cm beyond the cystourethral junction. The residual prostate measured 6.0 mm.

BREED

Pit Bull

SEX

Neutered Male

The **kidneys** revealed largely normal size and structure, corticomedullary definition and ratio (cortex 1/3 of medulla) were essentially maintained with some age-related loss of curvilinear patterns regarding the capsule and C/M junction. The cortices presented largely uniform texture with some increased echogenicity expected for his age patient. Medullary structure differed distinctly from that of the cortex and no evidence of pelvic dilation was present. The left kidney measured 5.84 cm. The right kidney measured 5.74 cm.

AGE

9 Years 4 Months

Adrenal Glands

Both **adrenal glands** were visualized and recognized as having normal shape, size, position and echogenicity for this breed. The phrenic vasculature, glandular echogenicity and detail were unremarkable. Capsule, cortex, and medullary definition were normal for this age patient. The right adrenal gland measured 0.47 cm at the cranial pole and 0.46 cm at the caudal pole. The left adrenal gland measured 0.45 cm at the cranial pole and 0.53 cm at the caudal pole.

WEIGHT

47 Pounds

INTERPRETED BY

Eric Lindquist, DMV
DABVP, Cert. IVUSS

Spleen

The **spleen** presented minor heterogeneous parenchymal changes without disrupted architecture. Relatively normal size to slightly swollen. Given the patient history, FNA would be ideal or monitoring. However, this is most consistent from a sonographic standpoint with benign hyperplasia or reactive spleen.

IMAGING PERFORMED BY

Dr. Whitcraft

Liver

The **liver** images from right and left intercostal as well as subcostal views revealed subjectively normal liver size, contour, and structure. Some age-related parenchymal remodeling was noted but likely not clinically significant at this time. Vascular and biliary tracts were of normal volume and no evidence of congestion was noted. The gallbladder presented some dependent debris with essentially normal contour. The cystic and common bile ducts were normal. No overt evidence of active inflammatory, infiltrative or regenerative pathology was noted but should be paired with current or past LE elevations regarding any clinical significance to this presentation. The hepatic lymph nodes were unremarkable.

HOSPITAL NAME

Craig Road AH

REFERRING VET

Dr. Whitcraft

Gastrointestinal

INVOICE

26612

Examination of the **gastrointestinal tract** revealed a stomach and intestine free of stasis, of normal wall thickness, acceptable curvilinear mural detail, and peristaltic activity. Small and large intestine demonstrated normal luminal chyme and stool consistency respectively. No obstructive or overt infiltrative disease was noted. No associated abnormal lymphatic activity was noted.

DATE

10/23/21



PATIENT

Zeus Comerford

SPECIES

Canine

BREED

Pit Bull

SEX

Neutered Male

AGE

9 Years 4 Months

WEIGHT

47 Pounds

INTERPRETED BY

Eric Lindquist, DMV
DABVP, Cert. IVUSS

IMAGING PERFORMED BY

Dr. Whitcraft

HOSPITAL NAME

Craig Road AH

REFERRING VET

Dr. Whitcraft

INVOICE

26612

DATE

10/23/21

Pancreas

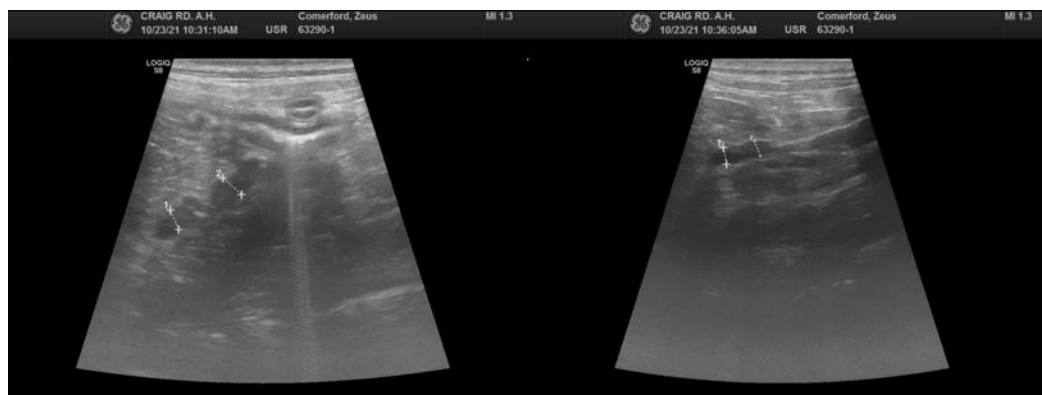
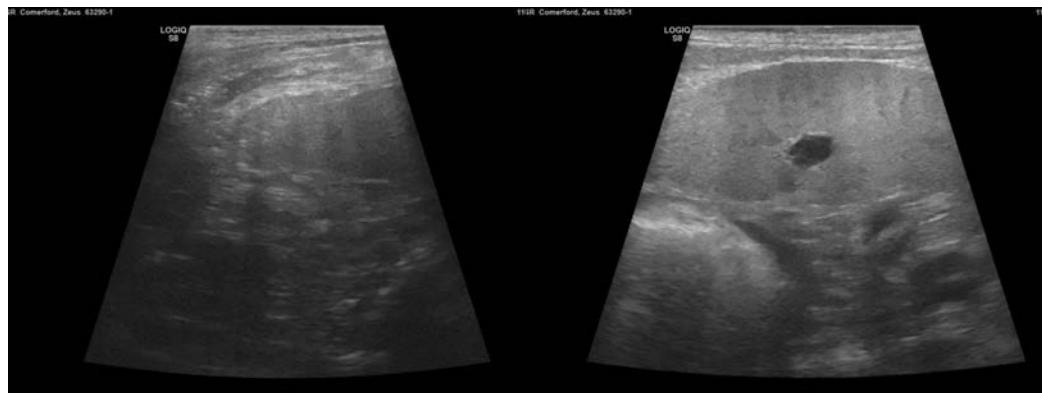
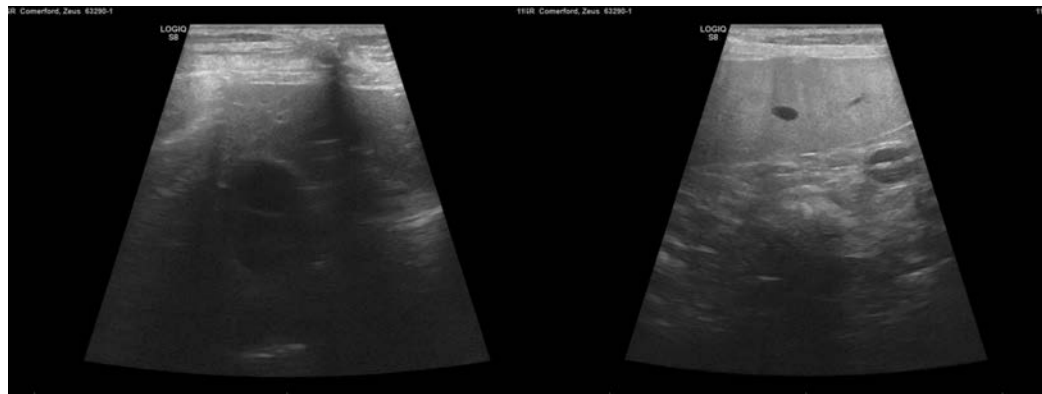
The base and limbs of the **pancreas** were observed to be largely isoechoic to surrounding omental fat. Pancreatic duct and capsular contour were acceptably normal and parenchyma respected normal curvilinear patterns. No overt evidence of active inflammatory or neoplastic disease was noted.

ULTRASONOGRAPHIC FINDINGS

- Minor heterogeneous spleen – likely benign
- Unremarkable abdomen otherwise

INTERPRETATION OF THE FINDINGS & FURTHER RECOMMENDATIONS

Given the patient history, screening FNA of the spleen recommended.





PATIENT

Zeus Comerford

SPECIES

Canine

BREED

Pit Bull

SEX

Neutered Male

AGE

9 Years 4 Months

WEIGHT

47 Pounds

INTERPRETED BY

Eric Lindquist, DMV
DABVP, Cert. IVUSS

**IMAGING
PERFORMED BY**

Dr. Whitcraft

HOSPITAL NAME

Craig Road AH

REFERRING VET

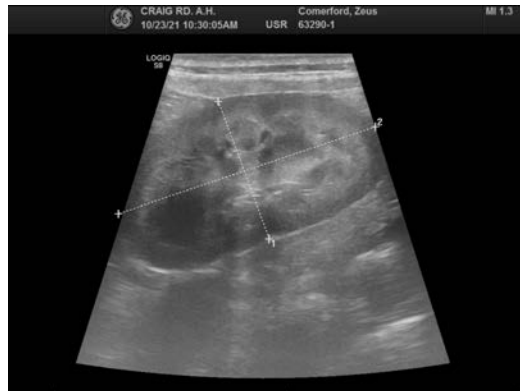Dr. Whitcraft

INVOICE

26612

DATE

10/23/21



The information and recommendations provided are based on the images presented by the referring veterinarian. No evaluation can be communicated regarding pathology that was not visible in the image/video clips provided.

Thank you for this referral. If the clinical or image interpretation does not parallel your findings or if I can be of any further assistance please contact me.

Eric Lindquist, DMV, DABVP, Cert. IVUSS, CEO of SonoPath.com
info@SonoPath.com