

PATIENT

Bella Abecassis

SPECIES

Canine

BREED

Labradoodle

SEX

Spayed Female

AGE

4 Years 11 Months

WEIGHT

59.2 Pounds

INTERPRETED BY

Eric Lindquist, DMV
DABVP, Cert. IVUSS

IMAGING PERFORMED BY

Michaleen

HOSPITAL NAME

DPC Veterinary
Hospital

REFERRING VET

Dr. Loduca

INVOICE

17868

DATE

10/21/22

PRESENTING CLINICAL SIGNS

History: FOREIGN BODY

LIMITED ULTRASONOGRAPHIC EXAMINATION

The **stomach** was empty in this patient, as was the upper duodenum. Soft stool and fluid filled colon were noted

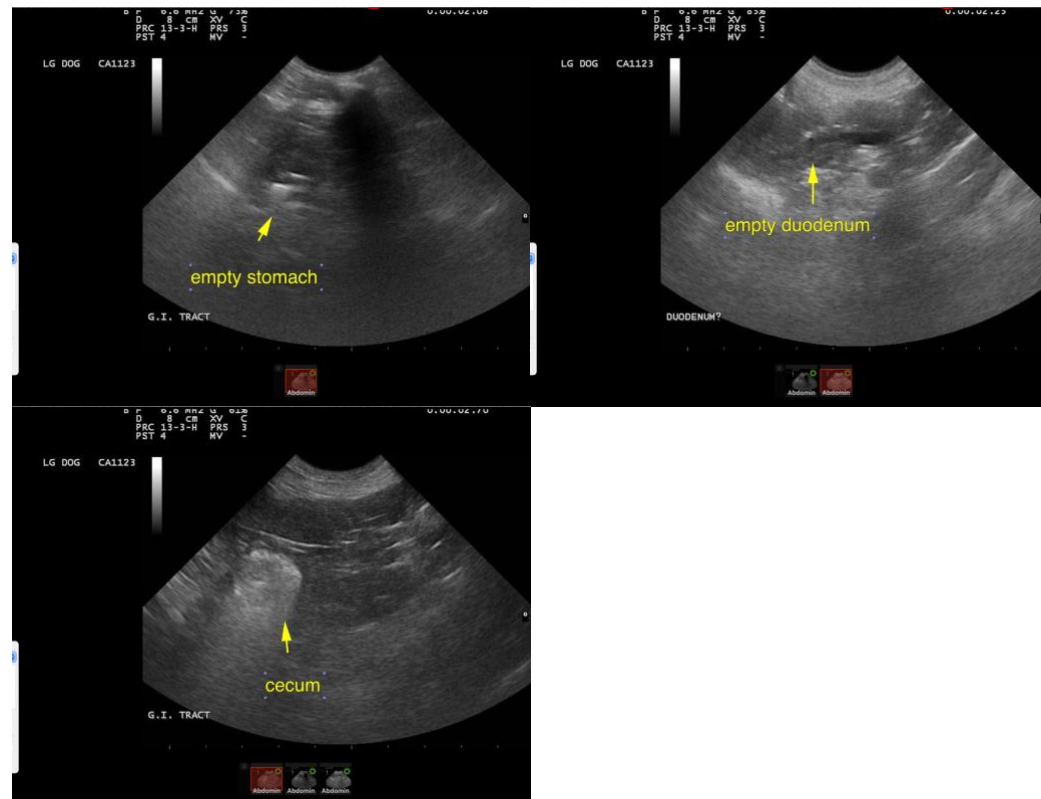
The visible **pancreas** was unremarkable.

ULTRASONOGRAPHIC FINDINGS

- Fluid filled cecum and colon

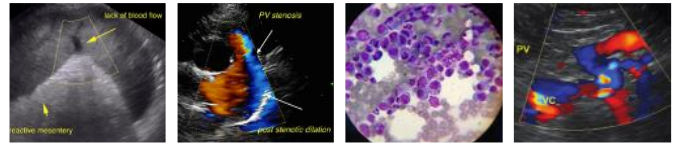
INTERPRETATION OF THE FINDINGS & FURTHER RECOMMENDATIONS

Supportive medical management is recommended. No evidence of foreign bodies.



The information and recommendations provided are based on the images presented by the referring veterinarian. No evaluation can be communicated regarding pathology that was not visible in the image/video clips provided.

Thank you for this referral. If the clinical or image interpretation does not parallel your findings or if I can be of any further assistance please contact me.



PATIENT

Eric Lindquist, DMV, DABVP, Cert. IVUSS, CEO of SonoPath.com
info@SonoPath.com

Bella Abecassis

SPECIES

Canine

BREED

Labradoodle

SEX

Spayed Female

AGE

4 Years 11 Months

WEIGHT

59.2 Pounds

INTERPRETED BY

Eric Lindquist, DMV
DABVP, Cert. IVUSS

**IMAGING
PERFORMED BY**

Michaleen

HOSPITAL NAME

DPC Veterinary
Hospital

REFERRING VET

Dr. Loduca

INVOICE

17868

DATE

10/21/22