

**DATE PRESENTING CLINICAL SIGNS**

10/22/21 History: Pet is actively depressed.

PATIENT

Current Medications: 9/20/2021: Temaril P Give 2 tablet by mouth every 12 hours for 4 days, then reduce to 1 tablet by mouth every 12 hours. Qty: 25.

Smokey Isbell

Lab Results: BUN: 63, Creat: 1.9, Magnesium: 2.7, Urine Specific Gravity: 1.011, Cholesterol: 414, Triglyceride: 1133, ALT: 156, AST: 73.

SPECIES

Radiographs: Attached separately.

Canine

Date of Previous IntraPet Ultrasound: No previous IntraPet scans.

Sedation: Not needed.

Stat Report: Not requested.

BREED**ULTRASONOGRAPHIC EXAMINATION OF THE ABDOMEN**

Shetland Sheepdog

Urinary System**SEX**The **urinary bladder**, trigone, and pelvic urethra presented normal thicknesses and normal tone. The ureters were not visible which is normal. No uroliths or sediment were visualized and anechoic urine was present. No evidence of inflammatory or neoplastic changes were noted. Ureteral papillae were normal.

Neutered Male

AGE

The pelvic urethra was imaged 2.0 cm beyond the cystourethral junction. The residual prostate was uniform, measuring 1.14 cm.

2/13/2007

WEIGHT

23 Pounds

The **kidneys** revealed largely normal size and structure, corticomedullary definition and ratio (cortex 1/3 of medulla) were essentially maintained with some moderate age-related loss of curvilinear patterns regarding the capsule and C/M junction. The cortices presented largely uniform texture with some increased echogenicity expected for his age patient. Medullary structure differed distinctly from that of the cortex and no evidence of pelvic dilation was present. Slight mineralization was noted in the Kidneys. The left kidney measured 4.34 cm. The right kidney measured 4.34 cm.**INTERPRETED BY**Eric Lindquist, DMV
DABVP, Cert. IVUSS**Adrenal Glands**Both **adrenal glands** were visualized and recognized as having normal shape, size, position and echogenicity for this breed. The phrenic vasculature, glandular echogenicity and detail were unremarkable. Capsule, cortex, and medullary definition were normal for this age patient. The right adrenal gland measured 1.95 cm x 0.64 cm at the caudal pole and 0.57 cm at the cranial pole. The left adrenal gland measured 2.02 cm x 0.6 cm at the caudal pole and 0.56 cm at the cranial pole.**HOSPITAL NAME**

Bel Air VH

REFERRING VET

Dr. Schmidt

SpleenThe **spleen** was slightly enlarged with uniform parenchyma, likely reactive state. No evidence of masses or suspicion of neoplasia.**INVOICE**

13994

LiverExam of the cranial abdomen demonstrated excessive **liver** size, swollen contour, with conserved uniform architecture. Parenchymal echogenicity was diffusely isoechoic to the spleen and falciform fat. This type of liver presentation typically is associated with slow and gradual SAP elevations with low-grade ALT rise. USG-FNA sampling is encouraged if more aggressive LE profiles are present such as ALT > 200 or rapid rise in SAP. These presentations are usually reactive hepatopathies owing to other disease processes either endocrine (Diabetes, Hypothyroidism, Cushing's disease), "antigen surveillance" from the gut/pancreas, or idiopathic breed predisposed progressions. This is a mild change. The gallbladder was overdistended and

rounded with striating bile, consistent with emerging mucocele. No evidence of peripheral inflammation noted.

Gastrointestinal

Examination of the **gastrointestinal tract** revealed a stomach and intestine free of stasis, of normal wall thickness, acceptable curvilinear mural detail, and peristaltic activity. Small and large intestine demonstrated normal luminal chyme and stool consistency respectively. No obstructive or overt infiltrative disease was noted. No associated abnormal lymphatic activity was noted.

Pancreas

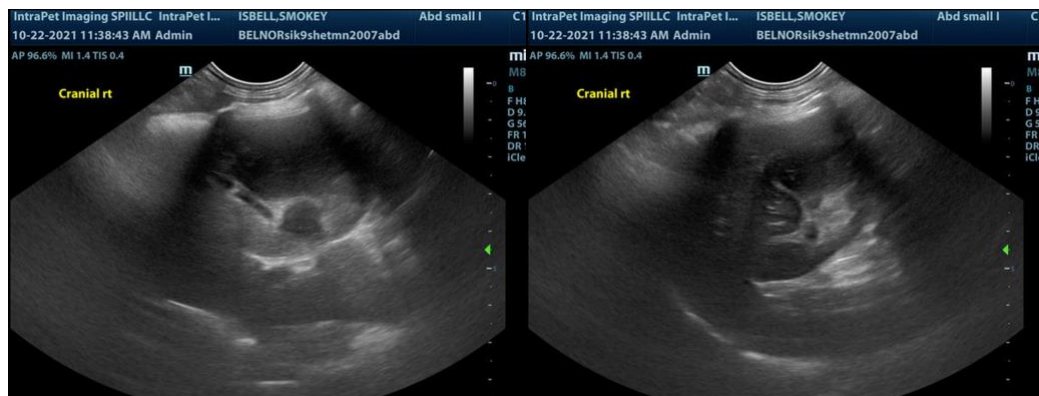
The base and limbs of the **pancreas** were observed to be largely isoechoic to surrounding omental fat. Pancreatic duct and capsular contour were acceptably normal and parenchyma respected normal curvilinear patterns. No overt evidence of active inflammatory or neoplastic disease was noted.

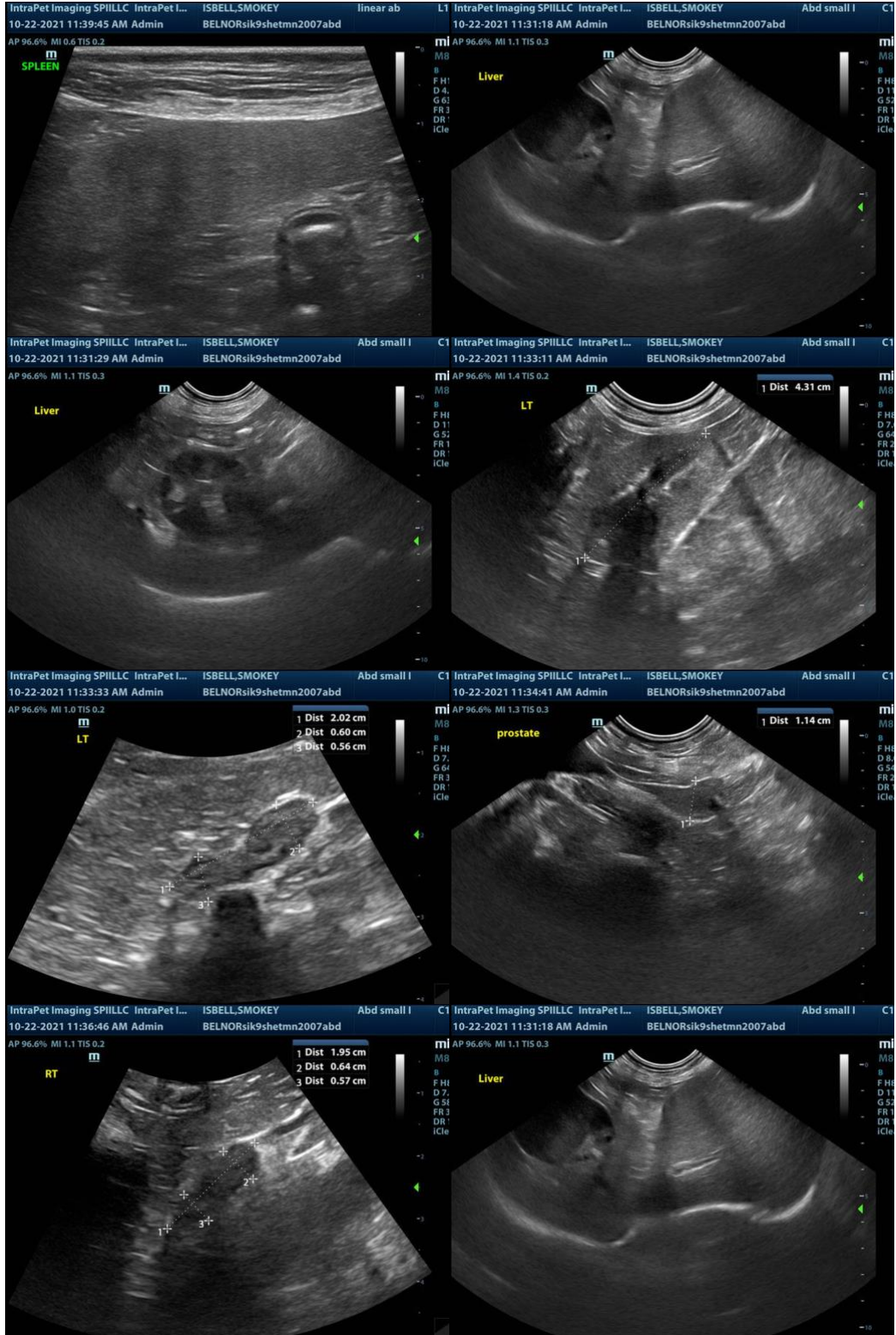
ULTRASONOGRAPHIC FINDINGS

- Gallbladder mucocele without evidence of inflammation
- Benign vacuolar hepatopathy/inflammatory hepatopathy pattern
- Age-related abdominal changes noted elsewhere

INTERPRETATION OF THE FINDINGS & FURTHER RECOMMENDATIONS

FNA could be considered. Empirical treatment for emerging mucocele recommended. Gallbladder motility study, empirical ursodiol therapy over 6 weeks and/or direct cholecystectomy from a proactive standpoint would all be valid in this patient.





The information and recommendations provided are based on the images presented by the referring veterinarian. No evaluation can be communicated regarding pathology that was not visible in the image/video clips provided.

Thank you for this referral. If the clinical or image interpretation does not parallel your findings or if I can be of any further assistance please contact me.

Eric Lindquist, DMV, DABVP, Cert. IVUSS, CEO of SonoPath.com
info@SonoPath.com

Gallbladder Mucoceles

<http://www.sonopath.com/GBMucocele>
<http://www.sonopath.com/GBMucoceleSurvey>
<http://www.sonopath.com/SxBiliaryDisease>

Description: A gallbladder mucocele occurs when the gallbladder becomes overly distended with an excessive accumulation of mucus secondary to cystic mucosal hyperplasia. Previously, pathologists noted this finding at necropsy and considered it an incidental or age-related lesion. In the last decade, however, it has become evident that not all gallbladder mucoceles remain clinically silent and that they can in fact be associated with extrahepatic bile duct obstruction (EHBDO), cholecystitis, and gallbladder wall rupture. Approximately 50% of mucoceles may result in necrosis and rupture, typically at the neck or fundic region of the gallbladder. The etiology of these mucoceles remains unknown, but researchers suspect that it is related to disordered cholestasis and/or lipid metabolism. Suggested causes include: primary or secondary gallbladder motility disorder; dyslipidemia/hypercholesterolemia; extrahepatic bile duct obstruction; and primary or secondary disorders of mucus-producing cells, such as cystic mucosal hyperplasia of the gallbladder wall. Clinical correlation is also seen with cholangitis, cholecystitis, cholelithiasis, biliary obstruction from cholelithiasis or neoplasia, and pancreatitis. Abnormal adrenal hormones may also play a causal role in altering gallbladder mucus secretion. Hypothyroid dogs are three times more likely to develop a mucocele, and Cushinoid dogs are twenty-nine times more likely to do so. Vacuolar hepatopathy frequently co-occurs with mucoceles; practitioners are therefore advised to investigate underlying disorders associated with vacuolar hepatopathy. Bacterial infection of the gallbladder has been associated with increased mucin production in dogs; this condition may also become pathological and lead to excessive mucus accumulation. In humans, hypercortisolism is related to chronic cholecystitis and changes the biochemical composition of bile. The latter, however, was not substantiated by two studies evaluating bile composition, bacterial infection, and sludge formation during a three-month period of exogenous administration of hydrocortisone administration in dogs. There is a marked increase in the prevalence of mucocele formation in dogs with naturally occurring hyperadrenocorticism, but a definitive correlational mechanism has yet not been ascertained.

Mucocele are most commonly seen in middle-aged to older dogs (median age of 10 years); however, researchers have reported mucocele development in dogs as young as 3 years old. Certain breeds—Miniature Schnauzers, Shetland Sheepdogs, Cocker Spaniels, Shih-tzus, Pugs, Bichon Frisés, Schipperkes, West Highland White Terriers, and Scottish Terriers—appear to be overrepresented

among canine patients. Significant predisposition to mucocele formation in Shelties prompted an investigation that uncovered a specific genetic mutation in the ABCB4 gene, which functions in the translocation of phosphatidylcholine across hepatocyte cell membranes. In the future, we may be able to screen young Shelties for this mutation, which would allow us to monitor gallbladder mucocele development with ultrasound over time and thereby offer early dietary and medical management, or even surgical intervention as needed. Felines are less commonly affected.

Clinical Signs: According to several retrospective studies, the most common clinical signs include vomiting (87%), abdominal pain (87%), anorexia (78%), lethargy, icterus (57%), and fever (26%). The average duration of illness is 5 days. Focal pain upon examining the gallbladder is common and referred to as a positive Murphy sign. Patients may also be asymptomatic, despite biochemical abnormalities, even in the face of ultrasonographic evidence of a mucocele. Patients with fully formed mucoceles are at risk of further complications, such as gallbladder rupture, peritonitis, sepsis, and related coagulopathies, and should be considered for surgical intervention.

Diagnostics: Biochemical analyses may indicate leukocytosis, with or without a left shift, and most commonly reveal elevated hepatic enzymes (SAP 100%, GGT 86%, ALT 77%, AST 60%) and bilirubin (63%). Ultrasonographic findings may include: a distended gallbladder with centrally suspended luminal content and a hypoechoic intraluminal rim; a thickened gallbladder wall; intraluminal stellate; echogenic striations (the “kiwi fruit sign”); and/or the presence of non-dependent intraluminal contents or sludge. (Note: The presence of the “kiwi fruit sign” is not essential for the diagnosis of a gall bladder mucocele, as many mucocele variations do not demonstrate a complete stellate pattern.) A hypoechoic ring seen around the gallbladder may indicate wall edema or early rupture. Presence of free fluid, as well as localized, echogenic hepatic parenchyma and intra-abdominal fat, are also consistent with bile leakage and peritonitis. Pain is often noted upon interrogation of the area. Dilation of the common bile duct may also be present.

Since there exists an association between hypercholesterolemia/hyperlipidemia and gallbladder mucoceles, patients that exhibit both should be screened for hypothyroidism, adrenal hyperplasia syndromes (Cushing’s disease and sex hormone dysregulation), diabetes mellitus, pancreatitis, exogenous exposure to glucocorticoids, and necroinflammatory liver disease.

Treatment: Surgical intervention is recommended due to the significant risk of peritonitis and sepsis associated with rupture, and since medical management on its own may not be effective. Candidates for surgery must be adequately stabilized prior to surgery, and a coagulation panel should be assessed beforehand. Use of ursodeoxycholic acid (Actigall) is not recommended if any sonographic aspects of wall inflammation or emergent perforation are present. Percutaneous centesis of the gallbladder is also not advised in the presence of a mucocele. Some studies that have investigated a relatively small number of dogs have found medical therapy with Actigall and SAMe to be somewhat effective at a very early subclinical stage. Yet, there are no definitive guidelines for ascertaining whether certain sonographic or laboratory findings permit the differentiation of a clinically significant mucocele versus a non-clinical, stable mucocele that may become clinically significant in the future. For this reason, each patient must be assessed individually. It may be the case that very dramatic mucoceles do not cause any overt clinical signs, whereas other patients may have minor mucoceles that lead to significant clinical signs and

necessitate urgent cholecystectomy to avoid the onset of bile peritonitis due to rupture. It is generally advised that dogs with clinical signs, elevated liver enzymes, elevated WBC counts, and sonographic evidence of a mucocele be treated surgically. However, if a clinically silent mucocele is found incidentally on ultrasound, careful observation and monitoring is reasonable, provided there are no underlying diseases that may promote degradation (e.g., hyperadrenocorticism). Owners should be instructed to carefully monitor their pets for the development of clinical signs that may signal progression of the disease.

Antibiotic therapy directed towards gram-negative, enteric bacteria (i.e., *E. coli*, *Klebsiella*, *Enterobacter*, etc.) and anaerobic bacteria is indicated, and will likely be necessary for several weeks following surgery. Culture and sensitivity results should guide long-term treatment. Cholecystectomy with a possible bile duct transposition is the procedure of choice. The bile duct is often flushed to remove sludge and debris to help avoid post-surgical obstruction. Cholecystotomy for removing gallbladder contents is not advised as studies have shown that mucocele concretions have reformed in several dogs treated in this manner. At the time of surgery, one should obtain liver biopsies as well as submit cultures and sensitivity of the gallbladder contents. Liver biopsies may show normal tissue, cholangiohepatitis, biliary hyperplasia, vacuolar hepatopathy, or mild to moderate portal hepatitis/fibrosis with bile duct proliferation. Ultrasound-guided cholecystocentesis is not recommended in dogs with mature mucoceles due to the risk of gallbladder rupture and seeding the abdomen with bacteria. Rupture of the gallbladder constitutes a surgical emergency and carries a worse prognosis for survival. Several investigators have noted that, upon surgical exploration of asymptomatic mucocele patients, there is evidence of prior localized peritonitis and fibrosis, likely resulting from tears in the gallbladder's neck, which lead to minute amounts of bile leakage.

Conclusion: Possible etiological explanations for gallbladder mucoceles are quite varied, and underlying diseases must be treated. The treatment of choice is cholecystectomy, with surgical intervention especially recommended for patients with clinical signs or significantly elevated liver enzymes so as to avoid gallbladder rupture and subsequent peritonitis.

References:

Aguirre AL, Center SA, Randolph JF, et al. Gallbladder disease in Shetland Sheepdogs: 38 cases (1995-2005). *J Am Vet Med Assoc* 2007;231(1):79-88.

Besso JG, Wrigley RH, Gliatto JM, Webster CR. Ultrasonographic appearance and clinical findings in 14 dogs with gallbladder mucocele. *Vet Radiol Ultrasound* 2000;41(3):261-71.

Cornejo L, Webster CRL. Canine gallbladder mucoceles. *Compend Contin Educ Vet* 2005;27:912-30.

Crews LJ, Feeney DA, Jessen CR, et al. Clinical, ultrasonographic, and laboratory findings associated with gallbladder disease and rupture in dogs: 45 cases (1997-2007). *J Am Vet Med Assoc* 2009;234(3):359-66.

Kook PH, Schellenberg S, Grest P, et al. Microbiologic evaluation of gallbladder bile of healthy dogs and dogs with iatrogenic hypercortisolism: a pilot study. *J Vet Intern Med* 2010;24(1):224-28.

Kook PH, Schellenberg S, Rentsch KM, et al. Effects of iatrogenic hypercortisolism on gallbladder sludge formation and biochemical bile constituents in dogs. *Vet J* 2012;191(2):225-30.

Malek S, Sinclair E, Hosgood G, et al. Clinical findings and prognostic factors for dogs undergoing cholecystectomy for gallbladder mucocele. *Vet Surg* 2013;42(4):418-26.

Mealey KL, Minch JD, White SN, et al. An insertion mutation in ABCB4 is associated with gallbladder mucocele formation in dogs. *Comp Hepatol* 2010;9:6.

Mehler SJ, Bennett RA. Canine Extrahepatic Biliary Tract Disease and Surgery. *Compend Contin Educ Vet* 2006;28(4):302-15.

Pike FS, Berg J, King NW, et al. Gallbladder mucocele in dogs: 30 cases (2000-2002). *J Am Vet Med Assoc* 2004;224(10):1615-22.

Walter R, Dunn ME, d'Anjou MA, L'Écuyer M. Nonsurgical resolution of gallbladder mucocele in two dogs. *J Am Vet Med Assoc* 2008;232(11):1688-93.

Worley DR, Hottinger HA, Lawrence HJ. Surgical management of gallbladder mucoceles in dogs: 22 cases (1999-2003). *J Am Vet Med Assoc* 2004;225(9):1418-22.