



PATIENT

Reba Michalek

SPECIES

Canine

BREED

Chihuahua Mix

SEX

Spayed Female

AGE

9 Years

WEIGHT

9 Pounds

INTERPRETED BY

Eric Lindquist, DMV
DABVP, Cert. IVUSS

IMAGING PERFORMED BY

Petrina Patete

HOSPITAL NAME

Mountain View VH

REFERRING VET

Petrina Patete

INVOICE

13991

DATE

10/22/21

PRESENTING CLINICAL SIGNS

History: Employee Pet Practice Ultrasound. No concerns.

Abnormal PE/Chem/CBC/UA Results: None

ULTRASONOGRAPHIC EXAMINATION OF THE ABDOMEN

Urinary System

The **urinary bladder**, trigone, and pelvic urethra presented normal thicknesses and normal tone. The ureters were not visible which is normal. No uroliths or sediment were visualized and anechoic urine was present. No evidence of inflammatory or neoplastic changes were noted. Ureteral papillae were normal. The pelvic urethra was imaged 2.0 cm beyond the cystourethral junction.

The **kidneys** revealed largely normal size and structure, corticomedullary definition and ratio (cortex 1/3 of medulla) were essentially maintained with some minor age-related loss of curvilinear patterns regarding the capsule and C/M junction. The cortices presented largely uniform texture with some increased echogenicity expected for his age patient. Medullary structure differed distinctly from that of the cortex and no evidence of pelvic dilation was present. The left kidney measured 3.7 cm. The right kidney measured 3.7 cm. Slight areas of mineralization noted in the right kidney.

Adrenal Glands

Both **adrenal glands** were visualized and recognized as having normal shape, size, position and echogenicity for this breed. The phrenic vasculature, glandular echogenicity and detail were unremarkable. Capsule, cortex, and medullary definition were normal for this age patient. The left adrenal gland measured 0.41 cm at the cranial pole and 0.42 cm at the caudal pole. The right adrenal gland measured 0.8 cm at the cranial pole and 0.5 cm at the caudal pole.

Spleen

The **spleen** presented a smooth homogeneous parenchyma hyperechoic to liver and renal cortical parenchyma. The capsule was smooth without noticeable expansion or deviation from within the spleen or adjacent pathology. The splenic vasculature demonstrated normal volume without signs of congestion or thrombosis. No sonographic evidence of acute or chronic inflammatory, neoplastic, or infarctual changes were noted. Caudal folding of the spleen was noted, uniform.

Liver

The **liver** images submitted revealed subjectively normal liver size, contour, and structure. Parenchymal echogenicity was naturally coarse and hypoechoic to the spleen. Vascular and biliary tracts were of normal volume with no evidence of congestion. The gallbladder presented acceptably thin walls with primarily anechoic content. The cystic and common bile ducts were normal. No pathological hepatic lymphadenopathy was evident. No overt structural evidence of inflammatory, infiltrative or regenerative pathology was evident.

Gastrointestinal

The **stomach** was filled with ingesta. Normal transit of chyme noted. This is most consistent with postprandial presentation. The small intestine and colon were unremarkable.

Pancreas



PATIENT

Reba Michalek

SPECIES

Canine

BREED

Chihuahua Mix

SEX

Spayed Female

AGE

9 Years

WEIGHT

9 Pounds

INTERPRETED BY

Eric Lindquist, DMV
DABVP, Cert. IVUSS

IMAGING PERFORMED BY

Petrina Patete

HOSPITAL NAME

Mountain View VH

REFERRING VET

Petrina Patete

INVOICE

13991

DATE

10/22/21

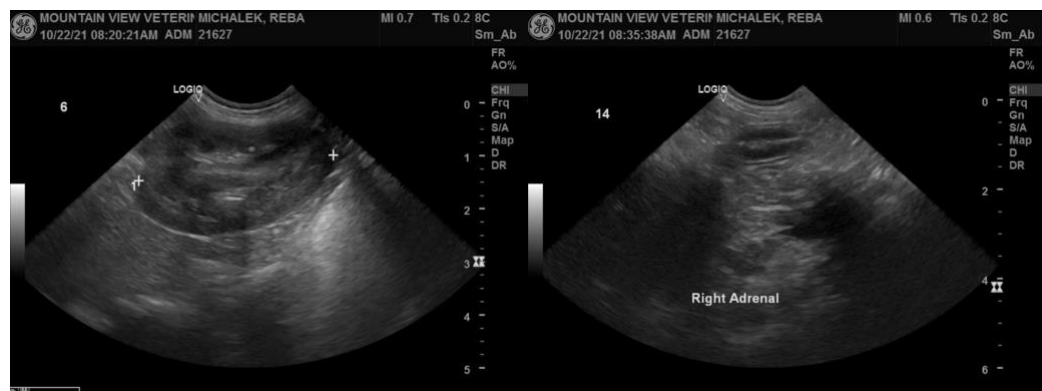
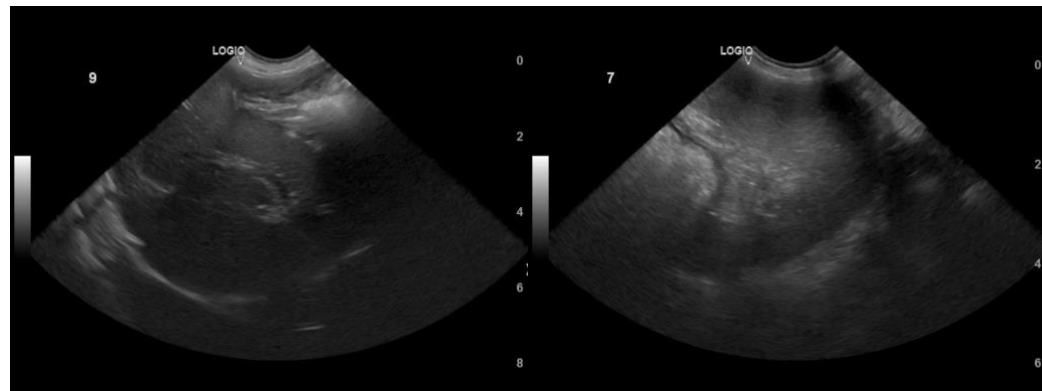
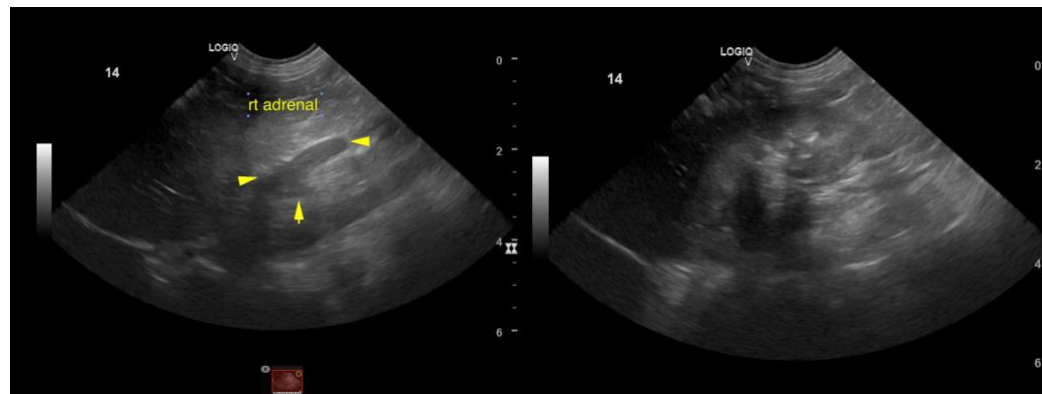
The base and limbs of the **pancreas** were observed to be largely isoechoic to surrounding omental fat. Pancreatic duct and capsular contour were acceptably normal and parenchyma respected normal curvilinear patterns. No overt evidence of active inflammatory or neoplastic disease was noted.

ULTRASONOGRAPHIC FINDINGS

- Full stomach
- Age-related renal changes with minor renal mineralization
- Splenic fold

INTERPRETATION OF THE FINDINGS & FURTHER RECOMMENDATIONS

Unremarkable abdomen otherwise.





PATIENT

Reba Michalek

SPECIES

Canine

BREED

Chihuahua Mix

SEX

Spayed Female

AGE

9 Years

WEIGHT

9 Pounds

INTERPRETED BY

Eric Lindquist, DMV
DABVP, Cert. IVUSS

IMAGING PERFORMED BY

Petrina Patete

HOSPITAL NAME

Mountain View VH

REFERRING VET

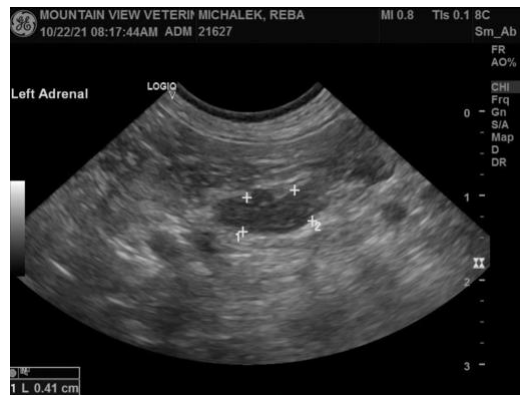Petrina Patete

INVOICE

13991

DATE

10/22/21



The information and recommendations provided are based on the images presented by the referring veterinarian. No evaluation can be communicated regarding pathology that was not visible in the image/video clips provided.

Thank you for this referral. If the clinical or image interpretation does not parallel your findings or if I can be of any further assistance please contact me.

Eric Lindquist, DMV, DABVP, Cert. IVUSS, CEO of SonoPath.com
info@SonoPath.com