



PATIENT

Lari Pergerson

SPECIES

Feline

BREED

Domestic Shorthair

SEX

Spayed Female

AGE

7 years

WEIGHT

5.63 lbs

PRESENTING CLINICAL SIGNS

History: Presents on routine physical with a newly auscultated murmur, Grade II, left and right parasternal. Hx IBD and renal insufficiency
BUN and creat mildly elevated (41, 2.5)- static from last bldwrk BNP slightly elevated- 143 T4- 2.2

ULTRASONOGRAPHIC EXAMINATION OF THE HEART

The echocardiogram in this patient demonstrated normal **left atrial** size based on 3 separate LA measurements. The cranial and caudal **mitral** valve leaflets presented normal linear structure and kinetics.. The **left ventricle** presented normal thicknesses with linear contour and was not dilated nor restricted. The **myocardium** presented normal echogenicity without subjective evidence of significant fibrotic or ischemic disease. **Contractility** of the ventricular walls was adequate and in normal range for this patient evidenced by the fractional shortening measurement and subjective evaluation of the different regions and angles of the myocardium. The **left ventricular outflow** tract demonstrated normal laminar flow and subjective structural integrity. The **right atrium** and auricle revealed normal size, structure and content. No evidence of masses was noted or chamber overload. **Tricuspid** valvular assessment demonstrated adequate linear morphology and kinetics. The **right ventricle** was of normal size (1/3 diameter of LV), chordae structure, myocardial echogenicity and thickness. **Pulmonic** tract assessment revealed normal valve structure, laminar flow, and diameter (approx.1:1 pa/ao ratio). No visible **pericardial** or free pleura fluid was noted or extra cardiac pathology in the visible planes. The cranial **mediastinum** and **pericardial regions** were free of masses in the visible window.

INTERPRETED BY

Eric Lindquist, DMV
DABVP, Cert. IVUSS

IMAGING PERFORMED BY

Dr. Gregory

HOSPITAL NAME

Casco Bay VH

REFERRING VET

Dr. Gregory

INVOICE

92574

DATE

10/22/21

FELINE CARDIAC PARAMETERS	BODY WEIGHT (kg)	HR (BPM)	IVSd (cm)	LVIDd (cm)	LVWd (cm)	FS (%)	EF (%)
NORMAL PARAMETER	-----	150-240	0.3-0.6	1.0-2.1	0.25-0.6	35-67	80-100
PATIENT		NM	0.5	1.1		50	
FELINE CARDIAC PARAMETERS	LA/AO (Boon)	LA/AO HEART BASE (Sisson)	LA 2D 4-chamber long axis AS to FW (Sisson) (cm)	LVOT VEL. (m/s)	RVOT VEL. (m/s)	IVRT (m/)	
NORMAL PARAMETER	<1.5	0.88-1.79	0.7-1.7	<1.6	<1.3	40-60	
PATIENT	1.3						NM
Adapted from June Boon, Veterinary Echocardiography, 1998 Sisson D et al. JVIM 1991; 5: 232, Jacobs et al. Am J Vet Res 1985; 46:1705							



PATIENT

Lari Pergerson

ULTRASONOGRAPHIC FINDINGS

Normal echocardiogram.

Idiopathic flow murmur.

SPECIES

Feline

INTERPRETATION OF THE FINDINGS & FURTHER RECOMMENDATIONS

The murmur cannot be exactly localized; however, benign flow murmurs are common in cats. Structurally and functionally the heart is normal.

BREED

Domestic Shorthair

Flow murmurs can be caused by volume shifts, anemia, excitable/tachycardic state or stethoscope pressure upon clinical exam are typically benign and may develop later in life theoretically owing to age related changes of the heart or DRVOTO which is clinically insignificant.

SEX

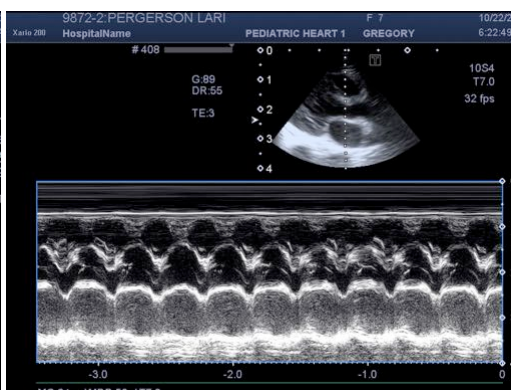
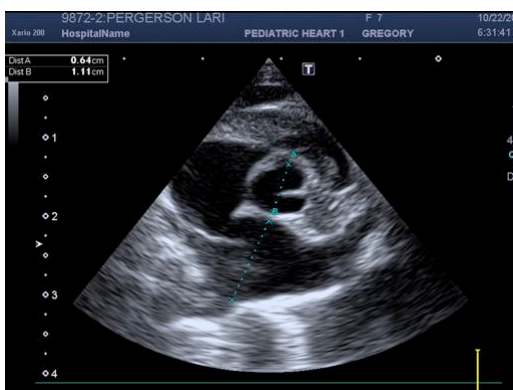
Spayed Female

AGE

7 years

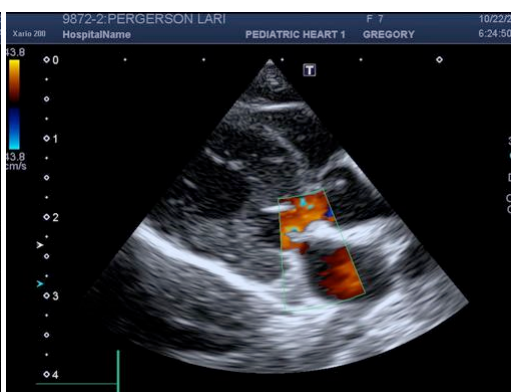
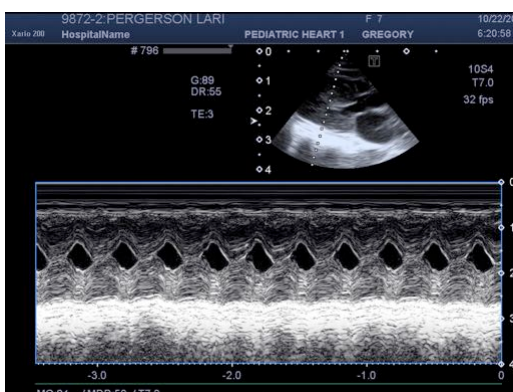
WEIGHT

5.63 lbs



INTERPRETED BY

Eric Lindquist, DMV
DABVP, Cert. IVUS



IMAGING PERFORMED BY

Dr. Gregory

HOSPITAL NAME

Casco Bay VH

REFERRING VET

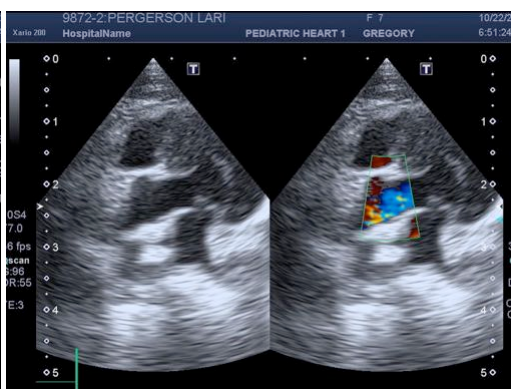
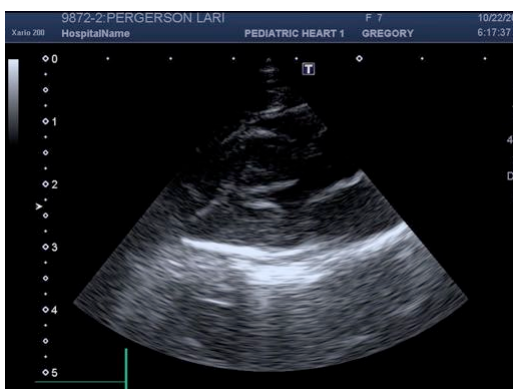
Dr. Gregory

INVOICE

92574

DATE

10/22/21





PATIENT

Lari Pergerson

SPECIES

Feline

BREED

Domestic Shorthair

SEX

Spayed Female

AGE

7 years

WEIGHT

5.63 lbs

INTERPRETED BY

Eric Lindquist, DMV
DABVP, Cert. IVUSS

**IMAGING
PERFORMED BY**

Dr. Gregory

HOSPITAL NAME

Casco Bay VH

REFERRING VET

Dr. Gregory

INVOICE

92574

DATE

10/22/21

The information and recommendations provided are based on the images presented by the referring veterinarian. No evaluation can be communicated regarding pathology that was not visible in the image/video clips provided.

Thank you for this referral. If the clinical or image interpretation does not parallel your findings or if I can be of any further assistance please contact me.

Eric Lindquist, DMV, DABVP, Cert. IVUSS, CEO of SonoPath.com
info@SonoPath.com