

PATIENT

Katie McCourt

SPECIES

Canine

BREED

Golden Retriever Mix

SEX

Spayed Female

AGE

11 Years

WEIGHT

59 Pounds

INTERPRETED BY

Eric Lindquist, DMV
DABVP, Cert. IVUSS

IMAGING PERFORMED BY

Diane McFadden

HOSPITAL NAME

Rockaway AH

REFERRING VET

Dr. Maniar

INVOICE

13973

DATE

10/22/21

PRESENTING CLINICAL SIGNS

History: mass palpated in neck; FNA today

Abnormal PE/Chem/CBC/UA Results: elevated T4 and FT4

LIMITED ULTRASONOGRAPHIC EXAMINATION

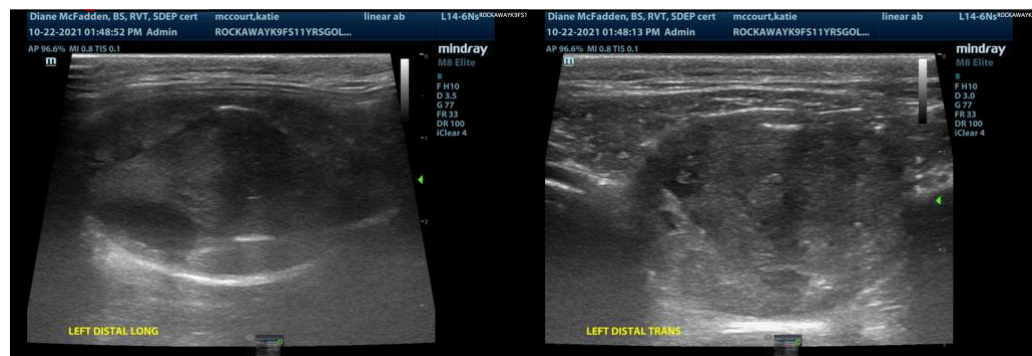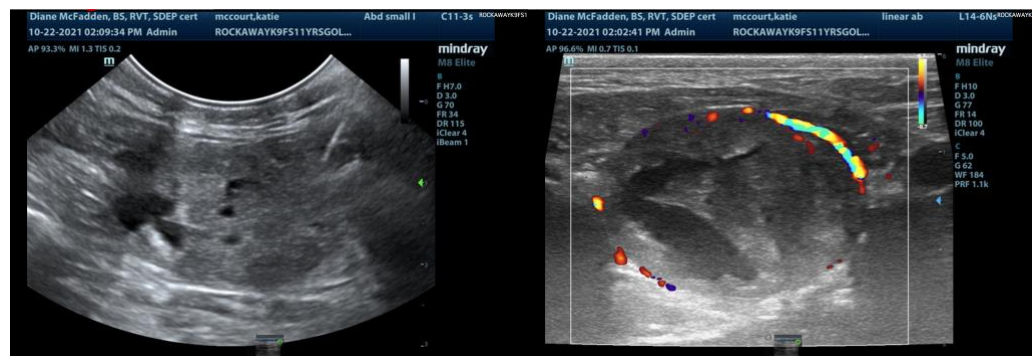
A mineralizing mass was noted in the region of the left thyroid with mild areas of cavitation. The mass is somewhat more ventral, this may represent ectopic tissue, appears encapsulated and resectable. Surgical consult warranted. CT evaluation for surgical planning would be ideal. The right thyroid lobe was fairly subnormal in size, measuring 3.0 mm in maximum width X 1.0 cm. Parathyroid was unremarkable. Esophagus, parotid salivary glands and regional tissues are all normal.

ULTRASONOGRAPHIC FINDINGS

- Mineralizing mass distal to the left thyroid lobe- Suspect thyroid carcinoma, possibly deriving from ectopic tissue
- Subjectively atrophied right thyroid lobe

INTERPRETATION OF THE FINDINGS & FURTHER RECOMMENDATIONS

Full thyroid profile recommended to assess if this lesion is causing a hyperthyroid state. Surgical consult recommended.





PATIENT

Katie McCourt

SPECIES

Canine

BREED

Golden Retriever Mix

SEX

Spayed Female

AGE

11 Years

WEIGHT

59 Pounds

INTERPRETED BY

Eric Lindquist, DMV
DABVP, Cert. IVUSS

IMAGING PERFORMED BY

Diane McFadden

HOSPITAL NAME

Rockaway AH

REFERRING VET

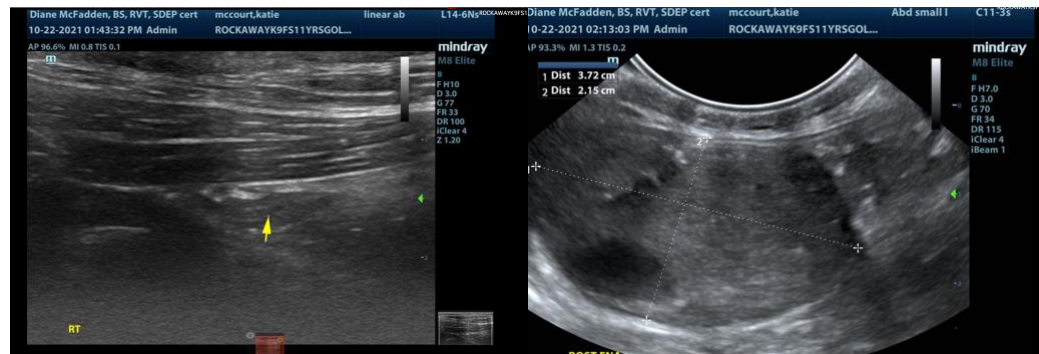Dr. Maniar

INVOICE

13973

DATE

10/22/21



The information and recommendations provided are based on the images presented by the referring veterinarian. No evaluation can be communicated regarding pathology that was not visible in the image/video clips provided.

Thank you for this referral. If the clinical or image interpretation does not parallel your findings or if I can be of any further assistance please contact me.

Eric Lindquist, DMV, DABVP, Cert. IVUSS, CEO of SonoPath.com
info@SonoPath.com