

**DATE**

10/22/21

**PRESENTING CLINICAL SIGNS**

History: Seizure dog, on Phenobarbital. Clinically stable. 10/13/21- Alkphs 1385 U/L, prev 579 U/L on 10/7/2020. Recd AUS prior to upcoming dental procedure.

Current Medications: Phenobarbital 1 grain (64.8 mg) po q 12 hours since 1/2019.

Lab Results: Alkphs 1385 U/L, prev 579 U/L on 10/7/2020, on Phenobarb.

Radiographs: Not provided by the veterinarian.

Date of Previous IntraPet Ultrasound: No previous IntraPet scans.

Sedation: not needed

Stat Report: not requested

**PATIENT**

Cooper Stratton

**SPECIES**

Canine

**BREED**

Beagle Mix

**SEX**

Neutered male

**AGE**

5/12

**WEIGHT**

45 lbs

**INTERPRETED BY**

Eric Lindquist, DMV  
DABVP, Cert. IVUSS

**HOSPITAL NAME**

Greenbrier for Swan  
Creek VC

**REFERRING VET**

Dr. Holloway

**INVOICE**

92591

**ULTRASONOGRAPHIC EXAMINATION OF THE ABDOMEN****Urinary System**

The **urinary bladder**, trigone, and pelvic urethra presented normal thicknesses and normal tone. The ureters were not visible which is normal. No uroliths or sediment were visualized and anechoic urine was present. No evidence of inflammatory or neoplastic changes was noted. Ureteral papillae were normal.

The **kidneys** revealed normal size and structure, corticomedullary definition and ratio for this age. The cortices presented largely uniform texture with normal echogenic relationship to liver and spleen. Medullary structure differed distinctly from the cortex and no evidence of pelvic dilation was present. The capsules were acceptably uniform without significant irregularities. The left kidney measured 5.68 cm with slight pinpoint mineralization. The right kidney measured 6.11 cm.

**Adrenal Glands**

Both **adrenal glands** were visualized and recognized as having normal shape, size, position and echogenicity for this breed. The phrenic vasculature, glandular echogenicity and detail were unremarkable. Capsule, cortex, and medullary definition were normal for this age patient. The left adrenal gland measured 2.27 x 0.75 cm at the caudal pole and 0.66 cm at the cranial pole. The right adrenal gland measured 2.5 x 0.82 cm at the caudal pole and 0.92 cm at the cranial pole.

**Spleen**

The **spleen** was largely smooth with subtle heterogeneous parenchymal changes while maintaining normal echogenic relationship to the liver and kidney. These changes are consistent with normal age-related alteration. The capsule was smooth without noticeable impingement from within the spleen or from pathology in the adjacent abdomen. The splenic vasculature demonstrated normal volume without signs of congestion or significant contraction. No evidence of active acute or chronic inflammatory, neoplastic, or infarctual changes was noted.

**Liver**

The **liver** revealed mild uniform swelling and slight coarse architecture. The gallbladder and common bile duct were unremarkable. There was no evidence of significant disease.

**Gastrointestinal**

Examination of the **gastrointestinal tract** revealed a stomach and intestine free of stasis, of normal wall thickness, acceptable curvilinear mural detail, and peristaltic activity. Small and large intestine demonstrated normal luminal chyme and stool consistency respectively. No obstructive or overt infiltrative disease was noted. No associated abnormal lymphatic activity was noted.

### **Pancreas**

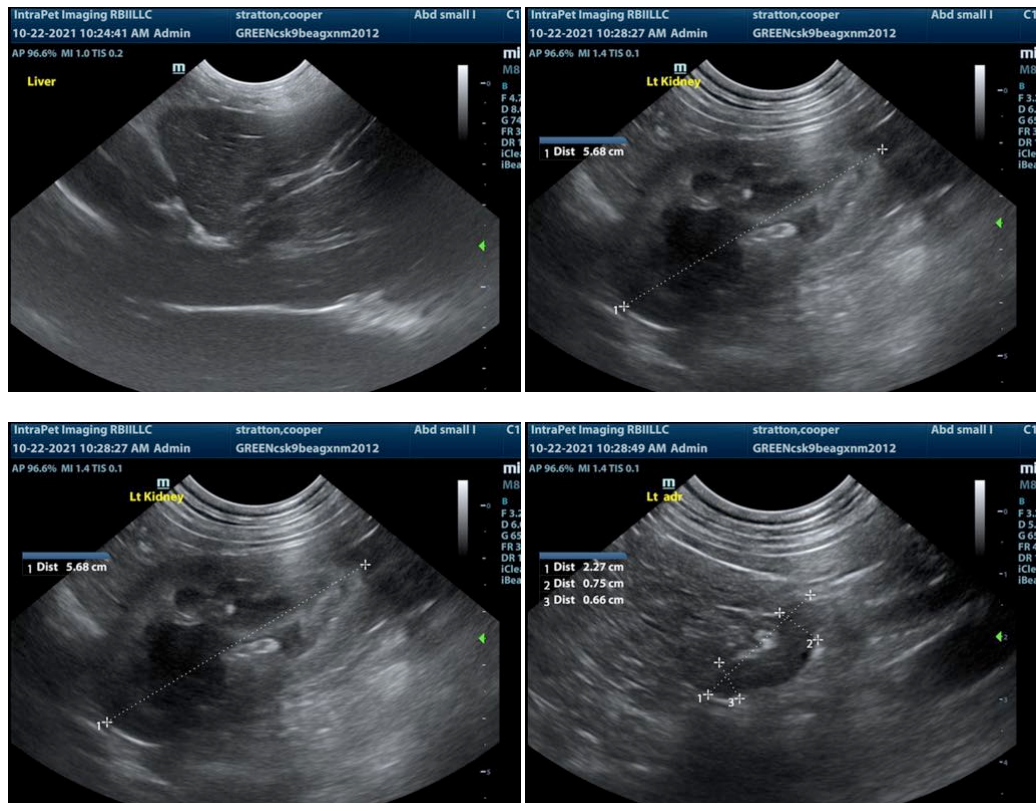
The base and limbs of the **pancreas** were observed to be largely isoechoic to surrounding omental fat. Some parenchymal remodeling, however, with mild deviation from curvilinear normalcy was observed. Pancreatic duct and capsular irregularities were present consistent with age related changes. If pain upon imaging (+ Murphy sign) was present or if the patient is focally painful in subxiphoid palpation then low-grade smoldering chronic pancreatitis should be suspected.

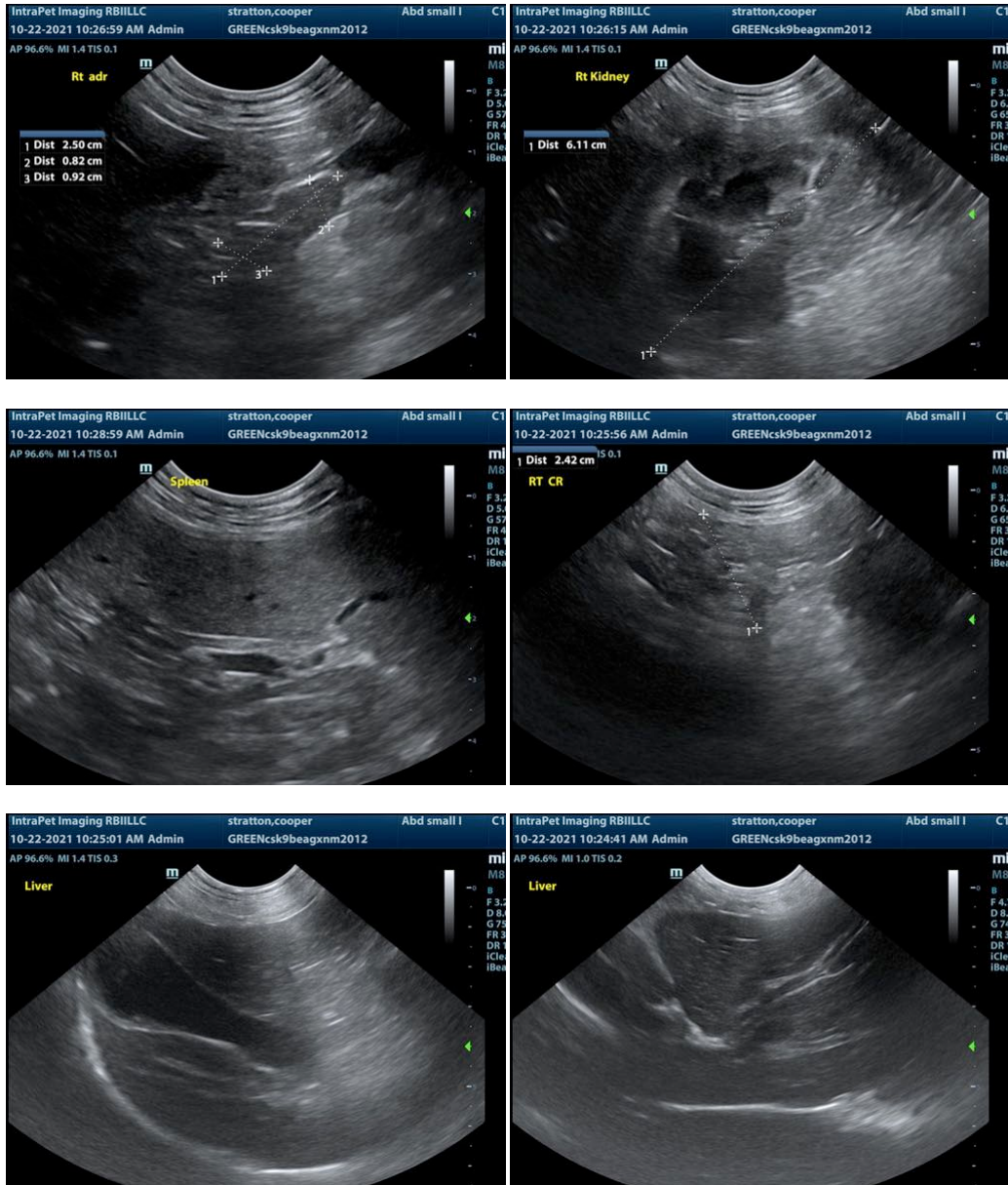
### **ULTRASONOGRAPHIC FINDINGS**

Age related abdominal changes.  
Benign hepatopathy.

### **INTERPRETATION OF THE FINDINGS & FURTHER RECOMMENDATIONS**

There is no evidence of significant disease or primary disease that would be responsible for the seizure activity. If seizure activity is not able to be controlled with medical measures then CT with contrast of the brain is recommended.





The information and recommendations provided are based on the images presented by the referring veterinarian. No evaluation can be communicated regarding pathology that was not visible in the image/video clips provided.

Thank you for this referral. If the clinical or image interpretation does not parallel your findings or if I can be of any further assistance please contact me.

**Eric Lindquist, DMV, DABVP, Cert. IVUSS, CEO of SonoPath.com**  
 Eric.Lindquist@SonoPath.com