



PATIENT

Bessie Alston

SPECIES

Canine

BREED

Cocker Spaniel

SEX

Spayed Female

AGE

7 Years

WEIGHT

29.4 Pounds

INTERPRETED BY

Eric Lindquist, DMV
DABVP, Cert. IVUSS

IMAGING PERFORMED BY

Kelly Vazquez

HOSPITAL NAME

Englewood VC

REFERRING VET

Dr. Ezik

INVOICE

13965

DATE

10/22/21

PRESENTING CLINICAL SIGNS

History: No heart murmur detected, but EKG suggests cardiomegaly and chest radiographs also suggests equivocal enlargement.

Abnormal PE/Chem/CBC/UA Results:

ULTRASONOGRAPHIC EXAMINATION OF THE ABDOMEN

Urinary System

The **urinary bladder** and visible pelvic urethra were unremarkable for the level of repletion presented. The urine, however, did present moderate mildly echogenic debris consistent with mucous, exfoliated cells from renal or bladder origin, and/or blood clots as these echogenic changes can all present similarly. This is often related to urinary tract infection but may represent simple evidence of exfoliated debris or sterile inflammation. Cystocentesis, urinalysis, +/- culture would be recommended to rule out and define any UTI. The pelvic urethra was imaged 2.0 cm beyond the cystourethral junction.

The **kidneys** revealed normal size and structure, corticomedullary definition and ratio for this age. The cortices presented largely uniform texture with normal echogenic relationship to liver and spleen. Medullary structure differed distinctly from the cortex and no evidence of pelvic dilation was present. The capsules were acceptably uniform without significant irregularities. The right kidney measured 4.76 cm. The left kidney measured 5.12 cm.

Adrenal Glands

Both **adrenal glands** were visualized and recognized as having normal shape, size, position and echogenicity for this breed. The phrenic vasculature, glandular echogenicity and detail were unremarkable. Capsule, cortex, and medullary definition were normal for this age patient. The left adrenal gland measured 1.82 cm x 0.48 cm at the caudal pole and 0.51 cm at the cranial pole. The right adrenal gland measured 1.59 cm x 0.39 cm at the caudal pole and 0.76 cm at the cranial pole.

Spleen

The **spleen** presented a smooth homogeneous parenchyma hyperechoic to liver and renal cortical parenchyma. The capsule was smooth without noticeable expansion or deviation from within the spleen or adjacent pathology. The splenic vasculature demonstrated normal volume without signs of congestion or thrombosis. No sonographic evidence of acute or chronic inflammatory, neoplastic, or infarctual changes were noted.

Liver

The **liver** images from right and left intercostal as well as subcostal views revealed subjectively normal liver size, contour, and structure. Some minor age-related parenchymal remodeling was noted but likely not clinically significant at this time. Vascular and biliary tracts were of normal volume and no evidence of congestion was noted. The gallbladder presented some dependent debris with essentially normal contour. The cystic and common bile ducts were normal. No overt evidence of active inflammatory, infiltrative or regenerative pathology was noted but should be paired with current or past LE elevations regarding any clinical significance to this presentation. The hepatic lymph nodes were unremarkable.



PATIENT

Gastrointestinal

Bessie Alston

Examination of the **gastrointestinal tract** revealed a stomach and intestine free of stasis, of normal wall thickness, acceptable curvilinear mural detail, and peristaltic activity. Small and large intestine demonstrated normal luminal chyme and stool consistency respectively. No obstructive or overt infiltrative disease was noted. No associated abnormal lymphatic activity was noted.

SPECIES

Canine

Pancreas

BREED

Cocker Spaniel

The base and limbs of the **pancreas** were observed to be largely isoechoic to surrounding omental fat. Pancreatic duct and capsular contour were acceptably normal and parenchyma respected normal curvilinear patterns. No overt evidence of active inflammatory or neoplastic disease was noted.

SEX

Spayed Female

- Unremarkable abdomen
- Urinary Bladder debris
- Age-related hepatic changes

AGE

7 Years

INTERPRETATION OF THE FINDINGS & FURTHER RECOMMENDATIONS

No evidence of pathology. Expected changes for this age patient.

WEIGHT

29.4 Pounds

INTERPRETED BY

Eric Lindquist, DMV
DABVP, Cert. IVUSS

IMAGING PERFORMED BY

Kelly Vazquez

HOSPITAL NAME

Englewood VC

REFERRING VET

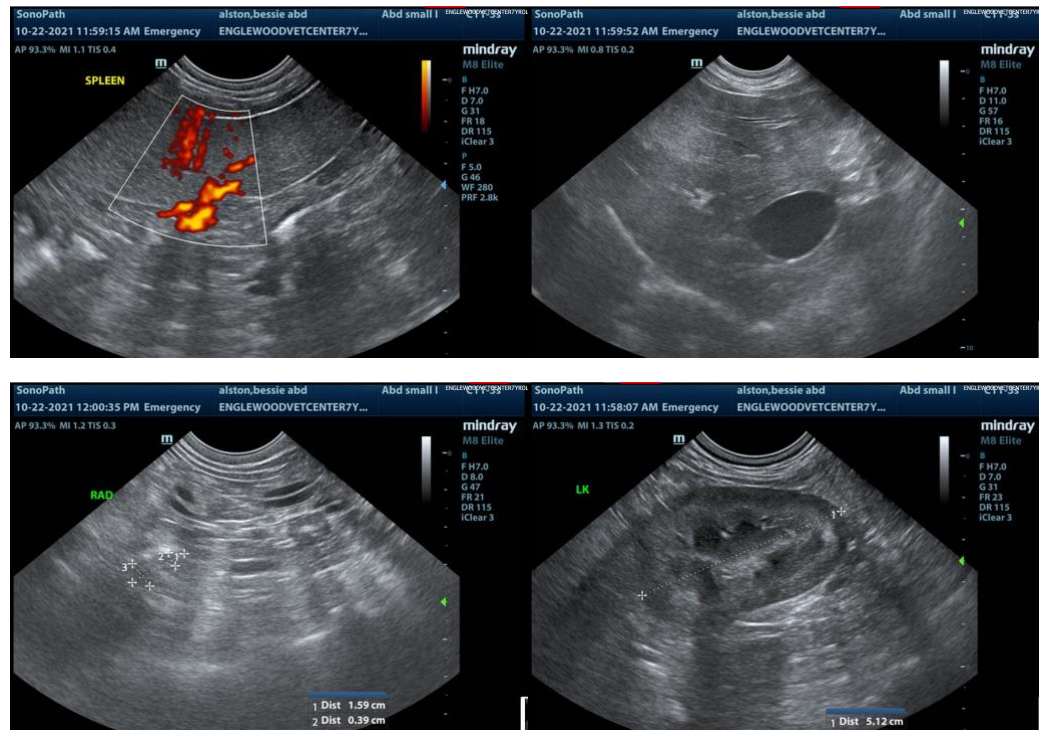
Dr. Ezik

INVOICE

13965

DATE

10/22/21





PATIENT

Bessie Alston

SPECIES

Canine

BREED

Cocker Spaniel

SEX

Spayed Female

AGE

7 Years

WEIGHT

29.4 Pounds

INTERPRETED BY

Eric Lindquist, DMV
DABVP, Cert. IVUSS

IMAGING PERFORMED BY

Kelly Vazquez

HOSPITAL NAME

Englewood VC

REFERRING VET

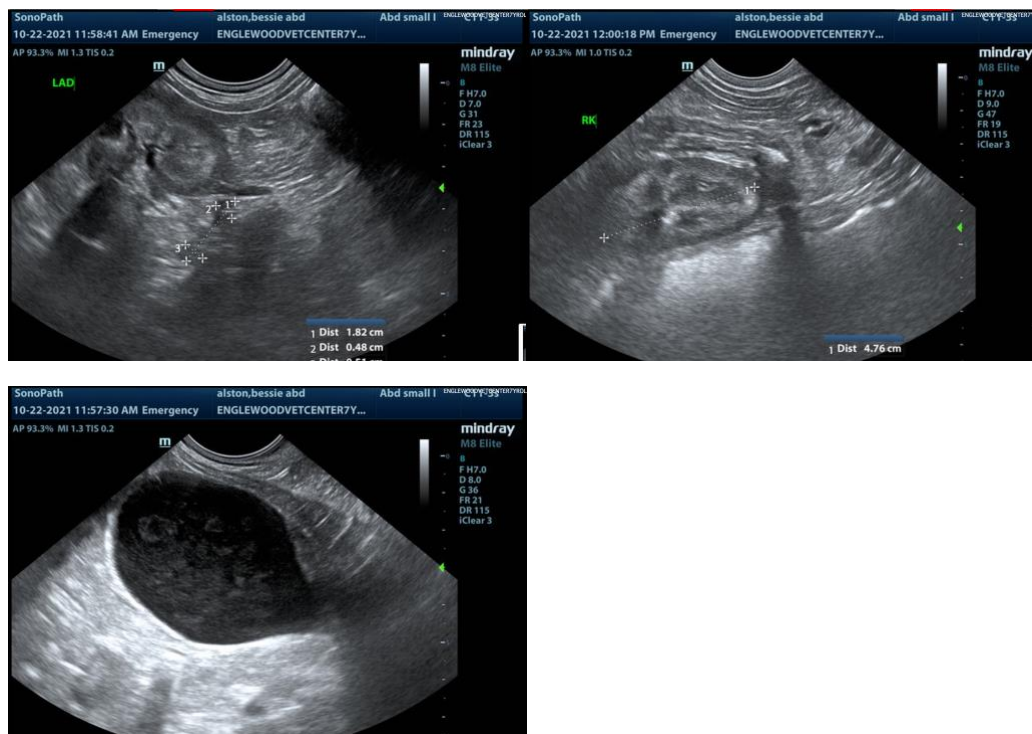
Dr. Ezik

INVOICE

13965

DATE

10/22/21



The information and recommendations provided are based on the images presented by the referring veterinarian. No evaluation can be communicated regarding pathology that was not visible in the image/video clips provided.

Thank you for this referral. If the clinical or image interpretation does not parallel your findings or if I can be of any further assistance please contact me.

Eric Lindquist, DMV, DABVP, Cert. IVUSS, CEO of SonoPath.com
info@SonoPath.com