

PATIENT

Berkeley Tolliver

SPECIES

Canine

BREED

Golden Retriever Mix

SEX

Neutered Malw

AGE

1 Year

WEIGHT

20 Pound

INTERPRETED BY

Eric Lindquist, DMV
DABVP, Cert. IVUSS

IMAGING PERFORMED BY

Diane McFadden

HOSPITAL NAME

Rockaway AH

REFERRING VET

Dr. Maniar

INVOICE

13969

DATE

10/22/21

PRESENTING CLINICAL SIGNS

History: thyroid scan; FNA of skin mass on neck, question whether it is thyroid tissue, or attached to thyroid or other.

Abnormal PE/Chem/CBC/UA Results:

LIMITED ULTRASONOGRAPHIC EXAMINATION

A subcutaneous mixed echogenic mass noted in this patient most consistent with granuloma. The thyroid lobes were uniform, measuring 1.93 cm on the left and 1.6 cm on the right, do not appear involved in the process. The trachea, esophagus, regional tissue and salivary glands were all normal. Parathyroid glands were normal size and contour. Regional lymphadenopathy in the region of the salivary gland, reactive, the largest lymph node measured 2.0 cm x 1.5 cm. Cannot rule out a penetrating foreign body in this patient.

ULTRASONOGRAPHIC FINDINGS

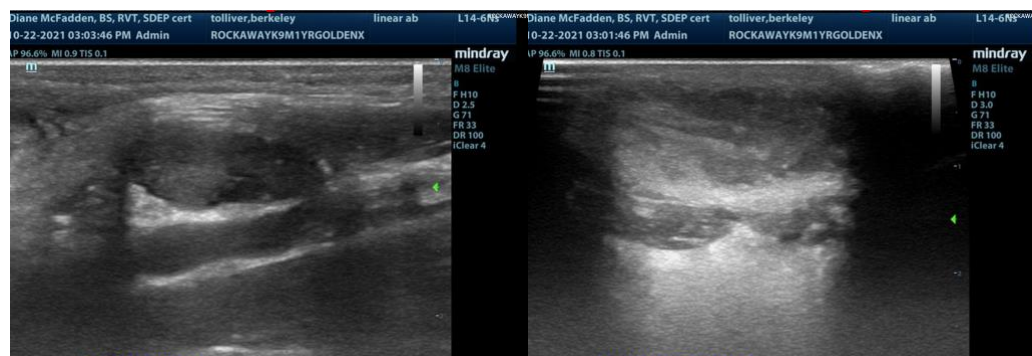- Cellulitis presentation with regional lymphadenopathy

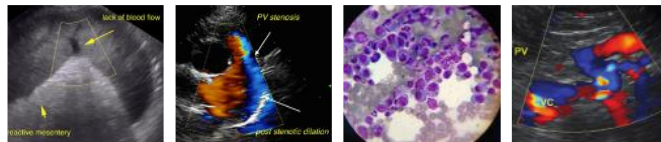
INTERPRETATION OF THE FINDINGS & FURTHER RECOMMENDATIONS

Neck CT recommended to assess the extent of the pathology. Broad spectrum antibiotics to treat for cellulitis such as enrofloxacin/clindamycin combination.

SonoPath CT Services are offered at the [Blairstown Animal Hospital](https://www.blairstownanimalhospital.com/). Blairstown animal hospital is just a 30-minute drive west on route 80 from the route 80/287 interchange/Parsippany, New Jersey. More information can be found at:

<https://sonopath.com/resources/sonopaths-teleconsultation-services-and-sdep-certification/sonopath-ct-services>





PATIENT

Berkeley Tolliver

SPECIES

Canine

BREED

Golden Retriever Mix

SEX

Neutered Malw

AGE

1 Year

WEIGHT

20 Pound

INTERPRETED BY

Eric Lindquist, DMV
DABVP, Cert. IVUSS

IMAGING PERFORMED BY

Diane McFadden

HOSPITAL NAME

Rockaway AH

REFERRING VET

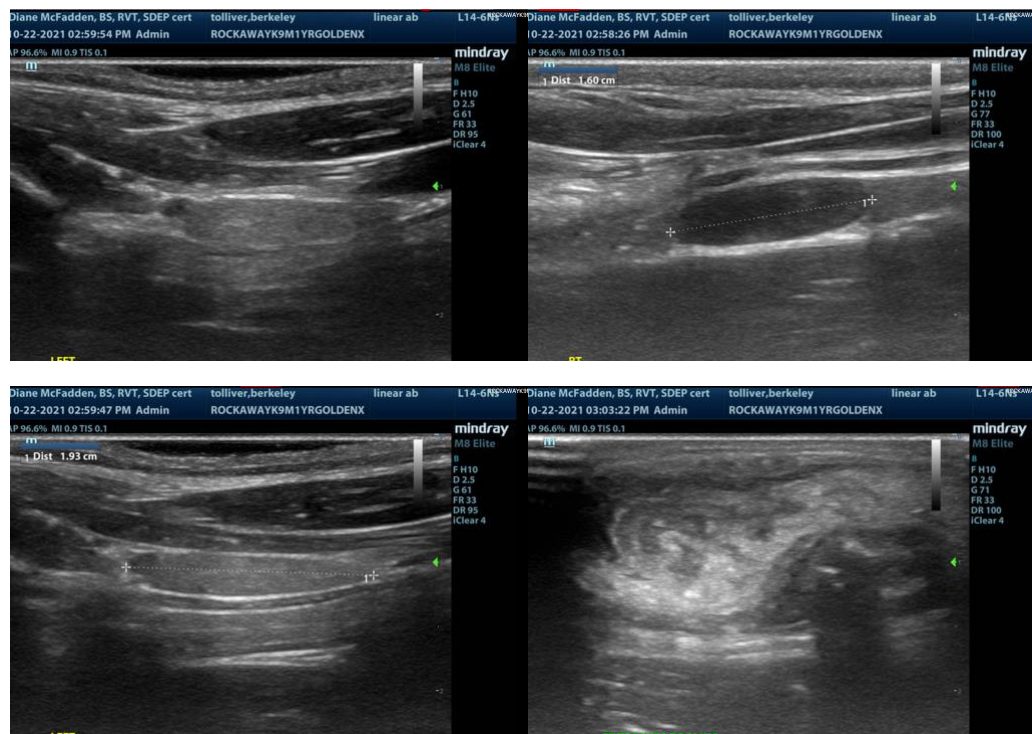
Dr. Maniar

INVOICE

13969

DATE

10/22/21



The information and recommendations provided are based on the images presented by the referring veterinarian. No evaluation can be communicated regarding pathology that was not visible in the image/video clips provided.

Thank you for this referral. If the clinical or image interpretation does not parallel your findings or if I can be of any further assistance please contact me.

Eric Lindquist, DMV, DABVP, Cert. IVUSS, CEO of SonoPath.com
info@SonoPath.com