



PATIENT

PRESENTING CLINICAL SIGNS

Adrienne Lemming

History: Owner dropped off urine month ago for greenish hue to it. WBC-50 HPF, Cocci Seen then on 09/17, treated with Cefpodoxime, Abnormal PE/Chem/CBC/UA Results: Recheck urine - Chronic Hematuria L USG 1.030 , Protein 2+], RBC 21-50 HPF.

SPECIES

Canine

BREED

Mix

SEX

Spayed Female

AGE

8 years

WEIGHT

53.6 lbs

INTERPRETED BY

Eric Lindquist, DMV
DABVP, Cert. IVUSS

IMAGING PERFORMED BY

Marco Lichfield

HOSPITAL NAME

Sova AH

REFERRING VET

Dr. Ammeraal

INVOICE

92573

DATE

10/22/21

ULTRASONOGRAPHIC EXAMINATION OF THE ABDOMEN

Urinary System

The **urinary bladder** reveals large calculi and a large amount of suspended debris. Grouping of calculi measured 2.6 cm. The largest calculus measured 1.0 cm and was non-obstructive at the time of the sonogram. A cystourethral polyp was noted and measured 0.5 cm. This may be related to passage of calculi in the past. There is a minor potential for transitional cell carcinoma. The urethra was unremarkable.

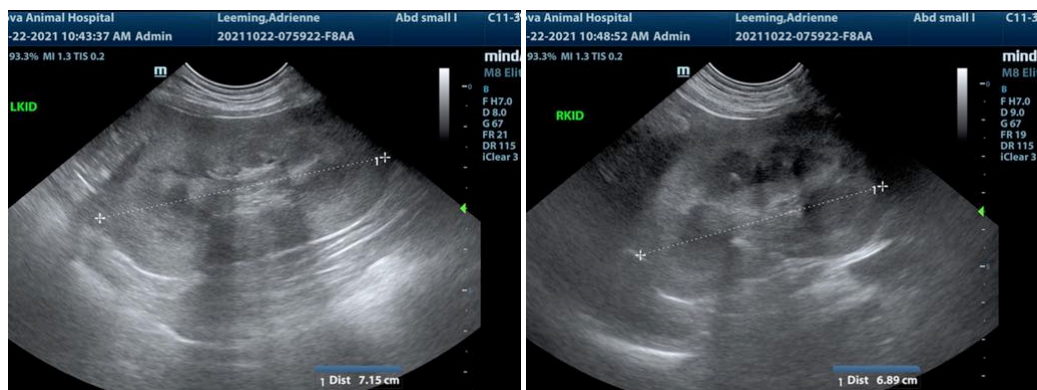
The **kidneys** revealed normal size and structure, corticomedullary definition and ratio for this age. The cortices presented largely uniform texture with normal echogenic relationship to liver and spleen. Medullary structure differed distinctly from the cortex and no evidence of pelvic dilation was present. The capsules were acceptably uniform without significant irregularities. Slight mineralization was noted in the kidneys. The left kidney measured 7.15 cm. The right kidney measured 6.89 cm.

ULTRASONOGRAPHIC FINDINGS

Bladder calculi with cystourethral junction polyp.
Renal mineralization.

INTERPRETATION OF THE FINDINGS & FURTHER RECOMMENDATIONS

I recommend cystotomy, bladder lavage and biopsy of the polyp noted on the dorsal aspect of the cystourethral junction. This appears to be mucosal. Treatment for urinary tract infection is warranted over a 4 week period may be necessary.





PATIENT

Adrienne Lemming

SPECIES

Canine

BREED

Mix

SEX

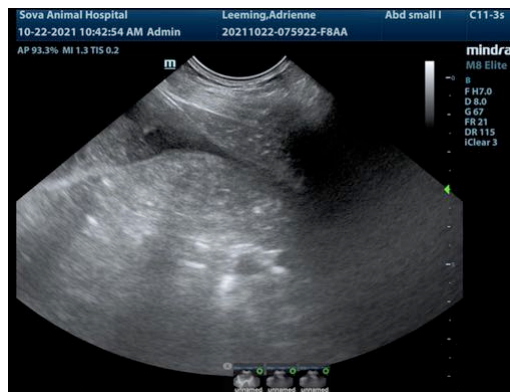
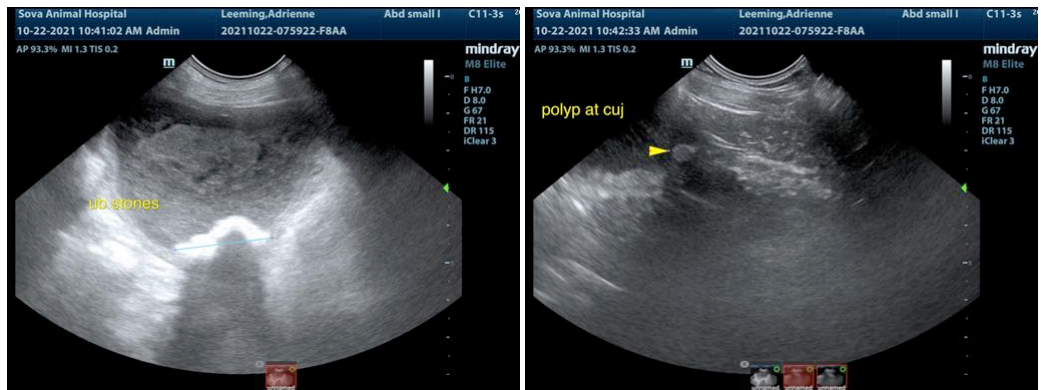
Spayed Female

AGE

8 years

WEIGHT

53.6 lbs



INTERPRETED BY

Eric Lindquist, DMV
DABVP, Cert. IVUSS

IMAGING PERFORMED BY

Marco Lichfield

HOSPITAL NAME

Sova AH

REFERRING VET

Dr. Ammeraal

INVOICE

92573

DATE

10/22/21

The information and recommendations provided are based on the images presented by the referring veterinarian. No evaluation can be communicated regarding pathology that was not visible in the image/video clips provided.

Thank you for this referral. If the clinical or image interpretation does not parallel your findings or if I can be of any further assistance please contact me.

Eric Lindquist, DMV, DABVP, Cert. IVUSS, CEO of SonoPath.com
info@SonoPath.com