



PATIENT

Jerry Brown

SPECIES

Canine

BREED

Rat Terrier

SEX

Neutered Male

AGE

14 Months

WEIGHT

21.2 Pounds

INTERPRETED BY

Eric Lindquist, DMV

DABVP, Cert. IVUSS

IMAGING PERFORMED BY

Dr. Carlos Abdul-Chani

HOSPITAL NAME

Byram AH

REFERRING VET

Dr. Carlos Abdul-Chani

INVOICE

42260

DATE

10/21/22

PRESENTING CLINICAL SIGNS

Persistent fever of 104 F - 105 F ; Hunched over posture. Normal PE besides fever. Prostate normal
Current meds: Clavamox 250 mgs BID, Enrofloxacin 68 mgs BID, Meloxidyl 1 mg SID

Abnormal PE/Chem/CBC/UA Results: Neutrophils 21,912 rest of CBC/Superchem normal Lepto
SNAP = Negative

ULTRASONOGRAPHIC EXAMINATION OF THE ABDOMEN

Urinary System

The **urinary bladder**, trigone, and pelvic urethra presented normal thicknesses and normal tone. The ureters were not visible which is normal. No uroliths or sediment were visualized and anechoic urine was present. No evidence of inflammatory or neoplastic changes were noted. Ureteral papillae were normal. The pelvic urethra was imaged 1.0 cm beyond the cystourethral junction.

The uterine base was unremarkable at 8.0 mm.

The **kidneys** revealed normal size and structure, corticomedullary definition and ratio for this age. The cortices presented largely uniform texture with normal echogenic relationship to liver and spleen. Medullary structure differed distinctly from the cortex and no evidence of pelvic dilation was present. The capsules were acceptably uniform without significant irregularities. The right kidney measured 5.33 cm. The left kidney measured 5.68 cm.

Adrenal Glands

Both **adrenal glands** were visualized and recognized as having normal shape, size, position and echogenicity for this breed. The phrenic vasculature, glandular echogenicity and detail were unremarkable. Capsule, cortex, and medullary definition were normal for this age patient. The right adrenal gland measured 2.01 cm x 0.86 cm at the cranial pole and 0.47 cm at the caudal pole. The left adrenal gland measured 2.72 cm x 0.42 cm at the cranial pole and 0.57 cm at the caudal pole.

Spleen

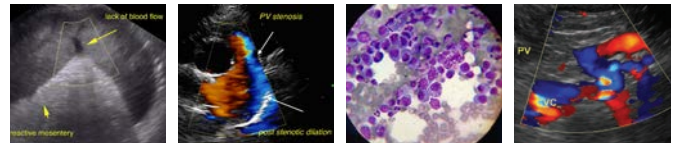
The **spleen** presented a smooth homogeneous parenchyma hyperechoic to liver and renal cortical parenchyma. The capsule was smooth without noticeable expansion or deviation from within the spleen or adjacent pathology. The splenic vasculature demonstrated normal volume without signs of congestion or thrombosis. No sonographic evidence of acute or chronic inflammatory, neoplastic, or infarctual changes were noted.

Liver

The **liver** images submitted revealed subjectively normal liver size, contour, and structure. Parenchymal echogenicity was naturally coarse and hypoechoic to the spleen. Vascular and biliary tracts were of normal volume with no evidence of congestion. The gallbladder presented acceptably thin walls with primarily anechoic content. The cystic and common bile ducts were normal. No pathological hepatic lymphadenopathy was evident. No overt structural evidence of inflammatory, infiltrative or regenerative pathology was evident.

Gastrointestinal

There was some residual chyme and gas was noted in the **stomach**, yet not pathological. This is consistent with end post prandial presentation. Transit of chyme into the small intestine was normal. Curvilinear patterns were maintained throughout the GI tract. No evidence of pathology. Soft stool



PATIENT

Jerry Brown

noted in the colon. No obstructive or overt infiltrative disease was noted. No associated abnormal lymphatic activity was noted.

Pancreas

SPECIES

Canine

The base and limbs of the **pancreas** were observed to be largely isoechoic to surrounding omental fat. Pancreatic duct and capsular contour were acceptably normal and parenchyma respected normal curvilinear patterns. No overt evidence of active inflammatory or neoplastic disease was noted.

BREED

Rat Terrier

ULTRASONOGRAPHIC FINDINGS

- Normal abdomen with soft stool in the colon

INTERPRETATION OF THE FINDINGS & FURTHER RECOMMENDATIONS

SEX

Neutered Male

No structural evidence of visceral disease to be responsible for the fever of unknown origin. Tick borne disease panel warranted.

AGE

14 Months

WEIGHT

21.2 Pounds

INTERPRETED BY

Eric Lindquist, DMV

DABVP, Cert. IVUSS

IMAGING PERFORMED BY

Dr. Carlos Abdul-Chani

HOSPITAL NAME

Byram AH

REFERRING VET

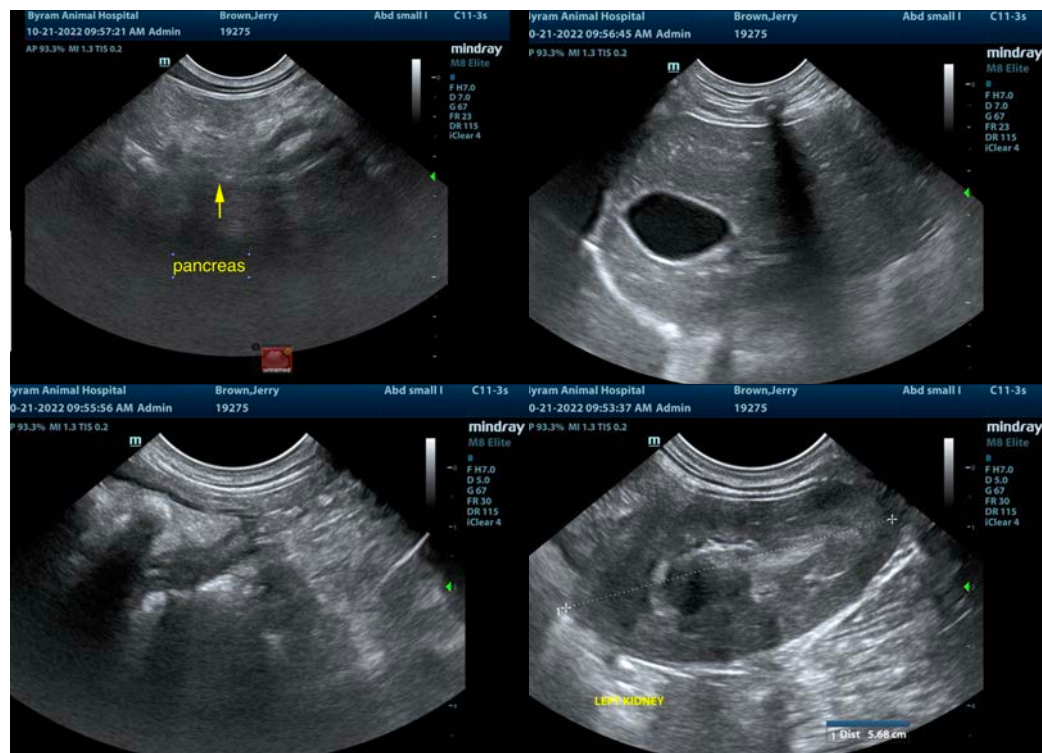
Dr. Carlos Abdul-Chani

INVOICE

42260

DATE

10/21/22





PATIENT

Jerry Brown

SPECIES

Canine

BREED

Rat Terrier

SEX

Neutered Male

AGE

14 Months

WEIGHT

21.2 Pounds

INTERPRETED BY

Eric Lindquist, DMV

DABVP, Cert. IVUSS

IMAGING PERFORMED BY

Dr. Carlos Abdul-Chani

HOSPITAL NAME

Byram AH

REFERRING VET

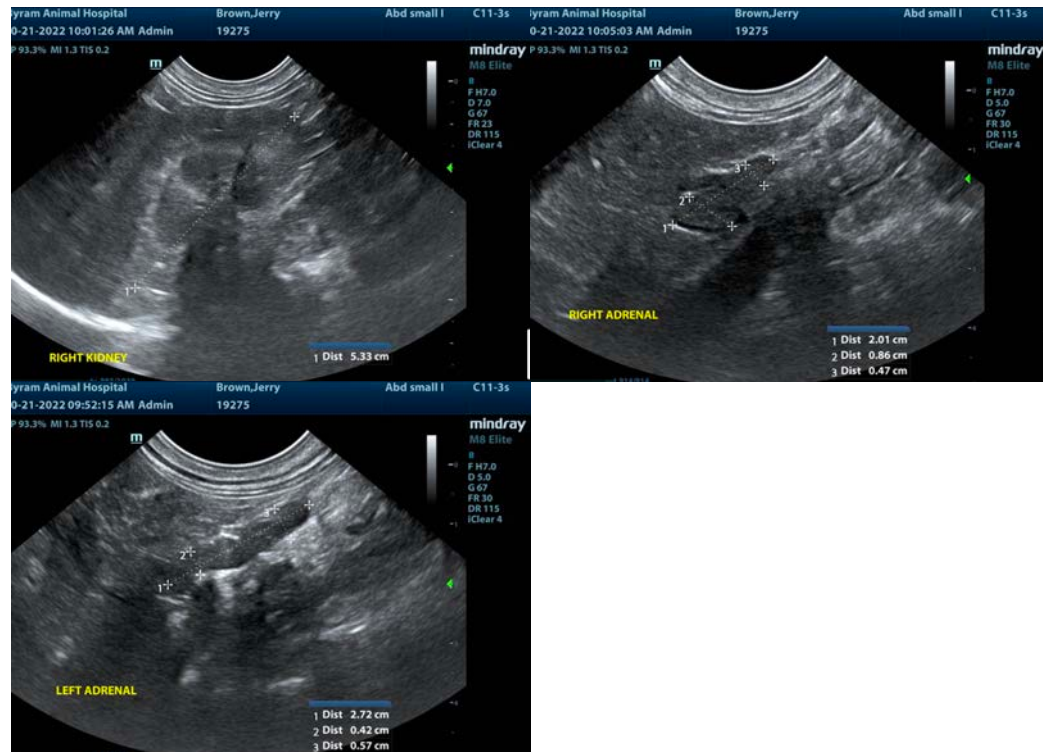
Dr. Carlos Abdul-Chani

INVOICE

42260

DATE

10/21/22



The information and recommendations provided are based on the images presented by the referring veterinarian/sonographer. No evaluation can be communicated regarding pathology that was not visible in the image/video clips provided.

Thank you for this referral. If the clinical or image interpretation does not parallel your findings or if I can be of any further assistance please contact me.

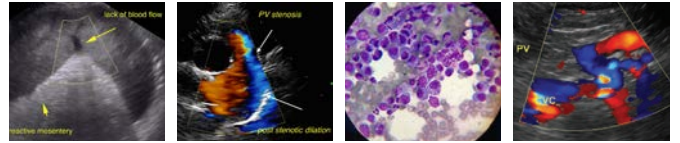
Eric Lindquist, DMV, DABVP, Cert. IVUSS, CEO of SonoPath.com

info@SonoPath.com

Fever of Unknown Origin

<http://www.sonopath.com/FUO>

Description: The definition of a fever of unknown origin (FUO) has not been clearly defined for animals. Currently, it is either understood to be a fever that does not resolve within the period one would expect for a “self-limiting infection” being treated with appropriate antimicrobial therapy, or that for which an underlying diagnosis has not been determined despite considerable diagnostic effort. The common causes of FUO were summarized concisely in a presentation at the American College of Veterinary Internal Medicine 2004 Forum. The presenters synthesized information from three veterinary papers on the subject, which suggested the following:



PATIENT

Jerry Brown

SPECIES

Canine

BREED

Rat Terrier

SEX

Neutered Male

AGE

14 Months

WEIGHT

21.2 Pounds

INTERPRETED BY

Eric Lindquist, DMV

DABVP, Cert. IVUSS

IMAGING PERFORMED BY

Dr. Carlos Abdul-Chani

HOSPITAL NAME

Byram AH

REFERRING VET

Dr. Carlos Abdul-Chani

INVOICE

42260

DATE

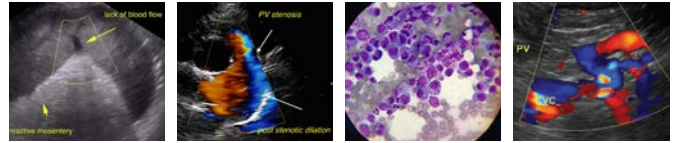
10/21/22

Final Diagnosis	Bennett (dogs & cats)	Dunn and Dunn (dogs only)	Lunn (dogs & one cat)	Total
Infection	21	16	10	47
Immune	18	22	6	46
Bone marrow disease	4	22	2	28
Neoplasia (outside marrow)	0	10	2	12
Miscellaneous	2	12	2	16
No diagnosis	0	19	2	21
TOTALS	45	101	24	170

The types of infection diagnosed in this case series were varied, ranging from discospondylitis (8 cases), blastomycosis (6), and bacterial endocarditis (4), to leishmaniasis (1), prostatitis (1), and *Ehrlichia canis* infection (1); a multitude of other infectious causes also fell within the spectrum. Of the cases in which immune-mediated disease was found, 44% had immune-mediated polyarthritis. Bone marrow diseases included myeloproliferative disease, myelodysplasia (8), lymphocytic leukemia (8), myeloma (3), chronic granulocytic leukemia (3), lymphoblastic leukemia, and malignant histiocytosis. The types of neoplasia located outside the bone marrow included lymphoma (6), metastatic disease (2), and neoplasms of the lung, spleen, and stomach. Finally, miscellaneous diseases included hypertrophic osteodystrophy (6), meningitis (3), portosystemic shunt (3), lymphadenitis (2), panosteitis, and intervertebral disc disease. Overall, the most common causes across all cases were polyarthritis (44), lymphoid neoplasia (15), discospondylitis (8), myelodysplasia (8), hypertrophic osteodystrophy (6), and blastomycosis (6).

Clinical Signs: Animals usually present with either persistent or waxing and waning fevers ranging from 103°F to 106°F. Other clinical signs depend on the underlying cause of the fever. Careful and thorough physical examination is required to assess potential causes.

Diagnostics: F.U.O etiologies are partly related to geography, and thus locale or travel history should factor into a practitioner's diagnostic approach. A patient's lifestyle may also provide clues regarding exposure to certain etiologic agents. Therefore, conducting a thorough history can unveil important pieces of the diagnostic puzzle. Physical examination is especially important and should include an inspection of all accessible lymph nodes, palpation and movement of the joints, a fundic examination, a neurological evaluation, spinal and limb palpation and range of motion tests, and a rectal examination.



PATIENT

Jerry Brown

SPECIES

Canine

BREED

Rat Terrier

SEX

Neutered Male

AGE

14 Months

WEIGHT

21.2 Pounds

INTERPRETED BY

Eric Lindquist, DMV

DABVP, Cert. IVUSS

IMAGING PERFORMED BY

Dr. Carlos Abdul-Chani

HOSPITAL NAME

Byram AH

REFERRING VET

Dr. Carlos Abdul-Chani

INVOICE

42260

DATE

10/21/22

A minimum database should include a CBC reviewed by a clinical pathologist, as well as a biochemical profile and urinalysis. Retroviral testing should also be considered in cats. In areas where tick-borne disease is prevalent, in-house testing should be performed early. Advanced laboratory work can include: urine culture, blood culture, and infectious disease panels (PCR and/or serology). In dogs, one may screen for the following infectious agents: *Ehrlichia* spp., *Borrelia burgdorferi*, Rock Mountain Spotted Fever, *Bartonella* spp. (culture and PCR), and *Leptospira* spp. in cases of hepatic or renal involvement. In cats, one should evaluate for FeLV, FIV, feline infectious peritonitis (FIP) virus, toxoplasmosis, *Hemoplasma* spp. (*Mycoplasma*), and *Bartonella* spp. (culture and PCR). Testing for *Ehrlichia* spp., *Rickettsia* spp., and *Anaplasma phagocytophilum* can also be considered. A fungal assay is indicated if the patient lives in or has had exposure to a region with a higher incidence of fungal disease. Other infectious disease tests may be performed depending on the geographical location of the pet. Screening for *Brucella* should be done in breeding dogs. Immune-mediated disease screening can include a Coomb's test, a slide agglutination test (if the patient is anemic), and an antinuclear antibody (ANA) test. Immune disease is often a diagnosis of exclusion.

Imaging should include thoracic radiographs, abdominal ultrasound, and/or abdominal radiographs. Ultrasound can be very useful for assessing evidence of cholangiohepatitis, pyelonephritis, chronic urinary tract infection, abscess formation, peritonitis, and neoplasia; it also permits an examination of the intra-abdominal lymph nodes. An echocardiogram can offer assessment for vegetative endocarditis, whereas spinal radiographs offer assessment for discospondylitis. In cases where all other testing has proven negative and the patient has not responded to broad-spectrum antibiotics and supportive care, arthrocentesis should be considered to evaluate for septic joint disease, immune-mediated polyarthritis, and infectious disease. Finally, one can consider assessing the cerebrospinal fluid for meningoencephalitis, GME, and meningitis/arteritis. A bone marrow exam should be performed if blood dyscrasias are noted on the CBC.

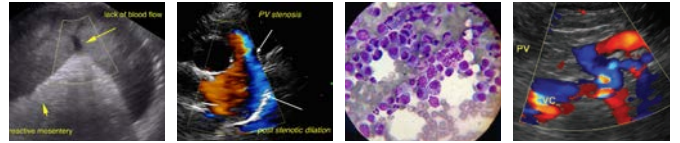
Treatment: Treatment of the fever depends entirely on the underlying cause. Ideally, a thorough diagnostic plan will yield a diagnosis that will guide the appropriate therapeutic course. However, if an exhaustive approach has not produced a definitive diagnosis and there is no response to broad-spectrum antibiotics, trial therapy with immunosuppressive agents such as prednisolone can be considered to treat presumed immune-mediated diseases. Given the potential for negative sequelae should an underlying infection be present, one must be certain that the investigation is thorough and monitor the patient's response carefully.

Conclusion: If a documented fever has not responded to antibiotics, antipyretics, or general nursing care, it is important to obtain a diagnosis to guide more specific treatment. A systematic physical examination and thorough history-taking will help inform further diagnostics in addition to what is revealed by the minimum database.

References:

Bennet D. Diagnosis of pyrexia of unknown origin. *In Practice* 1995;17(10):470-81.

Dunn KJ, Dunn JK. Diagnostic investigations in 101 dogs with pyrexia of unknown origin. *J Sm Anim Pract* 1998;39(12):574-80.



PATIENT

Jerry Brown

Flood J. The diagnostic approach to fever of unknown origin in cats. *Compend Contin Educ Vet* 2009;31(1):26-31.

SPECIES

Canine

Flood J. The diagnostic approach to fever of unknown origin in dogs. *Compend Contin Educ Vet* 2009;31(1):14-21.

BREED

Rat Terrier

Lappin MR. The role of blood borne pathogens in feline fever of unknown origin. Proceedings from the American College of Veterinary Internal Medicine, Denver, CO, June 15-18, 2011.

SEX

Neutered Male

Lunn KF. Fever of unknown origin: a systematic approach to diagnosis. *Compend Contin Educ Vet* 2001;23(11):976-92.

Lunn KF. Fever of unknown origin: appropriate choice of diagnostic tests. Proceedings from the American College of Veterinary Internal Medicine, Minneapolis, MN, June 9-12, 2004.

AGE

14 Months

WEIGHT

21.2 Pounds

INTERPRETED BY

Eric Lindquist, DMV

DABVP, Cert. IVUSS

IMAGING PERFORMED BY

Dr. Carlos Abdul-Chani

HOSPITAL NAME

Byram AH

REFERRING VET

Dr. Carlos Abdul-Chani

INVOICE

42260

DATE

10/21/22