

PATIENT

Marcus Lilliston

SPECIES

Canine

BREED

Great Dane

SEX

Male

AGE

5 years

WEIGHT

153.6 lbs

INTERPRETED BY

Eric Lindquist, DMV
DABVP, Cert. IVUSS

IMAGING PERFORMED BY

Dr. Hornbuckle

HOSPITAL NAME

Golden Isles AH

REFERRING VET

Dr. Hornbuckle

INVOICE

92540

DATE

10/21/21

PRESENTING CLINICAL SIGNS

History: Marcus presented for further evaluation of hematuria, with focus on urinary system. Other than hematuria he has no current clinical signs
Abnormal PE/Chem/CBC/UA Results: U/A and culture pending, cytology was attempted with poor results

ULTRASONOGRAPHIC EXAMINATION OF THE ABDOMEN

Urinary System

The **urinary bladder** presented minor apical wall thickening and was over distended.

The prostate was enlarged, edematous and cystic. The cyst may represent abscessation. The prostate measured 7.0 cm in short axis. Deviation of the descending colon was noted.

The **kidneys** revealed normal size and structure, corticomedullary definition and ratio for this age. The cortices presented largely uniform texture with normal echogenic relationship to liver and spleen. Medullary structure differed distinctly from the cortex and no evidence of pelvic dilation was present. The capsules were acceptably uniform without significant irregularities. The left kidney measured 8.0 cm. The right kidney measured 8.0 cm.

Adrenal Glands

Both **adrenal glands** were visualized and recognized as having normal shape, size, position and echogenicity for this breed. The phrenic vasculature, glandular echogenicity and detail were unremarkable. Capsule, cortex, and medullary definition were normal for this age patient.

Spleen

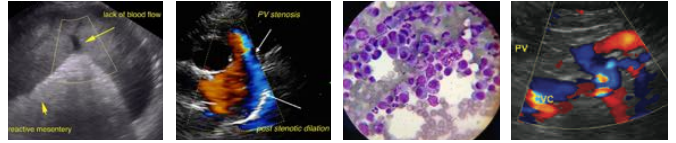
The **spleen** presented a smooth homogeneous parenchyma hyperechoic to liver and renal cortical parenchyma. The capsule was smooth without noticeable expansion or deviation from within the spleen or adjacent pathology. The splenic vasculature demonstrated normal volume without signs of congestion or thrombosis. No sonographic evidence of acute or chronic inflammatory, neoplastic, or infarctual changes was noted.

Liver

The **liver** images submitted revealed subjectively normal liver size, contour, and structure. Parenchymal echogenicity was naturally coarse and hypoechoic to the spleen. Vascular and biliary tracts were of normal volume with no evidence of congestion. The gallbladder presented acceptably thin walls with primarily anechoic content. The cystic and common bile ducts were normal. No pathological hepatic lymphadenopathy was evident. No overt structural evidence of inflammatory, infiltrative or regenerative pathology was evident.

Gastrointestinal

Examination of the **gastrointestinal tract** revealed a stomach and intestine free of stasis, of normal wall thickness, acceptable curvilinear mural detail, and peristaltic activity. Small and large intestine



PATIENT

Marcus Lilliston

demonstrated normal luminal chyme and stool consistency respectively. No obstructive or overt infiltrative disease was noted. No associated abnormal lymphatic activity was noted.

SPECIES

Canine

Pancreas

The base and limbs of the **pancreas** were observed to be largely isoechoic to surrounding omental fat. Pancreatic duct and capsular contour were acceptably normal and parenchyma respected normal curvilinear patterns. No overt evidence of active inflammatory or neoplastic disease was noted.

BREED

Great Dane

ULTRASONOGRAPHIC FINDINGS

SEX

Male

BPH prostatitis pattern.

INTERPRETATION OF THE FINDINGS & FURTHER RECOMMENDATIONS

AGE

5 years

Neutering is recommended. If neutering is absolutely not a potential then the following protocol could be considered.

WEIGHT

153.6 lbs

Finasteride at 1 mg/kg/day can be utilized as an off-label approach to reducing prostatic size in BPH cases. Coverage for prostatitis would also likely be appropriate with Fluoroquinolone/Baytril or similar. A recheck sonogram is recommended in 3-4 weeks with reassessment of the urinalysis and evaluation of any inflammatory sediment.

INTERPRETED BY

Eric Lindquist, DMV
DABVP, Cert. IVUSS

IMAGING PERFORMED BY

Dr. Hornbuckle

HOSPITAL NAME

Golden Isles AH

REFERRING VET

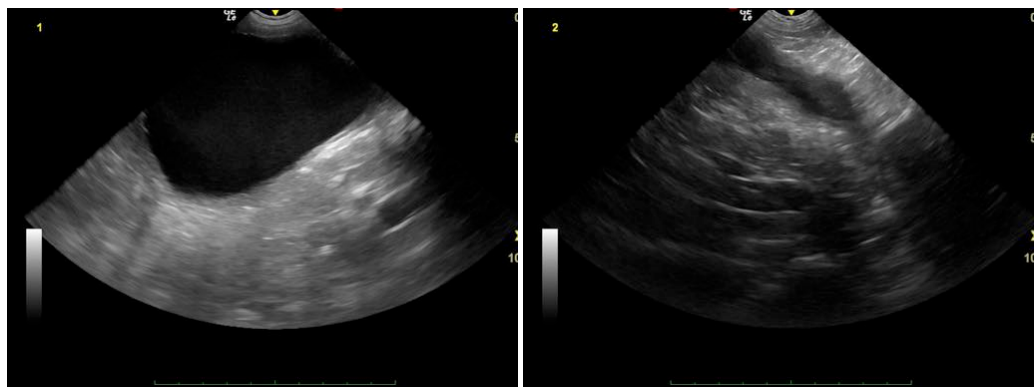
Dr. Hornbuckle

INVOICE

92540

DATE

10/21/21





PATIENT

Marcus Lilliston

SPECIES

Canine

BREED

Great Dane

SEX

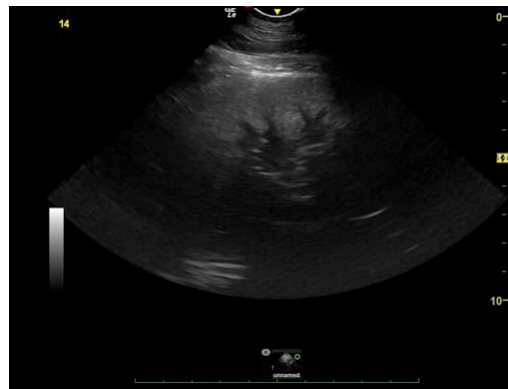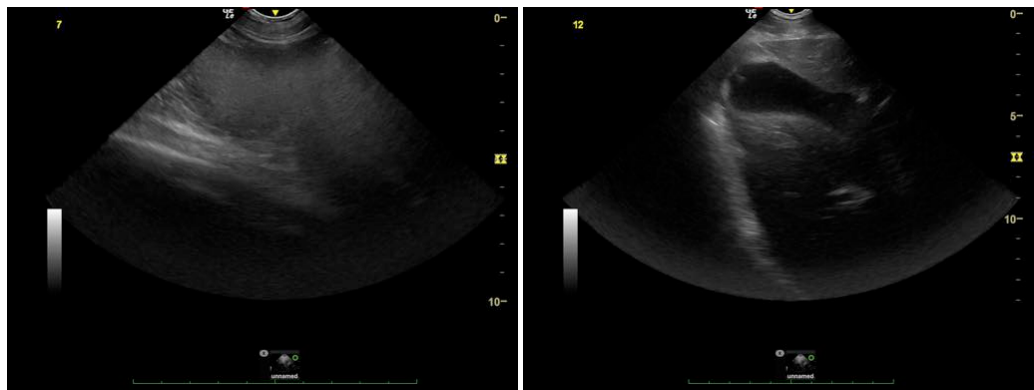
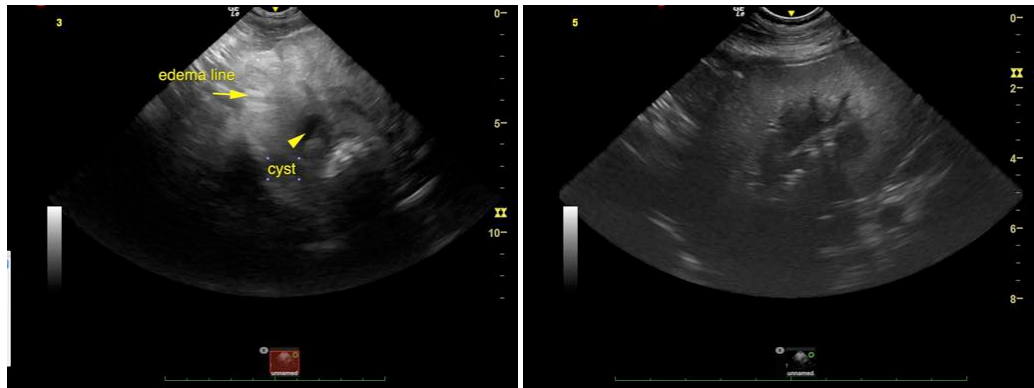
Male

AGE

5 years

WEIGHT

153.6 lbs



INTERPRETED BY

Eric Lindquist, DMV
DABVP, Cert. IVUSS

IMAGING PERFORMED BY

Dr. Hornbuckle

HOSPITAL NAME

Golden Isles AH

REFERRING VET

Dr. Hornbuckle

INVOICE

92540

DATE

10/21/21

The information and recommendations provided are based on the images presented by the referring veterinarian. No evaluation can be communicated regarding pathology that was not visible in the image/video clips provided.

Thank you for this referral. If the clinical or image interpretation does not parallel your findings or if I can be of any further assistance please contact me.

Eric Lindquist, DMV, DABVP, Cert. IVUSS, CEO of SonoPath.com
info@SonoPath.com