



PATIENT PRESENTING CLINICAL SIGNS

Frankie Tartini Follow up echo, last one performed by SPM on 7/31/20. Current med: Pimobendan 3.75 mgs BID.

SPECIES ULTRASONOGRAPHIC EXAMINATION OF THE HEART

Canine

BREED

Dachshund

SEX

Neutered Male

AGE

14 Years

WEIGHT

23 Pounds

CANINE CARDIAC PARAMETERS	MR VMAX (m/s)	TR VMAX (m/s)	LA/AO (Boon method)	LA/AO (Heart Base; Swe)	FS (%)	EF (%)	EPSS (cm)
NORMAL PARAMETER	4.5-5.5	<2.7	1.3	<1.6	28-40	40-100	<0.6
PATIENT	5.5		1.5	1.3	36	67	NM
CANINE CARDIAC PARAMETERS	HR (BPM)	AV VMAX (m/s)	PV MAX (m/s)	BODY WEIGHT (kg)	LA 2D short axis Base view (cm)	LVIDd Avg; 2D and m-mode short axis (cm)	LVIDs Avg; 2D and m-mode short axis (cm)
NORMAL PARAMETER	50-100	0.7-1.7	0.7-1.6				
PATIENT	107	1.94	1.05		3.9	3.25	

Cardiac Presentation

The left atrium was mildly enlarged in the LA Max measurements. Arrhythmogenic activity was noted in this patient with prolapse of the anterior mitral valve leaflet. The cranial and caudal mitral valve leaflets presented vegetative thickening consistent with endocardiosis. Eccentric MR jet noted with moderate filling of the left atrium. Doppler indicated measurable insufficiency. The left ventricle presented thicknesses with linear contour and was not dilated nor restricted. The myocardium presented normal echogenicity without subjective evidence of significant fibrotic or ischemic disease. Contractility of the ventricular walls was adequate and in normal range for this patient evidenced by the fractional shortening measurement and subjective evaluation of the different regions of the myocardium. Aortic insufficiency noted at 6.0 m/sec. The right atrium and auricle revealed normal size, structure and content. No evidence of masses was noted or chamber overload. Tricuspid valvular assessment demonstrated adequate linear morphology. The right ventricle was of normal size (1/3 diameter of LV), chordae structure, myocardial echogenicity and thickness. Pulmonic tract assessment revealed normal valve structure, laminar flow, and diameter (approx. 1:1 pa/ao ratio). No visible pericardial or free pleura fluid was noted. No echographically detectable evidence of infiltrative disease was visible. The cranial mediastinum and pericardial regions were free of masses in the visible window.

ULTRASONOGRAPHIC FINDINGS

- Mitral and tricuspid insufficiency, early stage B2 valvular disease with minor left atrial enlargement
- Aortic insufficiency present

INTERPRETATION OF THE FINDINGS & FURTHER RECOMMENDATIONS

Assessment for systemic hypertension warranted as well as EKG given the arrhythmia. Pimobendan could be justified at 0.3 mg/kg BID. Recheck echo in 3-6 months, earlier if clinical signs indicate. ACE inhibitor warranted if systolic pressures are >160.

INTERPRETED BY

Eric Lindquist, DMV
DABVP, Cert. IVUSS

IMAGING PERFORMED BY

Kelly Vazquez

HOSPITAL NAME

New Bridge VP

REFERRING VET

Dr. Glennon

INVOICE

26565

DATE

10/21/21



PATIENT

Frankie Tartini

SPECIES

Canine

BREED

Dachshund

SEX

Neutered Male

AGE

14 Years

WEIGHT

23 Pounds

INTERPRETED BY

Eric Lindquist, DMV
DABVP, Cert. IVUSS

IMAGING PERFORMED BY

Kelly Vazquez

HOSPITAL NAME

New Bridge VP

REFERRING VET

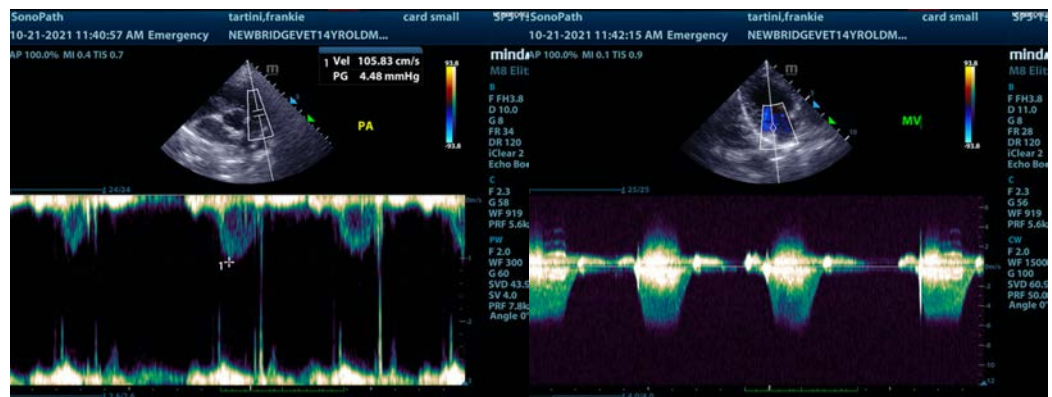
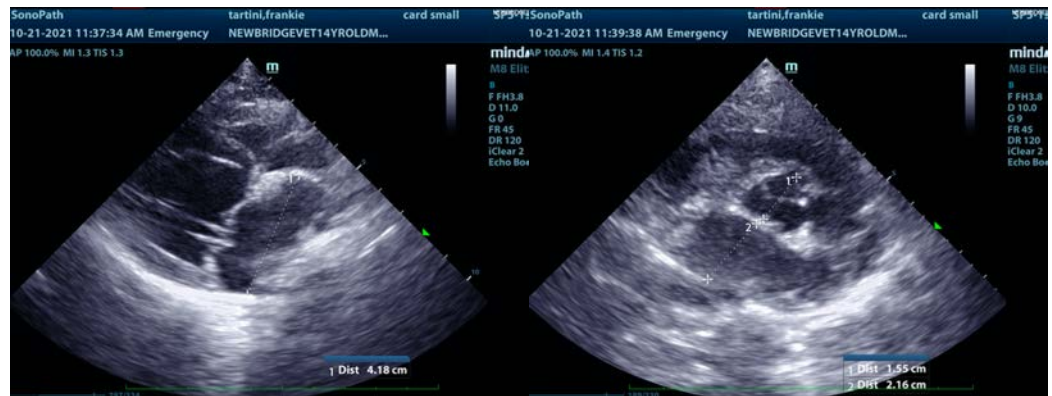
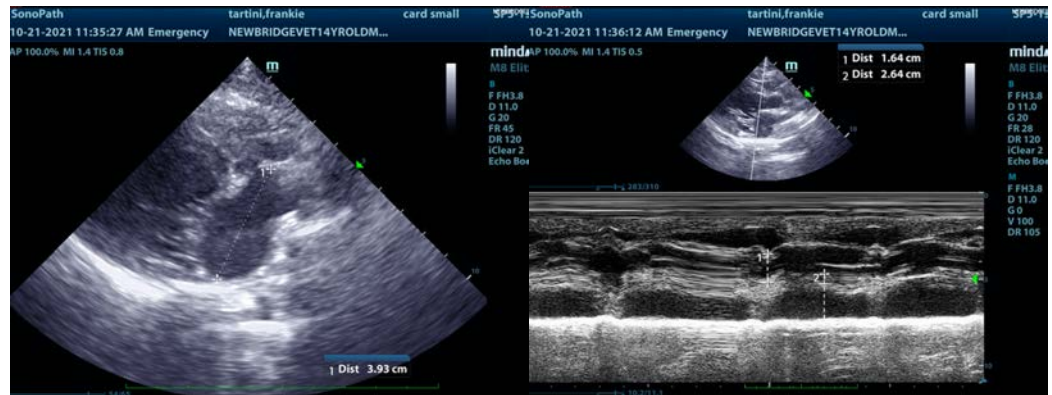
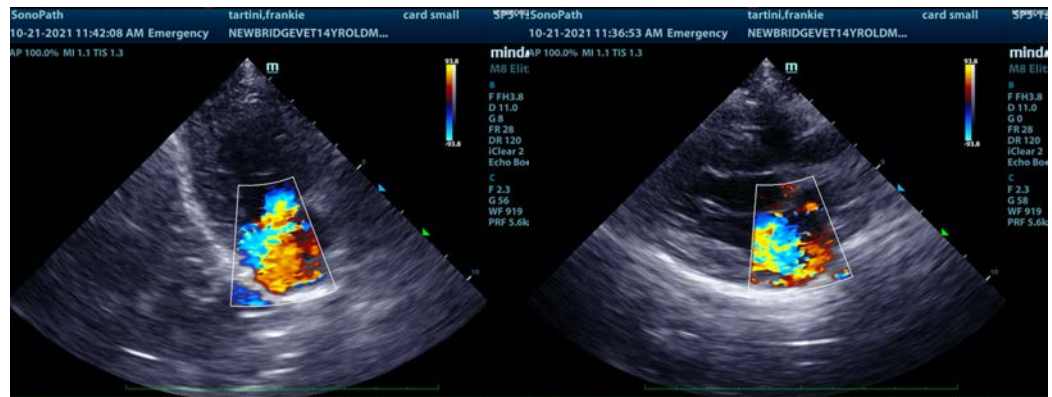Dr. Glennon

INVOICE

26565

DATE

10/21/21





PATIENT

Frankie Tartini

SPECIES

Canine

BREED

Dachshund

SEX

Neutered Male

AGE

14 Years

WEIGHT

23 Pounds

INTERPRETED BY

Eric Lindquist, DMV
DABVP, Cert. IVUSS

IMAGING PERFORMED BY

Kelly Vazquez

HOSPITAL NAME

New Bridge VP

REFERRING VET

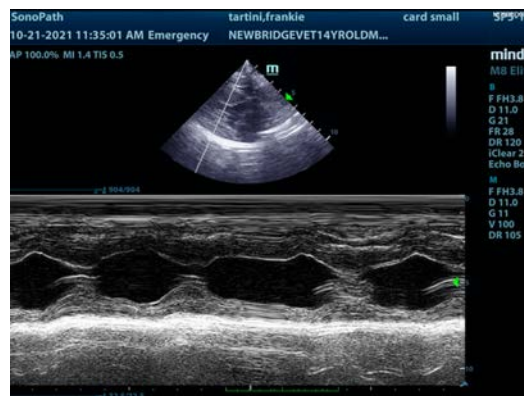
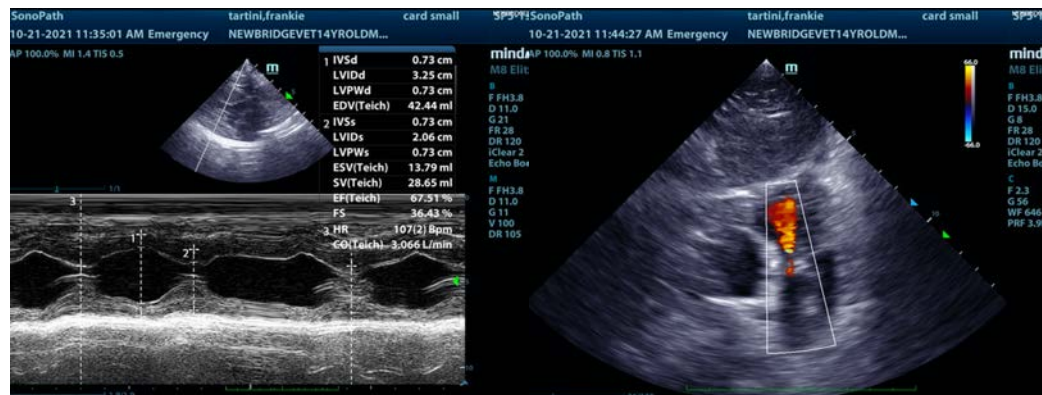
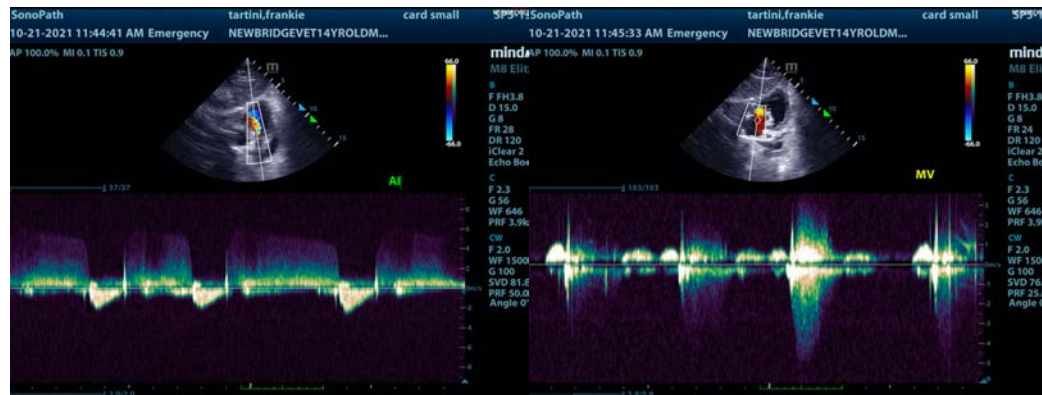
Dr. Glennon

INVOICE

26565

DATE

10/21/21



The information and recommendations provided are based on the images presented by the referring veterinarian. No evaluation can be communicated regarding pathology that was not visible in the image/video clips provided.

Thank you for this referral. If the clinical or image interpretation does not parallel your findings or if I can be of any further assistance please contact me.

Eric Lindquist, DMV, DABVP, Cert. IVUSS, CEO of SonoPath.com
info@SonoPath.com