



PATIENT PRESENTING CLINICAL SIGNS

Eli Stringham yellow/bloody diarrhea

SPECIES ULTRASONOGRAPHIC EXAMINATION OF THE ABDOMEN

Canine Urinary System

The **urinary bladder**, trigone, and pelvic urethra presented normal thicknesses and normal tone. The ureters were not visible which is normal. No uroliths or sediment were visualized and anechoic urine was present. No evidence of inflammatory or neoplastic changes were noted. Ureteral papillae were normal.

BREED

Poodle X

SEX

Male

The **kidneys** revealed normal size and structure, corticomedullary definition and ratio for this age. The cortices presented largely uniform texture with normal echogenic relationship to liver and spleen. Medullary structure differed distinctly from the cortex and no evidence of pelvic dilation was present. The capsules were acceptably uniform without significant irregularities. The left kidney measured 5.29 cm. The right kidney measured 5.2 cm.

AGE

8 Months

Adrenal Glands

Both **adrenal glands** were visualized and recognized as having normal shape, size, position and echogenicity for this breed. The phrenic vasculature, glandular echogenicity and detail were unremarkable. Capsule, cortex, and medullary definition were normal for this age patient. The right adrenal gland measured 1.93 cm x 0.61 cm at the caudal pole and 0.57 cm at the cranial pole. The left adrenal gland measured 2.5 cm x 0.37 cm at the caudal pole and 0.41 cm at the cranial pole.

WEIGHT

44.5 Pounds

Spleen

The **spleen** presented a smooth homogeneous parenchyma hyperechoic to liver and renal cortical parenchyma. The capsule was smooth without noticeable expansion or deviation from within the spleen or adjacent pathology. The splenic vasculature demonstrated normal volume without signs of congestion or thrombosis. No sonographic evidence of acute or chronic inflammatory, neoplastic, or infarctual changes were noted.

INTERPRETED BY

Eric Lindquist, DMV
DABVP, Cert. IVUSS

IMAGING PERFORMED BY

Jenn

HOSPITAL NAME

Rockaway AH

Liver

The **liver** images submitted revealed subjectively normal liver size, contour, and structure. Parenchymal echogenicity was naturally coarse and hypoechoic to the spleen. Vascular and biliary tracts were of normal volume with no evidence of congestion. The gallbladder presented acceptably thin walls with primarily anechoic content. The cystic and common bile ducts were normal. No pathological hepatic lymphadenopathy was evident. No overt structural evidence of inflammatory, infiltrative or regenerative pathology was evident.

REFERRING VET

Dr. Maniar

Gastrointestinal

The **stomach** presented a shadowing foreign body of approximately 4.0 cm in the pyloric outflow. The small intestine and colon were unremarkable.

INVOICE

26544

Pancreas

The base and limbs of the **pancreas** were observed to be largely isoechoic to surrounding omental fat. Pancreatic duct and capsular contour were acceptably normal and parenchyma respected normal curvilinear patterns. No overt evidence of active inflammatory or neoplastic disease was noted.

DATE

10/21/21



PATIENT

Eli Stringham

ULTRASONOGRAPHIC FINDINGS

- Gastric foreign body

SPECIES

Canine

INTERPRETATION OF THE FINDINGS & FURTHER RECOMMENDATIONS

Gastrotomy and GI biopsies recommended to rule out underlying disease.

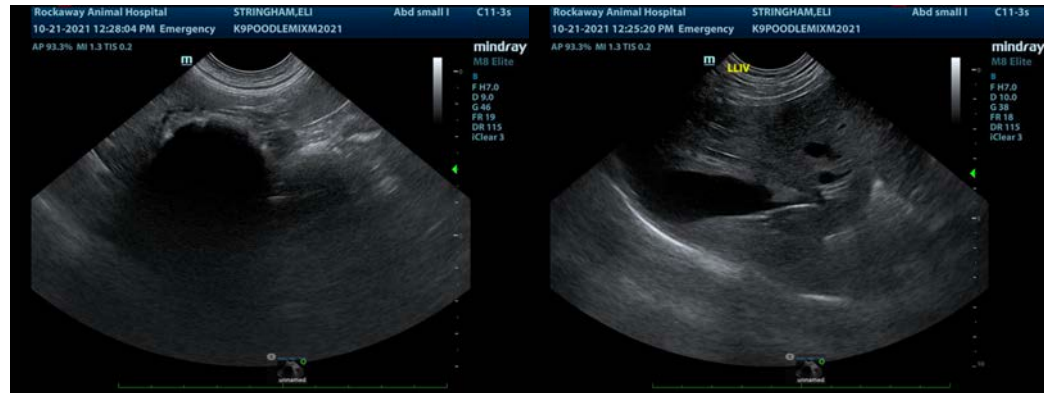
BREED

Poodle X

According to Sonopath research presented at ECVIM 2016 (Stockholm, Sweden), Advances in Small Animal Medicine and Surgery (May 2017), and EVDI 2017 (Verona, Italy), concurrent underlying chronic inflammatory neoplastic intestinal disease can often reside in PICA patients. Therefore, surgical biopsies are essential in this case regardless of the exploratory findings.

SEX

Male



AGE

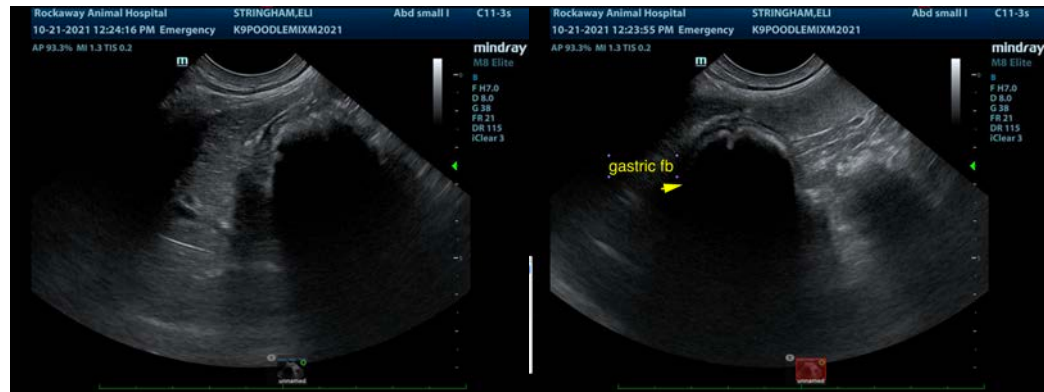
8 Months

WEIGHT

44.5 Pounds

INTERPRETED BY

Eric Lindquist, DMV
DABVP, Cert. IVUSS



IMAGING PERFORMED BY

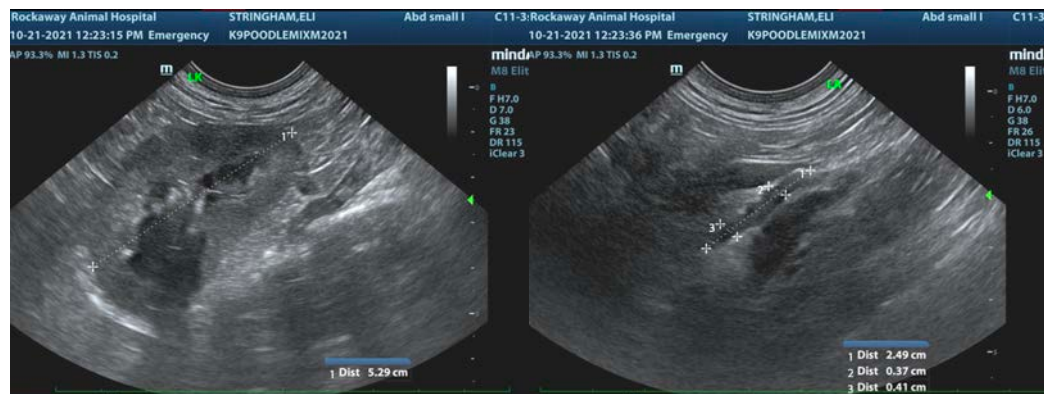
Jenn

HOSPITAL NAME

Rockaway AH

REFERRING VET

Dr. Maniar



INVOICE

26544

DATE

10/21/21



PATIENT

Eli Stringham

SPECIES

Canine

BREED

Poodle X

SEX

Male

AGE

8 Months

WEIGHT

44.5 Pounds

INTERPRETED BY

Eric Lindquist, DMV
DABVP, Cert. IVUSS

IMAGING PERFORMED BY

Jenn

HOSPITAL NAME

Rockaway AH

REFERRING VET

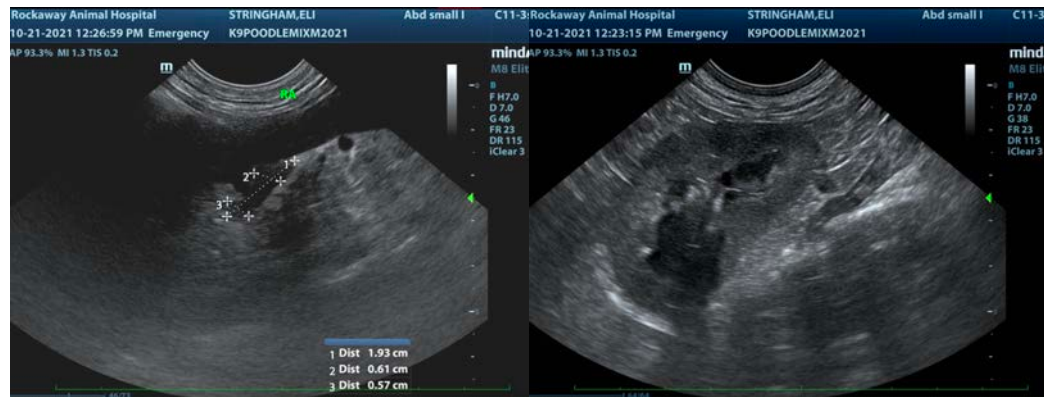
Dr. Maniar

INVOICE

26544

DATE

10/21/21



The information and recommendations provided are based on the images presented by the referring veterinarian. No evaluation can be communicated regarding pathology that was not visible in the image/video clips provided.

Thank you for this referral. If the clinical or image interpretation does not parallel your findings or if I can be of any further assistance please contact me.

Eric Lindquist, DMV, DABVP, Cert. IVUSS, CEO of SonoPath.com
info@SonoPath.com