



PATIENT PRESENTING CLINICAL SIGNS

Bitsy Berman

History: Bitsy has had a cough for several months and some wheezing. No heart murmur on exam, Rads suggested bronchitis and initially px responded to prednisone. Cough returned and owner began tracking sleeping resp. rate. SRR over the course of a week was consistently 30-32 and cough was intermittent but persistent. Px e/d well, no v/d generally active. U/S was ordered to explore the potential for heart related cough

SPECIES

Canine

BREED ULTRASONOGRAPHIC EXAMINATION OF THE HEART

Shih Tzu

The echocardiogram in this patient demonstrated normal **left atrial** size based on 3 separate methods of LA evaluation. The cranial and caudal **mitral** valve leaflets presented normal linear structure, extension in systole, and union in diastole with normal kinesis. The **left ventricle** presented thicknesses with linear contour and was not dilated nor restricted. The **myocardium** presented normal echogenicity without subjective evidence of significant fibrotic or ischemic disease. **Contractility** of the ventricular walls was adequate and in normal range for this patient evidenced by the fractional shortening measurement and subjective evaluation of the different regions of the myocardium. The **left ventricular outflow** tract demonstrated normal laminar flow and subjective structural integrity. The **right atrium** and auricle revealed normal size, structure and content. No evidence of masses was noted. **Tricuspid** valvular assessment demonstrated adequate linear morphology and kinesis. The **right ventricle** was of normal size (1/3 diameter of LV), chordae structure, myocardial echogenicity and thickness. **Pulmonary outflow** tract assessment revealed normal valve structure, laminar flow, and diameter (approx.1:1 pa/ao ratio). No visible **pericardial** or free pleura fluid was noted. The cranial **mediastinum and pericardial and extra-cardiac regions** were free of masses in the visible window.

SEX

Spayed Female

AGE

12 years

WEIGHT

16.6 lbs

INTERPRETED BY

Eric Lindquist, DMV
DABVP, Cert. IVUSS

IMAGING PERFORMED BY

Dr. Hornbuckle

HOSPITAL NAME

Golden Isles AH

REFERRING VET

Dr. Hornbuckle

CANINE CARDIAC PARAMETERS	MR VMAX (m/s)	TR VMAX (m/s)	LA/AO (Boon method)	LA/AO (Heart Base; Swe)	FS (%)	EF (%)	EPSS (cm)
NORMAL PARAMETER	4.5-5.5	<2.7	1.3	<1.6	28-40	40-100	<0.6
PATIENT			1.1	1.3	35		0.1
CANINE CARDIAC PARAMETERS	HR (BPM)	AV VMAX (m/s)	PV MAX (m/s)	BODY WEIGHT (kg)	LA 2D short axis Base view (cm)	LVIDd Avg; 2D and m- mode short axis (cm)	LVIDs Avg; 2D and m- mode short axis (cm)
NORMAL PARAMETER	50-100	0.7-1.7	0.7-1.6				
PATIENT					2.5 max	2.0	

INVOICE

92551

DATE

10/21/21

ULTRASONOGRAPHIC FINDINGS

Normal echocardiogram.



PATIENT

Bitsy Berman

INTERPRETATION OF THE FINDINGS & FURTHER RECOMMENDATIONS

The cough is non-cardiogenic in this patient. Primary respiratory protocol is recommended.

SPECIES

Canine

BREED

Shih Tzu

SEX

Spayed Female

AGE

12 years

WEIGHT

16.6 lbs

INTERPRETED BY

Eric Lindquist, DMV
DABVP, Cert. IVUSS

IMAGING PERFORMED BY

Dr. Hornbuckle

HOSPITAL NAME

Golden Isles AH

REFERRING VET

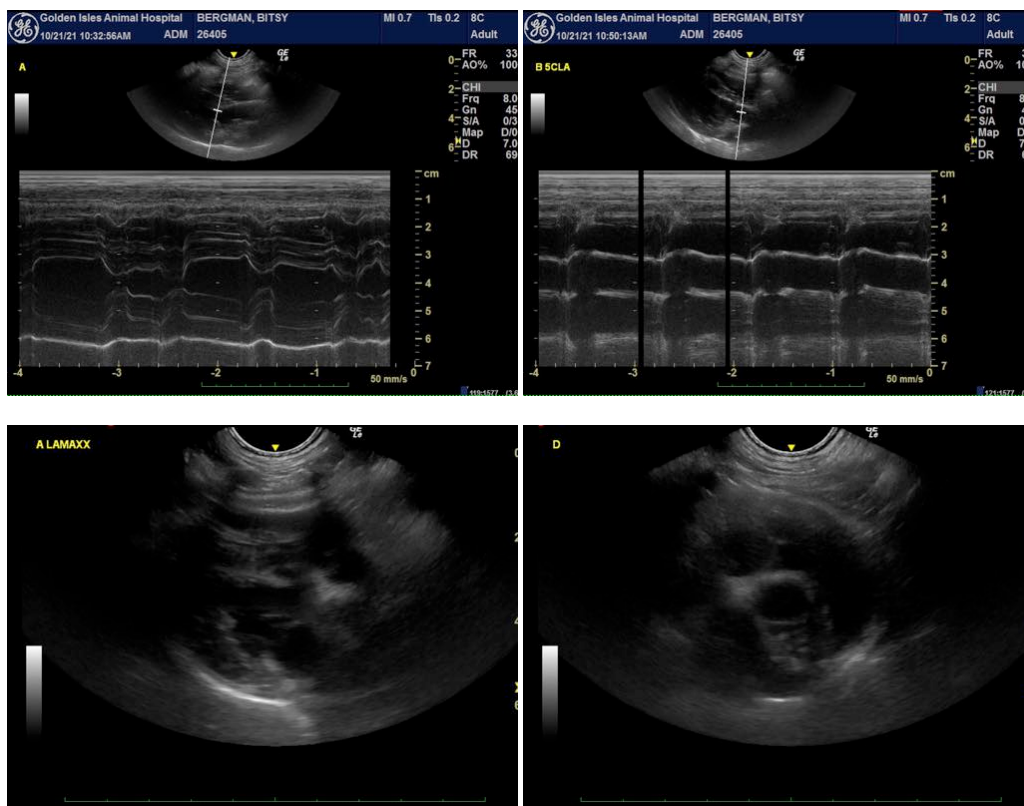
Dr. Hornbuckle

INVOICE

92551

DATE

10/21/21



The information and recommendations provided are based on the images presented by the referring veterinarian. No evaluation can be communicated regarding pathology that was not visible in the image/video clips provided.

Thank you for this referral. If the clinical or image interpretation does not parallel your findings or if I can be of any further assistance please contact me.

Eric Lindquist, DMV, DABVP, Cert. IVUSS, CEO of SonoPath.com
info@SonoPath.com